

A sticky foreign body in patient's airway

Shiva Kumar Arava, MD, DNB, FRCA, EDRA

Consultant Anaesthetist, Craigavon Area Hospital, Belfast, (Northern Ireland)

Correspondence: Dr Shiva Kumar Arava, 22, Schomberg Park, Belfast, BT4 2HH (Northern Ireland); E-mail:

A 38 year old man was scheduled to have an examination under anesthesia of his perianal region as a day case procedure. He had needle phobia, was a smoker, and fasted for more than 6 hours. Intravenous (IV) access was obtained uneventfully and general anesthesia was induced with IV fentanyl and propofol. An i-gel size 4 was inserted with ease and ability to ventilate was checked. The patient breathed spontaneously through the surgery. Anesthesia was maintained with sevoflurane in oxygen. The surgery proceeded uneventfully and the patient was wheeled into level 1 recovery with i-gel in situ breathing room air.

As he recovered fully, the recovery nurse took out the i-gel. A large yellowish sticky material was noticed on its cuff, initially thought to be a large mucous plug. A close inspection revealed it to be a chunky piece of chewing gum (Figures 1 & 2).

Luckily, the bulk of the soft non inflatable cuff of the I gel meant that the gum got stuck to it and lodged itself between the cuff and the piriform fossa. It could

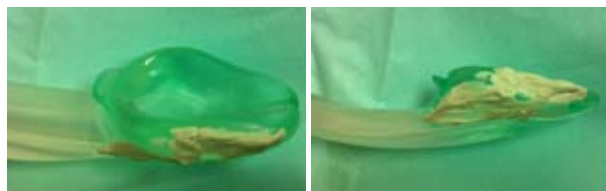


Figure 1 & 2: Chewing gum stuck to the lateral side of the cuff of i-gel

have been aspirated during induction of anesthesia or displaced onto the glottic inlet at the time of insertion of the i-gel with disastrous results. The i-gel's thermoplastic elastomer properties, the contours of the cuff itself which very accurately mirror the perilaryngeal framework and the ready malleability of the chewing gum, prevented the harm.

There have been many case reports of a variety of foreign bodies that have been found in reusable laryngeal mask airways¹⁻⁶. While cases have been reported where chewing gum has been aspirated and caused lower airway obstruction⁶, we believe this is the first report of chewing gum found stuck on an i-gel. The above episode shows the dangers lurking round the back of the tongue and the importance of one last "Can u say aah... please?" before administering the IV induction agent. A frank discussion regarding the risk of choking was had with the patient, but was laughed off. No laughing matter for us anesthetists...

The doctor-patient relationship needs to be based on openness, trust and good communication⁸. While every doctor should make this part of their routine practice and the General Medical Council ensures that it remains so, what will ensure that the patient keeps their end of the bargain? I have made it a routine practice now to specifically ask my patients whether they have been chewing gum and advise them of the risk of choking on gum that's not spat out.

REFERENCES

1. Conacher ID. Foreign body in a laryngeal mask airway. *Anaesthesia* 1991;46:164. [PubMed] [Free full text]
2. Riley RH, Browning FS. Another foreign body in a laryngeal mask airway. *Anaesthesia* 1996; 51: 286-7. [PubMed]
3. Cameron D, Onslow J. Obstruction of airway equipment. *Anaesthesia* 2002;57:188-9. [PubMed]
4. Srikanth K. Yet another foreign body in a laryngeal mask airway. *Anaesthesia* 2002; 57: 189-90. [PubMed]
5. Vohra SB. Another foreign body in a laryngeal mask. *Anaesthesia* 2004; 59: 98-98. [PubMed]
6. Extraction of chewing gum obstructing the lower airways. A need for competence in bronchoscopy? Matthew M. J. Smith, Charles Cooper. *BJA* 2012. [Free full text]

★ ★ ★ ★ ★