

ORIGINAL ARTICLE

Intraarticular dexamethasone in pain management following arthroscopic Bankart repair

Ranajit Panigrahi¹, Ritesh Roy², Anju Prasad³, Amita Kumari Mahapatra⁴, Ashok Priyadarshi⁵, Nishit Palo⁵

¹MBBS, MS (Orthopedics), Professor of Orthopedics

²MBBS, MD (Anesthesia), Professor of Anesthesiology

³MBBS, MD (Pharmacology), Associate Professor of Pharmacology

⁴MBBS, MD (Physiology), Assistant Professor of Physiology

⁵MBBS, Postgraduate in Department of Orthopedic

Hi-Tech Medical College & Hospital, High Tech Hospital Rd, Pandara, Bhubaneswar, Odisha 751007, (India)

Correspondence: Prof. Dr. Ritesh Roy, Plot no-582, Jagannath Complex, Flat No-102, Sahid Nagar, Bhubaneswar, Odisha -751007, (India); Cell: 09437101886; E-mail: drriteshroy@yahoo.com

ABSTRACT

Objective: Arthroscopic Bankart's procedure is widely used method for shoulder instability. It may evoke variable intensity of postoperative pain, which may be unbearable depending upon individual's pain threshold. Adequate pain relief reduces surgical stress response, improves postoperative recovery and rehabilitation. We conducted this study to compare the postoperative analgesic effect of addition of dexamethasone 300 µg/kg to intra-articular ropivacaine with ropivacaine only in arthroscopic Bankart's procedures.

Methodology: A prospective multi-center double blind study was conducted on 45 patients undergoing arthroscopic Bankart's procedure from Jan 2015 to June 2015. Patients were randomly assigned into 3 groups - Group I receiving 20 ml normal saline, Group II 20 ml 0.2% ropivacaine and Group III (15 ml 0.2% of ropivacaine and dexamethasone in a dose of 300 µg/kg intra-articularly. Variables assessed: analgesic effect (VAS Score), time to first postoperative analgesic request, total analgesics used during first 24 hours.

Results: Group III had significantly low pain scores for more than 24 hours as compared to Group II and Group I. Time to first analgesic requirement was the longest in Group III (1562.2 ± 79.10 min) (p < 0.01). Intensity of pain and total analgesic requirement was also significantly less in Group III (32.2 ± 23.83 mg) (p < 0.01) compared to Group II and I. No significant side-effects were noted.

Conclusion: Dexamethasone 300 µg/kg with ropivacaine intra-articularly has a superior analgesic efficacy, a much prolonged postoperative pain relief, minimal postoperative analgesia requirement and better patient compliance with negligible side effects. Thus, we recommend dexamethasone 300 µg/kg in arthroscopic Bankart's procedure to facilitate early rehabilitation and good functional scores.

Key words: Dexamethasone; Ropivacaine; Pain; Acute Pain; Pain, Postoperative; Shoulder pain; Analgesia; Shoulder

Citation: Panigrahi R, Roy R, Prasad A, Mahapatra AK, Priyadarshi A, Palo N. Intraarticular dexamethasone in pain management following arthroscopic Bankart repair. *Anaesth Pain & intensive Care* 2015;19(3):269-273

INTRODUCTION

Shoulder instability is a serious disabling injury which is routinely seen in orthopedic practice. Shoulder dislocations occur predominantly in males in the 3rd decade¹ with an incidence of 11-

56 per 100,000 person-years.² Shoulder dislocates mostly anteriorly but also posteriorly or inferiorly.³

The arthroscopic Bankart procedure is extremely popular, effective and widely accepted for treatment of anterior shoulder instability.⁴ In

spite of being a minimally invasive procedure, it can evoke different levels of pain postoperatively, which at times can be unbearable depending on the individual patient's pain tolerance. Postoperative pain affects patient's psychology, mobilization and rehabilitation adversely and may prolong hospital stay⁵ and worsen the prognosis. Adequate pain relief improves postoperative recovery and rehabilitation.⁵

An inter-scalene block gives excellent immediate pain control, but of a short and unpredictable duration; there is a high risk that the patient experiences severe and uncontrollable pain the first night after surgery.⁶ Continuous nerve block gives a better pain control but is more technically and logistically demanding.⁷ The severity and duration of pain after surgery has a high inter-individual variation, it is challenging to safely administer an adequate dose of opiate analgesics. There has frequently been a search for a simple method for providing postoperative analgesia in these patients that would have a prolonged duration of action, be easy to administer and without any serious side effects.

The intra-articular route of drug administration utilises the peripheral receptors and administration of local anesthetics through this route is routinely done after arthroscopic knee surgery but in shoulder procedures, intraarticular analgesics are not frequently used. Previous studies have reported the use local anesthetics such as bupivacaine, ropivacaine, opioids like morphine, magnesium sulphate intra-articularly in shoulder arthroscopic procedures with variable duration of analgesia for postoperative pain control.⁸⁻¹⁰

Although a few studies report the analgesic effect of fixed dose dexamethasone following shoulder arthroscopic procedures, we report the analgesic effects of a dexamethasone titrated by $\mu\text{g} / \text{kg}$ body weight manner following arthroscopic shoulder Bankart's repair. We compared a combination of dexamethasone- ropivacaine against ropivacaine, as well as versus normal saline following arthroscopic Bankart procedure. We hypothesized that a longer postoperative analgesia could be achieved, provided that dexamethasone $300 \mu\text{g} / \text{kg}$ was safe and free from any side effects.

METHODOLOGY

In this Multicenter prospective double-blind randomised trial, after clearance by the local ethical committee, 45 consecutive patients with shoulder

instabilities who underwent elective arthroscopic Bankart's repair from Jan 2015 to Jun 2015 were included in the study after they consented to participate in this study. Inclusion criteria were 15–60 years, Male/Female, no mental illnesses or allergy to dexamethasone or ropivacaine, ASA class I and II, being operated arthroscopically under general anesthesia for Bankart's lesion. Patient refusal, any previous surgery of shoulder, any known allergy or contraindication to ropivacaine, or dexamethasone, pregnancy, lactating mothers, hepatic, renal or cardiopulmonary abnormality, alcoholism, diabetes, long-term analgesic therapy, bleeding diathesis, coagulopathies, local skin site infections, hypertension were excluded from the study.

The randomization was performed based on a computer generated number by a person unaware of the study objectives who sealed the obtained codes in secure envelopes. The envelopes were given to the researcher who had no role in the treatment or evaluation. This person then gave a syringe containing the solution based on the confidential codes to the surgeon to inject into the joint cavity.

In the preoperative visit, the visual analogue scale (VAS) was obtained and the patients were questioned about any drug allergy, previous operations or drug treatment. Just before the operation, baseline heart rate (HR), mean arterial pressure (MAP) were recorded. Intraoperatively, routine ECG, HR, blood pressure (systolic, diastolic and mean) and arterial oxygen saturation (SpO_2) were monitored. The anesthetic technique was standard for all patients and all the operations were performed under general anesthesia. Syringes containing 20 ml aqueous solution of either normal saline or ropivacaine [ROPIN™ 0.2% 2 mg/ml; Neon Laboratories Ltd. Andheri (East), Mumbai (India)] or 15 ml ropivacaine with dexamethasone $300 \mu\text{g} / \text{kg}$ body weight were injected intra-articularly at the end of surgery by treating orthopedic surgeon and sterile compression bandage applied.

Postoperatively, VAS score and vital parameters like HR, MAP were recorded at 1, 3, 6, 8, 12, 18, and 24 hrs. Diclofenac sodium (75 mg) was administered I.V. as an analgesic supplementation if the recorded VAS pain score was > 4 and was repeated every 8 h if required. The time to the first analgesic requirement and the total diclofenac use during the first 24 h after operation were also recorded. Side effects such as nausea, vomiting, bradycardia and hypotension (defined as reduction of MAP 25%

of baseline) were recorded.

Group I (Control group) - received 20 ml saline.

Group II- Received 20 ml (0.2%) ropivacaine hydrochloride.

Group III- Received 15 ml (0.2%) ropivacaine and 300 $\mu\text{g}/\text{kg}$ dexamethasone.

Variables assessed: Postoperative analgesic effect (VAS score) at 1st, 3rd, 6th, 8th, 12th, 18th and 24th hour; time to first postoperative analgesic request and total analgesic used during first 24 hours were recorded.

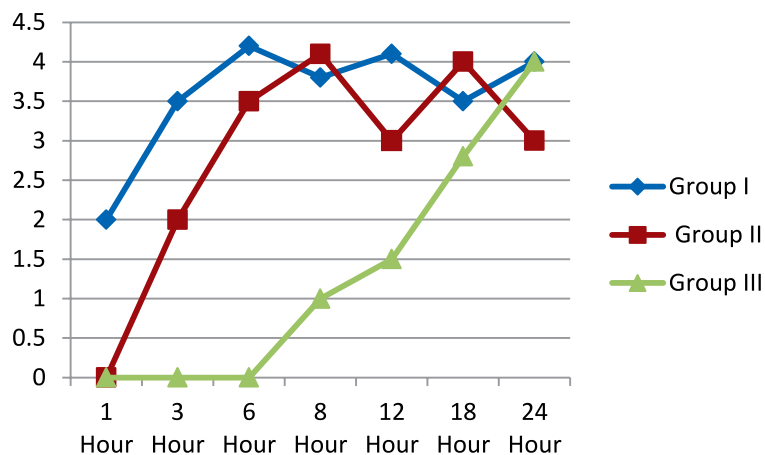


Figure 1: Change in Visual Analogue Scale in 3 Groups

RESULTS

Out of 45 patients, 32 were males. As regards the demographic characteristics (Table 1), there was no significant differences in the mean age, weight of the patients and duration of surgery in the groups. No side effects were reported during the first 24 hour after surgery. Mean arterial pressure and heart rate did not change significantly in the three groups.

VAS scores in Group III at 3rd hour ($p < 0.01$), at 6th hour ($p < 0.02$), at 8th hour ($p < 0.02$), at 12th hour ($p < 0.05$) and 18th ($p < 0.05$) hour was least as compared to group I and II following surgery (see Figure 1)

No incidence of nausea, vomiting, bradycardia, hypotension or other side-effects requiring

intervention were reported in the subjects.

Time to first postoperative analgesia request was longest in Group III (1562.2 ± 79.10 min) as compared to the Group II (445.2 ± 64.3 min) and Group I (323.8 ± 56.61 min) ($p < 0.01$). Mean total analgesic consumption in first 24 hours was least in Group III (32.2 ± 23.83 mg) followed by Group I (223.25 ± 54.83 mg) and Group II (151.72 ± 53.5 mg) ($p < 0.01$) (see Table 2).

DISCUSSION

Arthroscopic Bankart's repair is often associated with severe postoperative pain due to irritation of free nerve endings of synovial tissue and joint capsule during surgical excision, insertion of hardware, bone removal or soft tissue distension from

Table 1: Patient characteristics of 3 groups [Data given as Mean \pm SD]

Variables	Group I (n=15)	Group II (n=15)	Group III (n=15)
Age(years)	34.5 \pm 10.85	31.2 \pm 9.28	32.3 \pm 11.4
Gender(M/F)	11/5	10/4	11/4
Weight(kgs)	66.4 \pm 5.43	65.3 \pm 8.44	68.2 \pm 6.65
Duration of Surgery(min)	78.4 \pm 21.53	81.3 \pm 23.84	80.4 \pm 24.74

Table 2: Analgesia Duration and total analgesic requirement in 24 hours

	Group I	Group II	Group III	p-value
Mean time to 1 st postoperative analgesic requirement (min)	323.8 \pm 56.61	445.2 \pm 64.3	1562.2 \pm 79.10	0.004
Mean total analgesic (diclofenac) consumption in 24 hours (mg)	223.25 \pm 54.83	151.72 \pm 53.5	32.2 \pm 23.83	0.007

irrigation fluid¹¹. Good early rehabilitation requires postoperative pain control and mobilization. Although loco-regional anesthesia has greatly contributed as a solution for postoperative pain relief, its intra-articular administration following arthroscopic shoulder procedures is not yet in routinely clinical practice.

Dexamethasone has been used intrarticularly following shoulder arthroscopic surgeries in a few studies previously with good results, but no study has reported the analgesic effects in a dosage of 300 µg/kgwt. Our study reported the postoperative analgesic effect of dexamethasone in the dose of 300 µg/kgwt as an adjunct to ropivacaine following arthroscopic Bankart's lesion repair. We observed a long analgesic period and decreased analgesic requirement post operatively with a better patient compliance.

Dexamethasone was selected in our study because of its highly potent anti-inflammatory property with minimal mineralocorticoid activity and devoid of potential side effects. Steroids also share a block prolonging effect due to their anti-inflammatory potency.^{12,13} The dense and prolonged block in the dexamethasone group is attributed to the synergistic action with local anesthetic ropivacaine on blockade of nociceptive C-nerve fibres.

Studies report significant pain relief, up to 12 hours post shoulder arthroscopy in patients receiving intrarticular injection of 1000 mg magnesium sulphate with 10ml normal saline but reported side effects like nausea, vomiting in few patients¹⁴ and up to 10 hours in patients receiving intrarticular ropivacaine with decreased analgesic

requirement¹⁵. Whereas we observed a significant pain free period of more than 24 hours in our study in patients receiving intrarticular dexamethasone 300 µg/kgwt with 15ml of ropivacaine compared to normal saline and ropivacaine injections alone. Our patients were extremely pleased with the surgery and to our surprise, some cases did not require analgesic support even up to 30 hours.

We report a significant prolongation of analgesia and the time to first postoperative analgesic requirement (1562.2 ± 79.10 min $p < 0.01$), a significant reduction in consumption of analgesic (32.2 ± 23.83 mg $p < 0.01$) and a significantly lower pain VAS score in the first 24 hours in the intra-articular dexamethasone group which are better as compared to the reported literature. We attribute these results to the new dosage of dexamethasone.

A limitation could be a measure of dexamethasone's plasma concentration to correlate it with clinical findings, which may have confirmed the local effects. Intraarticular dexamethasone 300 µg/kg enhanced the postoperative analgesia after arthroscopic Bankart's repair without any significant side effects and thus can safely and effectively be used in this procedure.

CONCLUSION

Dexamethasone with ropivacaine, intrarticularly has a superior analgesic efficacy, a much prolonged postoperative pain relief, minimal postoperative analgesic requirement and better patient compliance with negligible side effects.

Conflict of interest: None declared by the authors.

REFERENCES

1. Zacchilli M, Owens B. Epidemiology of shoulder dislocations presenting to emergency departments in the United States. *J Bone Joint Surg Am* 2010;92(3):542–549. [PubMed] doi: 10.2106/JBJS.I.00450.
2. Liavaag S, Svenningsen S, Reikerås O, Enger M, Fjalestad T, Pripp A, Brox JI. The epidemiology of shoulder dislocations in Oslo. *Scand J Med Sci Sports* 2011;21(6):e334–e340. [PubMed] [Free full text] doi: 10.1111/j.1600-0838.2011.01300.x. Epub 2011 Apr 21.
3. Owens B, Duffey M, Nelson B, DeBerardino T, Taylor D, Mountcastle S. The incidence and characteristics of shoulder instability at the United States Military Academy. *Am J Sports Med* 2007;35(7):1168–1173. [PubMed]
4. Owens B, Harrast J, Hurwitz S, Thompson T, Wolf J. Surgical trends in Bankart repair: an analysis of data from the American Board of Orthopaedic Surgery certification examination. *Am J Sports Med* 2011;39(9):1865–1869. [PubMed] doi: 10.1177/0363546511406869.
5. Manuar MB, Majumdar S, Das A, Hajra BK, Dutta S, Mukherjee D et al. Pain relief after Arthroscopic Knee Surgery: A comparison of intra-articular ropivacaine, fentanyl, and dexmedetomidine: A prospective, double-blinded, randomized controlled study. *Saudi J Anaesth*. 2014 Apr;8(2):233-7. doi: 10.4103/1658-354X.130727. [PubMed]
6. Boezaart A, Tighe P. New trends in regional anesthesia for shoulder surgery: avoiding devastating complications. *Int J Shoulder Surg* 2010;4(1):1–7. [PubMed][Free full text] doi: 10.4103/0973-6042.68410.
7. Boezaart AP. Continuous interscalene block for ambulatory shoulder surgery. *Best Pract Res Clin Anaesthesiol* 2002;16(2):295–310. [PubMed]
8. Rodolà F, Vagnoni S, D'Avolio S, Vurchio M, Micci D, Chierichini A, et al. Intra-articular analgesia following arthroscopic surgery of the shoulder. *Eur Rev Med Pharmacol Sci*. 2001 Jul-Aug;5(4):143-6. [PubMed]
9. Saritas TB, Borazan H, Okesli S, Yel M, Otelcioglu S. Is intra-articular magnesium effective for postoperative analgesia in arthroscopic shoulder surgery? *Pain Res Manag*. 2015 Jan-Feb;20(1):35-8. [PubMed] [Free full text]
10. Doss N W, Splain S H, Crimi T, Michael R, Abadir A R, Gintautas J. Intra-articular morphine, ropivacaine and morphine/ropivacaine for pain control after arthroscopy. Preliminary Observation. *Proc West Pharmacol Soc*. 2001;44:195-196. [PubMed]
11. Ruiz-Suarez M. Postoperative pain control after shoulder arthroscopy. *Orthopaedics* 2008;31:1130. [PubMed]
12. Johanson A, Hao J, Sjölund B. Local corticosteroid application blocks transmission in normal nociceptive C-fibres. *Acta Anaesthesiol Scand* 1990;34:335-8. [PubMed]
13. Golwala MP, Swadia VN, Aditi AD, Sridhar NV. Pain relief by dexamethasone as an adjuvant to local anesthetics in supraclavicular-brachial plexus block. *J Anaesth Clin Pharmacol* 2009;25:285-8. [PubMed]
14. Saritas TB, Borazan H, Okesli S, Yel M, Otelcioglu S. Is intra-articular magnesium effective for postoperative analgesia in arthroscopic shoulder surgery? *Pain Res Manag*. 2015 Jan-Feb;20(1):35-8. [PubMed] [Free full text]
15. Rodolà F, Vagnoni S, D'Avolio S, Vurchio M, Micci D, Chierichini A, et al. Intra-articular analgesia following arthroscopic surgery of the shoulder. *Eur Rev Med Pharmacol Sci*. 2001 Jul-Aug;5(4):143-6. [PubMed]



“Man needs difficulties in life because they are necessary to enjoy the success.”

Dr. A.P.J Abdul Kalam