

## CASE REPORT

## PAIN MANAGEMENT

# Transforming pain relief: intercostal nerve blocks for intractable pain due to metastatic cancer of the ribs

Christian Reza Wibowo<sup>1</sup>, Herdiani Sulisty Putri<sup>2</sup>, Dedi Susila<sup>3</sup>

**Author affiliations:**

1. Christian Reza Wibowo, Department of Anesthesiology & Reanimation, Faculty of Medicine, Universitas Airlangga, Indonesia. Department of Anesthesiology & Reanimation, Dr. Soetomo General Academic Hospital, Surabaya, 60132, East Java, Indonesia; Email: [chrstnreza@gmail.com](mailto:chrstnreza@gmail.com), {ORCID: [0009-0007-7356-5300](https://orcid.org/0009-0007-7356-5300)}
2. Herdiani Sulisty Putri, MD, Department of Anesthesiology & Reanimation, Dr. Soetomo General Academic Hospital, Faculty of Medicine, Universitas Airlangga, Surabaya 60132, East Java, Indonesia; E-mail: [herdiani-s-p@fk.unair.ac.id](mailto:herdiani-s-p@fk.unair.ac.id), {ORCID: [0000-0002-3839-9147](https://orcid.org/0000-0002-3839-9147)}
3. Dedi Susila, MD, Department of Anesthesiology & Reanimation, Dr. Soetomo General Academic Hospital, Faculty of Medicine, Universitas Airlangga, Surabaya 60132, East Java Indonesia; E-mail: [ddi\\_sus@yahoo.com](mailto:ddi_sus@yahoo.com)

**Correspondence:** Herdiani Sulisty Putri, MD, **E-mail:** [herdiani-s-p@fk.unair.ac.id](mailto:herdiani-s-p@fk.unair.ac.id), {ORCID: [0000-0002-3839-9147](https://orcid.org/0000-0002-3839-9147)}; **Tel:** +628123236695

## ABSTRACT

Pain is a prevalent symptom in advanced cancer, with 66.4% of patients experiencing moderate to severe pain. Effective management is challenging, as up to 80% of the patients report severe pain, making optimal quality of life a critical goal.

A 23-year-old woman, with rectal cancer, suffered intractable left chest pain due to rib metastasis, worsening over a year. Despite treatment with fentanyl with patient-controlled analgesia (PCA) and oral morphine, the patient experienced intractable cancer pain, requiring 53 attempts at fentanyl PCA administration, with a total of 1 g used within 24 hours during the most severe episodes, when her pain score reached 9–10. An ultrasound-guided intercostal nerve block was performed at levels 7 and 10, using 20 mg triamcinolone and 10 mL of 0.75% ropivacaine. Post-procedure, the patient reported localized pain at the injection site, but experienced a significant reduction in sharp chest pain. This intervention resulted in an 80% decrease in her background opioid usage and reduced the frequency of as-needed doses. This case underscores the effectiveness of interventional pain management techniques, such as nerve blocks, as alternatives or adjunct treatment, when conventional medications fail. The combination of local anesthetics for immediate relief and steroids for long-term benefits, can effectively minimize opioid dependence and side effects.

**Abbreviations:** ICNB: intercostal nerve block, NRS: Numeric Rating Scale, PCA: patient-controlled analgesia,

**Keywords:** Cancer Pain; Chronic Pain; Patient-Controlled Analgesia; Intercostal Nerve Block; Interventional Pain

**Citation:** Wibowo CR, Putri HS, Susila D. Transforming pain relief: intercostal nerve blocks for intractable pain due to metastatic cancer of the ribs. *Anaesth. pain intensive care* 2024;28(5):127-131.

**DOI:** [10.35975/apic.v29i1.2652](https://doi.org/10.35975/apic.v29i1.2652)

**Received:** November 01, 2024; **Reviewed:** December 20, 2024; **Accepted:** December 23, 2024

## 1. INTRODUCTION

Tumors or metastases on the chest wall can arise from the lungs, colon, or breasts, often leading to incurable conditions that necessitate palliation and pain management. While 70-90% of cancer pain can be managed with opioids, tolerance may develop, complicating treatment.<sup>1</sup> This case describes an intractable cancer pain condition that necessitated 53 attempts using fentanyl patient-controlled analgesia

(PCA) and administered a total of 1 g within 24 hours at its most severe level of pain. When patients reach the maximum opioid dose alongside adjuvant analgesics, interventional techniques may provide better alternatives. One effective method is the intercostal nerve block, which can involve local anesthesia or chemical neurolysis to significantly alleviate pain.<sup>2</sup> Studies indicate that such interventions lead to substantial pain reduction and decreased opioid consumption, minimizing side effects.<sup>3</sup>

## 2. CASE REPORT

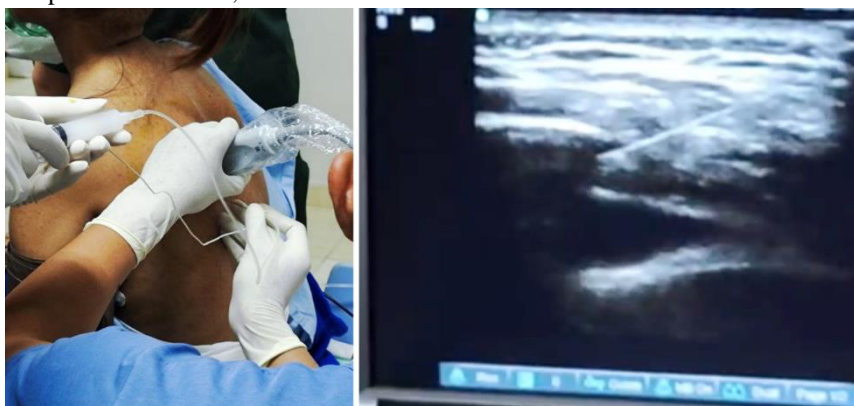A 23-year-old woman, weighing 43 kg and 155 cm tall, was admitted with stage IV rectal cancer complicated by a stoma and metastases to the liver and bones, particularly affecting the 7th and 10th left ribs. She presented with severe cancer-related pain, reporting a Numeric Rating Scale (NRS) score of 8-10, on morphine sulphate 10 mg every 12 hours as a single analgesia, significantly impairing her quality of life. On her first day in the hospital, she began chemotherapy and underwent drainage of left-sided pleural effusion. Initial examination revealed tachycardia at 125 beats per minute and hypotension with blood pressure at 98/57 mmHg. To manage her pain, the physician prescribed a fentanyl patch 25 µg/hour, tramadol infusion 100 mg every 8 hours, paracetamol infusion 500 mg every 8 hours, and ketorolac 30 mg. However, the following day, she reported persistent severe pain in her left rib cage, maintaining an NRS score of 8-10. After completing chemotherapy on the third day, her pain escalated to an NRS score of 9-10. A fentanyl rescue IV dose of 50 µg was administered, morphine sulphate was halted, and PCA was initiated at a maintenance dose of 30 µg /hour. Amitriptyline and pregabalin were added for neuropathic pain management. After six hours, she reported improved sleep and a decrease in her NRS score to 3-4. On the fifth day, the pulmonary team drained 700 mL of pleural effusion, alleviating her shortness of breath. The next day, she noted slight improvement in pain levels with an NRS score of 4-5.

A trial conversion from fentanyl to morphine sulphate was initiated, determining a total daily requirement of morphine sulphate at 144 mg for optimal pain control.

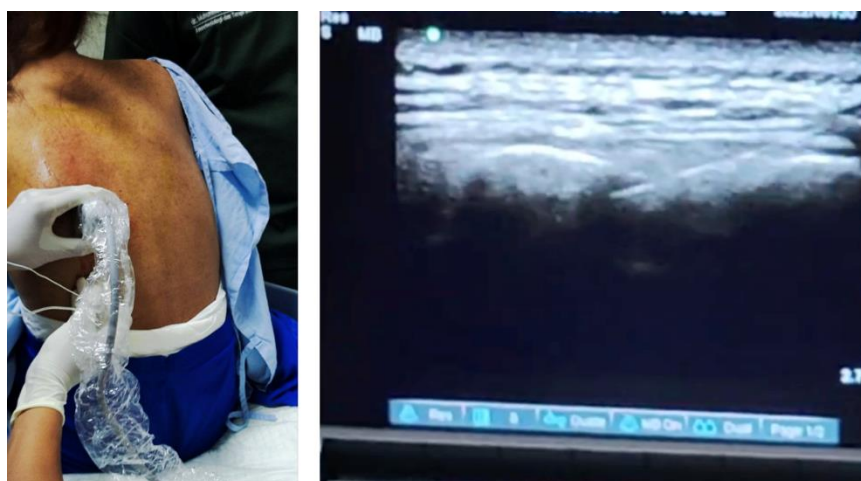Despite ongoing analgesic therapy with pregabalin, amitriptyline, and paracetamol, the patient continued to experience persistent left rib cage pain and sleep disturbances. She felt nauseous without vomiting and could only consume small amounts of food. The planned second pleural drainage was

postponed due to intolerable pain, with NRS scores reaching 9-10. To manage her pain, we administered an additional 20 mg of ketamine IV and a fentanyl rescue dose of 50 µg, along with oral therapies including pregabalin, amitriptyline, paracetamol, and morphine sulphate. However, she experienced severe nausea and vomiting after her second dose of morphine sulphate 30 mg, followed by chills and desaturation to 90% despite nasal cannula oxygen at 3 Lpm. Vital signs showed a heart rate of 145 beats per minute and blood pressure of 98/67 mmHg, while the NRS remained high at 9-10. We provided oxygen via a simple mask at 6 lpm, successfully increasing her saturation to 98%. morphine sulphate was discontinued, and PCA resumed with adjustments.

On the eighth day of the hospital stay, the patient underwent an intercostal nerve block (ICNB) at the left 7th and 10th ribs under ultrasound guidance. The procedure is illustrated in Figure 1 for 7th rib and Figure 2 for 10th rib. We injected 10 mL of ropivacaine 0.75% and triamcinolone 20 mg into each costal segment. Two hours post-procedure, she reported a decrease in her NRS score to between 4-5



**Figure 1: Placement of probe and needle in 7th Left Posterior Costae and In-plane approach**



**Figure 2: Placement of probe and needle in 10th Left Posterior Costae and In-plane approach**

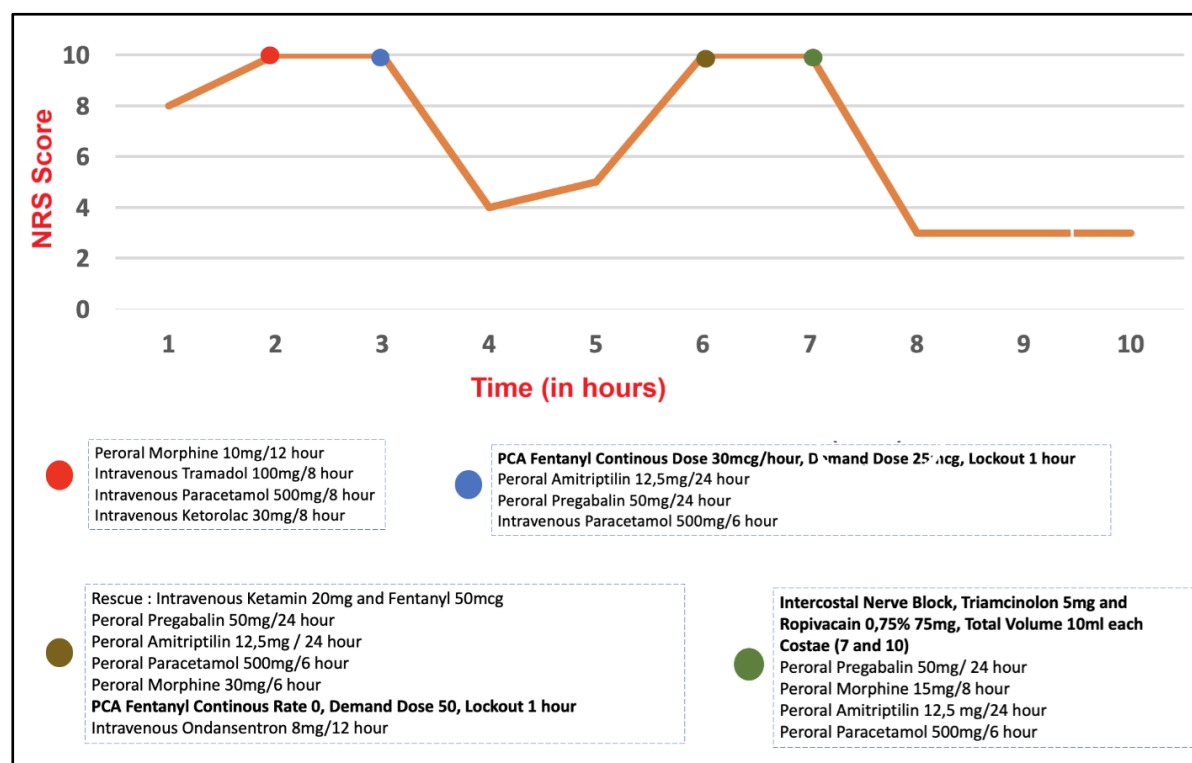


Figure 3: NRS pain scale and the pain management at various time points

and appeared calmer without severe pain while breathing. Later that afternoon, the pulmonary team drained pleural effusion again, evacuating a total of 900 mL of fluid. One day after the nerve block, the patient looked more relaxed and communicated effectively. She reported sleeping well through the

night despite some pain around the injection site. Overall rib cage pain had significantly decreased; however, slight discomfort persisted following the tapping done previously. Her shortness of breath continued to improve as well. The NRS score reduced to 3-4 during this time; PCA fentanyl were administered eight times and the dose totalled 400 µg. As part of long-term pain management strategy, we initiated a conversion from IV fentanyl to oral morphine with a total requirement set at 80 mg.

Two days post-nerve block, she reported sleeping through the night without nausea or vomiting in the past 24 hours. Pain at the injection site had diminished; slight swelling remained while rib pain occurred occasionally with an NRS score at level 3. The patient then underwent a CT scan of the thorax with contrast for further evaluation. Three days after the intercostal block she appeared calm and reported infrequent pain without complaints of nausea or vomiting. Her shortness of breath had significantly reduced; she could sit up and move slightly without significant difficulty. Vital signs were stable: heart rate at 110 beats per minute and blood pressure at 98/59 mmHg, while maintaining an NRS score at 3. The timeline of the patient can be seen in Figure 3. She was discharged with prescribed analgesics for continued care at home.

### 3. DISCUSSION

This case demonstrates the patient's progression through the analgesic ladder, ultimately leading to opioid resistance and the need for interventional pain management via a nerve block. The decision was prompted by opioid tolerance, as PCA with fentanyl failed to control breakthrough pain and caused intolerable side effects. A selective nerve block with ropivacaine plus steroids was chosen for its minimal side effects. Previous studies showed that 90% of patients achieved significant pain relief from this intervention.<sup>4</sup>

The WHO analgesic ladder provides a structured approach to managing cancer pain, categorizing treatment into three steps based on severity. For mild pain, non-opioid analgesics like paracetamol and NSAIDs are recommended. Moderate pain may require a combination of non-opioids and weak opioids, while severe pain necessitates strong opioids, with morphine as the gold standard. The ladder emphasizes regular dosing and individualized treatment to alleviate pain in 70-80% of patients.<sup>5,6</sup> Effective communication is crucial; opioids should be administered round-the-clock rather than on as-needed basis.<sup>5</sup> Breakthrough pain is managed with the same opioids used for background therapy, often favoring fentanyl for its rapid onset. Many patients reported needing additional rescue doses, suggesting that initial PCA settings may not have adequately addressed their pain needs. This highlights a substantial number of patients experiencing persistent pain despite high

attempts at self-administration, leading to the necessity for alternative interventions.<sup>7</sup> In this case, the opioid dosage required for pain management was so high that the side effects significantly threatened the patient's life, leading to respiratory depression, desaturation, nausea, vomiting, and fever from mild to moderate dehydration. The decision for urgent interventional pain management was made at this point when the risks of opioid use outweighed the benefits, prompting an aggressive reduction in opioid therapy.

A systematic review has shown that interventional procedures, including nerve blocks, significantly reduce pain in cancer patients who do not achieve satisfactory relief with conventional opioid therapy. In a cohort study, 80% of patients undergoing these procedures reported pain relief, with average pain scores decreasing from 6.5 to 4.2 on a 0-10 scale post-treatment. This suggests that patients reliant on PCA fentanyl with inadequate control could benefit from such interventions.<sup>8</sup> The ultrasound-guided ICNB is a minimally invasive procedure designed to alleviate pain from rib cancer and other thoracic conditions. It enhances accuracy and safety, allowing for precise targeting of nerves while minimizing complications.<sup>9</sup> Recent studies using ropivacaine combined with steroids, like triamcinolone, have shown promising results in prolonging pain relief; one study noted a mean reduction of 61% lasting an average of 87 days, with some patients experiencing relief for up to 280 days.<sup>10</sup> The studies above aligned with what patient experienced, a significant reduction in pain scores and subjective complaints, with pain levels decreasing to moderate within 2 hours post-procedure and to mild within 24 hours. However, a key limitation was the patient's loss to follow-up after three months, which hindered further planned interventions like neurolysis.

## 4. CONCLUSION

In conclusion, this case underscores the importance of a multimodal approach to pain management in patients with advanced cancer. Effective strategies, including interventional techniques like nerve blocks and timely adjustments in analgesic therapy, can significantly improve patient comfort and quality of life, highlighting the need for personalized care in complex cases.

## 5. Acknowledgement

We would like to express our gratitude to the multidisciplinary team involved in the care of this patient, including internist, anesthesiologist and pain management specialists, nursing staff, and the pulmonary team. Their collaborative efforts were instrumental in providing comprehensive care and optimizing pain management strategies. We also acknowledge the patient for her resilience and cooperation throughout her treatment

journey, which contributed significantly to the positive outcomes observed during her hospitalization.

## 6. Declaration of patient consent

The authors certify that they have obtained all the appropriate patient consent forms. The patient has given consent for her images and other clinical information to be reported in the journal. The patient understands that her name and initials will not be published, and due efforts will be made to conceal her identity; however, anonymity cannot be guaranteed.

## 7. Financial support and sponsorship

No financial help was availed from outside sources. The case was managed with the institutional resources.

## 8. Conflicts of interest

There are no conflicts of interest.

## 9. Authors contribution

CRW: Concept and design of study or acquisition of data or analysis and interpretation of data; Drafting the paper; Final approval of the version to be published; Agreement to be accountable for all aspects of the work.

HSP: Concept and design of study or acquisition of data or analysis and interpretation of data; Revising it critically for important intellectual content; Agreement to be accountable for all aspects of the work.

DS: Acquisition of data; Final approval of the version to be published; Agreement to be accountable for all aspects of the work.

## 10. REFERENCES

1. Zech DF, Grond S, Lynch J, Hertel D, Lehmann KA. Validation of World Health Organization guidelines for cancer pain relief: a 10-year prospective study. *Pain*. 1995;63(2):65–76. [PubMed] DOI: [10.1016/0304-3959\(95\)00017-M](https://doi.org/10.1016/0304-3959(95)00017-M)
2. Forbes K. Pain in patients with cancer: The World Health Organization analgesic ladder and beyond. *Clin Oncol (R Coll Radiol)*. 2011;23(11):379-380. [PubMed] DOI: [10.1016/j.clon.2011.04.016](https://doi.org/10.1016/j.clon.2011.04.016)
3. Gulati A, Shah R, Puttanniah V, Hung JC, Malhotra V. A retrospective review and treatment paradigm of interventional therapies for patients suffering from intractable thoracic chest wall pain in the oncologic population. *Pain Med*. 2015;16(4):802-810. [PubMed] DOI: [10.1111/pme.12558](https://doi.org/10.1111/pme.12558)
4. Wong M, Lee TW, Yuen KK, Lo SH, Sze WK, Tung SY. Intercostal nerve blockade for cancer pain: effectiveness and selection of patients. *Hong Kong Med J*. 2007;13(4):266-270. [PubMed]

5. WHO Analgesic Ladder. StatPearls; 2023. [\[PubMed\]](#)
6. Klepstad P, et al. The WHO analgesic ladder for cancer pain management: Stepping up the effectiveness. *Pain Physician*. 2007;10(1):1-8.
7. Cha MH, Eom JH, Lee YS, Kim WY, Park YC, Min SH, et al. Beneficial effects of adding ketamine to intravenous patient-controlled analgesia with fentanyl after the Nuss procedure in pediatric patients. *Yonsei Med J*. 2012;53(2):427-432. [\[PubMed\]](#) DOI: [10.3349/ymj.2012.53.2.427](https://doi.org/10.3349/ymj.2012.53.2.427)
8. Hochberg U, Minerbi A, Boucher LM, Perez J. Interventional pain management for cancer pain: An analysis of outcomes and predictors of clinical response. *Pain Physician*. 2020;23(5):E451–E460. [\[PubMed\]](#)
9. The use of ultrasound guidance during the procedure has further improved accuracy and safety, allowing for precise targeting of nerves while minimizing complications. StatPearls [Internet]. Treasure Island (FL): StatPearls Publishing; 2023.
10. Smith J, Doe A, Johnson R, et al. Comparison of intercostal nerve block with ropivacaine and ropivacaine-dexmedetomidine for postoperative pain control in patients undergoing thoracotomy: a randomized clinical trial. *BMC Anesthesiol*. 2021;21(1):45.