

## CORRESPONDENCE

## AIRWAY MANAGEMENT

# An innovative technique for best use of Macintosh laryngoscope converted into videolaryngoscope

Teena Bansal <sup>1</sup> Mamta Jain <sup>2</sup>, Anish Kumar Singh <sup>3</sup>, Jatin Lal <sup>4</sup>, Suresh Singhal <sup>5</sup>

### Author affiliations:

1. Teena Bansal, Professor, Deptt of Anaesthesiology & Critical Care, Post Graduate Institute of Medical Sciences, Rohtak-124001, Haryana, India; E-mail: [aggarwalteenu@rediffmail.com](mailto:aggarwalteenu@rediffmail.com)
2. Mamta Jain, Associate Professor, Deptt of Anaesthesiology & Critical Care, Post Graduate Institute of Medical Sciences, Rohtak-124001, Haryana, India; E-mail: [aggarwalteenu@rediffmail.com](mailto:aggarwalteenu@rediffmail.com)
3. Anish Kumar Singh, Associate Professor, Deptt of Anaesthesiology & Critical Care, Post Graduate Institute of Medical Sciences, Rohtak-124001, Haryana, India; E-mail: [anishsingh79@gmail.com](mailto:anishsingh79@gmail.com)
4. Jatin Lal, Professor, Deptt of Anaesthesiology & Critical Care, Post Graduate Institute of Medical Sciences, Rohtak-124001, Haryana, India; E-mail: [dr.jatinlal@gmail.com](mailto:dr.jatinlal@gmail.com)
5. Suresh Singhal, Senior Professor & Head, Deptt of Anaesthesiology & Critical Care, Post Graduate Institute of Medical Sciences, Rohtak-124001, Haryana, India; E-mail: [ssinghal12@gmail.com](mailto:ssinghal12@gmail.com)

**Citation:** Bansal T, Jain M, Singh AK, Lal J, Singhal S. An innovative technique for best use of Macintosh laryngoscope converted into videolaryngoscope. *Anaesth. pain intensive care* 2024;28(6):1138-1139.

**DOI:** [10.35975/apic.v28i6.2633](https://doi.org/10.35975/apic.v28i6.2633)

**Correspondence:** Dr. Teena Bansal; E-mail: [aggarwalteenu@rediffmail.com](mailto:aggarwalteenu@rediffmail.com)

Videolaryngoscopes (VLS) improve the visualisation of the larynx, making intubation easier. However, cost constraints limit their use particularly in resource limited settings where access to VLS is needed.<sup>1</sup> Macintosh laryngoscope converted into VLS using endoscope camera is highly cost effective and can replace VLS to an extent and may prove a boon for airway management.<sup>2,3</sup> However, VLS doesn't always guarantee easier passage of the endotracheal tube (ETT) despite of good laryngeal view, hence may result in longer time for intubation. We wish to highlight an innovation in the technique for its best use.

We wish to share our experience regarding intubation using a Macintosh laryngoscope converted into VLS (Figure 1 & 2). In some of the patients, we noticed Cormack-Lehane (CL) view grade 1 (POGO 100%) (Figure 3). But difficulty in introducing the ETT was noticed. We withdrew laryngoscope slightly and deliberately obtained partially restricted view of vocal cords such that earlier CL grade 1 got converted to grade 2 a (POGO 50%) (Figure 4). Now we were able to negotiate the ETT easily.

Factor responsible for determining the success and ease of endotracheal intubation using video laryngoscope is ease of manoeuvring the tracheal tube inside glottis after proper visualisation. Use of a stylet and proper contouring of ETT helps to facilitate the passage of ETT through the glottis using VLS.<sup>4</sup> We tried both these methods but these methods couldn't guide the ETT into the glottis.

Full glottic view is the view which is obtained when the tip of laryngoscope blade is positioned at the vallecula. Partially restricted view is the view which is 50% or less than 50% of actual glottis opening. This is achieved by deliberately positioning the tip of laryngoscope away from vallecula. Problems that can delay intubation using video-laryngoscope despite a good laryngeal view include difficulty in elevating the ETT tip from the posterior pharynx to access the glottic opening. More proximal position of the



laryngoscope blade and camera lens in partially restricted glottic view affords wider field of view allowing earlier visualisation and redirection of the advancing ETT. In addition, this view decreases the viewing angle, allows the glottis to drop which further helps in the redirection of ETT and hence makes intubation easy.<sup>5</sup>

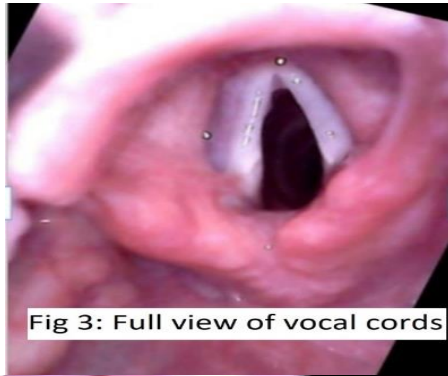

Fig 3: Full view of vocal cords

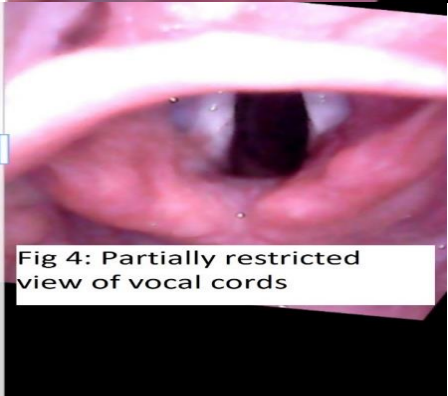


Fig 4: Partially restricted view of vocal cords

In this way, this technique decreases the intubation time. Further, no technical difficulty was noted during insertion of ETT using this technique. As such there is no limitation of this technique.

We have used this technique successfully for nasotracheal intubation as well as intubation in paediatric patients. Further, we have used this

technique via left molar approach also in a patient with massive neurofibroma of face.

Partially restricted view technique provides new insight and knowledge to improve the success of intubation as well as it also decreases the time of intubation using endoscopic camera assembled on Macintosh laryngoscope. We wish to highlight here that this partially restricted view technique will help readers a lot. The readers can learn and apply it efficiently.

#### Conflict of interests

None declared by any of the authors.

#### Author contribution

noted during insertion of ETT using this technique. As such there is no limitation of this technique.

All authors too part in the experiment and the preparation of this manuscript/

#### REFERENCES

1. Wallace CD, Foulds LT, Mcleod GA, Younger RA, Mcguire BE. A comparison of the ease of tracheal intubation using a McGrath MAC laryngoscope and a standard Macintosh Laryngoscope. *Anaesthesia* 2015;70:12281-5.
2. Sukmono B, Manggala SK, Auerkari AN, Christina B. Comparison of self-assembled video laryngoscope versus McGrath MAC. *Indian J Anaesth* 2022;66:350-7.
3. Ali QE, Nisanth NS, Amir SH, Rahat A. Intubation characteristics using modified USB videolaryngoscope: a prospective, randomized study. *Indian J Anaesth* 2023;7:S106-12.
4. Niforopoulou P, Pantazopoulos I, Demestihia T, Koudouna E, Xanthos T. Videolaryngoscopes in the adult airway management: A topical review of the literature. *Acta Anaesthesiol Scand* 2010;54:1050-61.
5. Gu Y, Robert J, Kovacs G, Milne AD, Morris I, Hung O, et al. A deliberately restricted laryngeal view with the Glidescope videolaryngoscope is associated with faster and easier tracheal intubation when compared with a full glottic view: a randomized clinical trial. *J Can Anesth* 201;63:928-37.