

CASE SERIES

PAIN MANAGEMENT

Bertolotti's syndrome as an uncommon cause of LBP; a case series

Liaquat Ali ¹, Muhammad Ali Abbas ², Huma Hanif ³, Sana Nasir ⁴, Umer Ali ⁵

Author affiliations:

1. Liaquat Ali, Professor & HoD, Department of Anesthesiology, Critical Care & Pain Medicine, Foundation University School of Health Sciences (FUSH/FUI), Fauji Foundation Hospital, Rawalpindi, Pakistan; E-mail: liaquatanaes@gmail.com
2. Muhammad Ali Abbas, Consultant Anesthetist, CMH, Lahore. Pakistan; E-mail: dralirizz@gmail.com
3. Huma Hanif, Registrar Anesthesiology. Department of Anesthesiology, Critical Care & Pain Medicine, Foundation University School of Health Sciences (FUSH/FUI), Fauji Foundation Hospital, Rawalpindi, Pakistan; E-mail: humabirdie@gmail.com
4. Sana Nasir, Post Graduate Resident Anesthesiology. Department of Anesthesiology, Critical Care & Pain Medicine, Foundation University School of Health Sciences (FUSH/FUI), Fauji Foundation Hospital, Rawalpindi, Pakistan; E-mail: sananasir1418@gmail.com
5. Umer Ali, Consultant Anesthesiology. Department of Anesthesiology, Critical Care & Pain Medicine, Foundation University School of Health Sciences (FUSH/FUI), Fauji Foundation Hospital, Rawalpindi, Pakistan; E-mail: umer6oct@gmail.com

Correspondence: Maj Gen (Retd) Professor Liaquat Ali; **E-mail:** liaquatanaes@gmail.com; **Phone:** +93 321 5836898

ABSTRACT

Lumbosacral transition of L5 vertebra is an anatomical variation. The transverse process of L5 vertebra may become enlarged and form a pseudo joint with ilium or sacrum, leading to low back pain, especially in young adults due to change in biomechanical properties of the lumbar spine. This condition is referred to as Bertolotti's syndrome. Here we report an ongoing case series of 11 of our patients in whom we studied the impact of steroid and local anesthetic infiltration as a treatment approach.

The primary objective of this case series is to comprehensively investigate and report the clinical characteristics, radiological findings, treatment modalities, and outcomes in a group of 11 patients diagnosed with Bertolotti's syndrome, thus adding to the existing body of knowledge about Bertolotti's syndrome by focusing on its occurrence and management in younger individuals, which is relatively less explored in the literature.

Abbreviations: VAS - Visual Analogue Scale; FABER - Flexion Abduction External rotation; SLR - Straight Leg Raising

Keywords: Bertolotti's Syndrome, Low back pain, Lumbosacral transition

Citation: Ali L, Abbas MA, Hanif H, Nasir S, Ali U. Bertolotti's syndrome as an uncommon cause of LBP; a case series. *Anaesth. pain intensive care* 2023;27(6):593-599; **DOI:** [10.35975/apic.v28i3.2484](https://doi.org/10.35975/apic.v28i3.2484)

Received: January 28, 2024; **Reviewed:** March 19, 2024; **Accepted:** April 03, 2024

1. INTRODUCTION

The initial account of Bertolotti's syndrome (BS) dates back to 1917, and it was characterized by an atypical enlargement of the transverse process, specifically in the lowest lumbar vertebra, i.e., L5. It forms a pseudo joint by connecting with either the sacrum, the ilium or both. This intriguing and frequently underdiagnosed condition has garnered increasing attention in the fields of orthopedics, radiology, and pain management in the recent years. The syndrome is named after the Italian radiologist Mario Bertolotti (1876-1957) who first described it in the early 1900s. Bertolotti was renowned for this research on the connection between the

transverse processes of the L5 vertebra and the sacrum, as detailed in his 1917 publication. BS can lead to a wide spectrum of clinical presentations, including LBP, radiculopathy, and sacroiliac joint dysfunction. Low back pain (LBP) is one of the most common reasons for taking medical advice and 80% of adults seek help at some stage. The articulation may be partial or total and unilateral or bilateral. Initially, it was believed that 4% to 8% of the population would experience the effects of this anatomical difference, but current estimates suggest a higher prevalence of around 30%⁽¹⁾. Opinions on the treatment of BS are diverse, but no consensus has been reached yet. We offer a case series involving 11

symptomatic cases of BS, which were effectively treated using fluoroscopy guided injections of local anesthetic and steroids in the pseudo joint with immediate improvement in the visual analogue scale (VAS) score.

The pre-anesthesia assessment for every patient was meticulously conducted, adhering to established protocols. Prior to any procedure, informed consent was obtained, ensuring patient understanding and agreement. Intravenous (IV) lines were securely placed, meeting standard safety measures. Two monitors, encompassing non-invasive blood pressure (NIBP), pulse oximetry, and ECG, were attached to monitor vital signs continuously. Emergency drugs and ventilation equipment were standby, ready for immediate use if required. As part of pre-operative care, midazolam 1 mg IV was administered for anxiolysis, promoting patient comfort and relaxation. All equipment used was sterilized, maintaining aseptic conditions throughout the procedure. Post-procedure, patients were diligently monitored for vital signs for a duration of one hour, ensuring optimal recovery and early detection of any complications. To keep the description brief, details of the procedure were provided only in the first case.

The first case in this series introduces a 40 years old male surgeon, who presented with BS. This case serves as an illustration of the syndrome's clinical presentation and the diagnostic and therapeutic challenges encountered in young individuals. It was the first case that was diagnosed from Pakistan in 2020.

2. CASE SERIES

Case 1

A 40 years old male surgeon presented with low backache not responding to oral and intravenous pain killers which prevented him from carrying out his daily routine activities. The pain was severe, excruciating and radiating to right buttock with a VAS score to be 8/10. There was tenderness over right sacroiliac area provoked by deep palpation. Provisional diagnosis of right sacroiliitis was made. Subsequently, fluoroscopy was done which revealed anomalous articulation between enlarged right L5 transverse process with ipsilateral ala of sacrum forming a pseudo arthrosis with maximum tenderness over it. Treatment planned included injecting local anesthetic and steroids in the joint area under fluoroscopy. Pre-anesthesia assessment was done, written informed consent was taken, IV line secured and standard monitors attached. Inj. midazolam 1 mg IV given for anxiolysis. Emergency drugs and ventilation equipment were on standby. The skin was prepared with antiseptic solution and draped. After local skin infiltration with 2% lignocaine plain, 22 gauge Quincke spinal needle was advanced between the right transverse

process of L5 vertebra and the ala of the sacrum under fluoroscopic guidance (Figure 1). Then 0.5 mL of contrast (Omnipaque) was injected. After contrast confirmation 0.1% bupivacaine and 40 mg of triamcinolone (total volume 4 mL) was injected. Pain was relieved immediately, and the VAS score was recorded to be 2/10. Patient was reassured and celecoxib 100 mg twice daily was prescribed for two weeks. At two weeks follow-up the patient had a complete pain relief without analgesics. At one-year follow-up he was symptom-free without any medication.

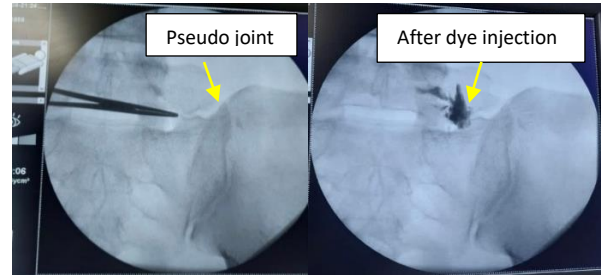


Figure 1: Fluoroscopy guided infiltration of local anesthetic + steroids in the pseudo joint (case 1)

Case 2

A 28-y old lady presented in our pain clinic with a history of LBP for the last one-year. Pain aggravated on standing from sitting position and there was tenderness below L5 area on right side with a VAS score of 7/10. Pain radiated to mid gluteal region and iliac spine on right side. FABER test was positive on her right side. Diagnosis of SI joint arthropathy was made on clinical examination. On X-ray lumbosacral spine, there was incidental finding of pseudo joint on right side between right transverse process of L5 vertebra and the ala of the sacrum (Figure 2) which was later confirmed via fluoroscopy. After contrast dye confirmation LA plus steroids were injected between right transverse process of L5 vertebra and the ala of her sacrum under fluoroscopy, achieving a VAS score of 1/10 immediately. At one-year follow-up, she was symptom free without any medication.

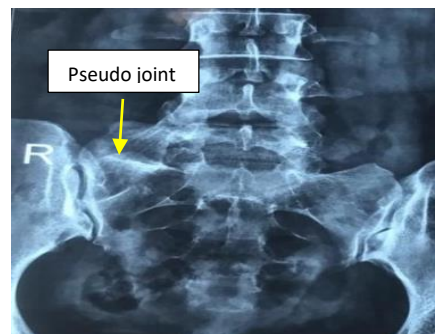


Figure 2: X-ray lumbosacral spine showing pseudo joint on right side (case 2)

Case 3

A 60-y old lady, known asthmatic, obese, presented with history of LBP radiating to both buttocks up to inferior gluteal region for the previous five years. Her VAS score was to be 9/10. On examination there was tender SI joint area. FABER test was positive and SLR test was negative bilaterally. On X-ray there were pseudo joints between L5 transverse process and ilium on each side. After contrast dye confirmation 0.1% bupivacaine and 40 mg of triamcinolone (total volume 4 mL) was injected in both pseudo joints. VAS score decreased from 9/10 to 2/10. On one-year follow-up the patient was symptom free without any medication.

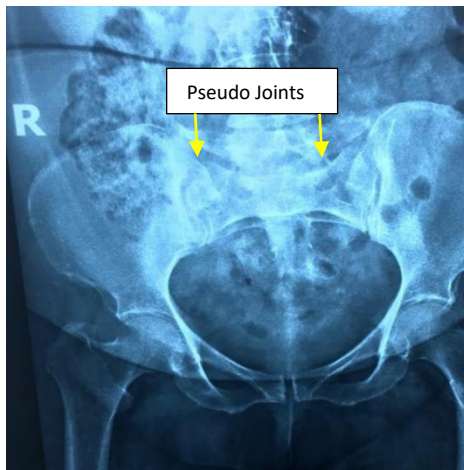


Figure 3: X-ray Lumbosacral spine showing bilateral pseudo joints

Case 4

A 58-year-old male presented to us with lower backache for the past two years. Pain was radiating to mid gluteal region on right side with a VAS score of 8/10. On examination there was local tenderness below L5 area and lateral to SI joint. X-ray revealed, pseudo joint (BS) between L5 transverse process, sacral ala and ilium (Figure 4).

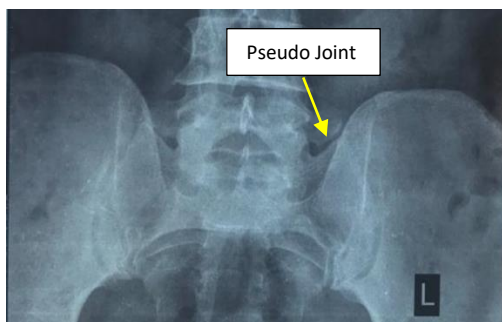


Figure 4: X-ray Lumbosacral spine showing pseudo joint between L5 transverse process, sacral ala and ilium

After contrast dye confirmation 0.1% bupivacaine and 40 mg of triamcinolone (volume 4 mL) was injected in the pseudo joint under fluoroscopy. VAS score decreased from 8/10 to 1/10. At one-year follow-up patient was symptom free without any medication.

Case 5

An 85-year-old lady presented with complaint of lower backache for the past 10 y. Pain radiated to right buttock area, posterior thigh and right leg calf region. There was history of numbness in posterolateral thigh and calf. On examination there was tenderness in and around SI Joint and in piriformis muscle. FABER test was positive. Differential diagnosis of SI joint arthropathy and piriformis syndrome was made. Incidental finding of pseudo joint between sacral ala and L5 transverse process was made on fluoroscopy (Figure 5). LA and steroids were injected in the pseudo joint under fluoroscopy. VAS score decreased from 8/10 to 1/10. At one-year follow-up patient was symptom free without any medication.

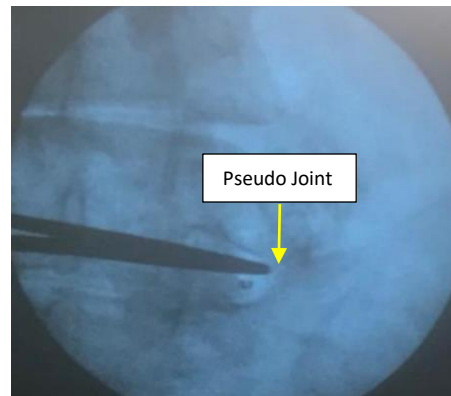


Figure 5: Fluoroscopy guided injection in the pseudo joint

Case 6

A 46-year-old female, known diabetic, on oral hypoglycemics, presented with lower backache for the past 18 y after C-section. She took NSAIDs on and off for her pain. A BS was not diagnosed timely, she underwent laminectomy in 2018 by spinal surgeon but pain didn't resolve as the cause of the pain was not addressed. After 2 y she presented to the pain clinic with severe bilateral lower backache radiating to knees. Pain exaggerated on sitting and relieved on walking. Patient was unable to do household chores. Her VAS score was 8/10. FABER test, pelvic compression test and sacral thrust test were positive. Diagnosis of pseudo joint between sacral ala and L5 transverse process was made on X-ray lumbosacral spine (Figure 6). After contrast dye confirmation 0.1% bupivacaine and 40 mg of

triamcinolone were injected in the pseudo joint under fluoroscopy (Figure 6). VAS score improved from 8/10 to 1/10. Patient reassured and celecoxib 100 mg twice daily was prescribed for two weeks. At two weeks follow-up patient had a complete pain relief without analgesics. At one-year follow-up patient was symptom free without any medication.

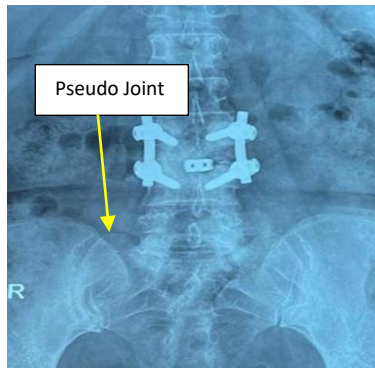


Figure 6: X-ray lumbosacral spine showing pseudo joint between L5 transverse process and sacral ala.

Case 7

A 27-year-old female presented with bilateral LBP for two days. Pain was acute in onset, more on right side radiating to right buttock with a VAS score of 7/10. The pain was so severe that she was unable to sit properly. Pain was burning in character, exaggerated by sitting, partially relieved by walking and not relieved by NSAIDs. Diagnosis of pseudo joint between right L5 transverse process and sacrum and ileum was made on x-ray (Figure 7). After contrast dye confirmation LA plus steroids were injected in the pseudo joint under fluoroscopy. VAS score decreased from 8/10 to 1/10 after 10 min. At two and one-year follow-up patient was symptom free without any medication.

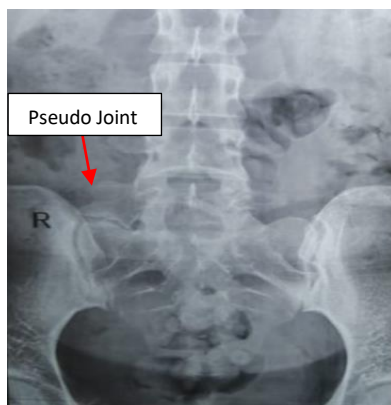


Figure 7: X-ray lumbosacral spine showing pseudo joint

Case 8

A 49-year-old male, presented with 15 days history of severe LBP. Pain was severe in intensity, more on right side, radiating to right buttock. It started after heavy weight lifting. Patient had difficulty in walking and standing with a VAS score of 9/10. Pain was not relieved by NSAIDs. Triamcinolone 40 mg with bupivacaine 5 mg injected in bilateral pseudo joints between transverse process and ileum under fluoroscope (Figure 9). After 10 min VAS score decreased to 1/10. At two weeks and one-year follow-up visits patient was symptom free without any medication.

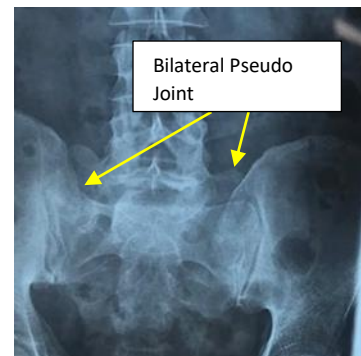

Figure 8: X-ray lumbosacral spine showing pseudo joint

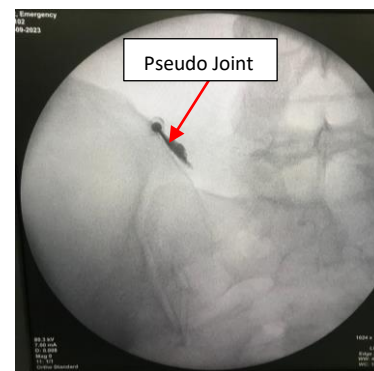


Figure 9: Fluoroscopy guided infiltration of LA with steroid in the pseudo joint

Case 9

A 47-year-old female, known diabetic and hypertensive for 10 y, presented with LBP (VAS score of 8/10), near right posterior superior iliac spine radiating towards right buttock. Her pain was gradual in onset, intermittent, moderate in intensity, sometimes associated with numbness and aggravated on standing and walking, and not relieved by strong painkillers. On examination, right posterior superior iliac spine area was tender. X-ray lumbosacral spine (Figure 10) showed narrow space between L5-S1 vertebrae, grade 1 spondylosisthesis and

right sided transitional vertebra (pseudo articulating joint with sacrum) at L5. After contrast dye confirmation LA plus steroids were injected in the pseudo joint between the right sided large transverse process of L5 and sacrum under fluoroscopic guidance (Figure 10). Her VAS score improved to 2/10. At two weeks and one-year follow-up patient was symptom free without any medication.

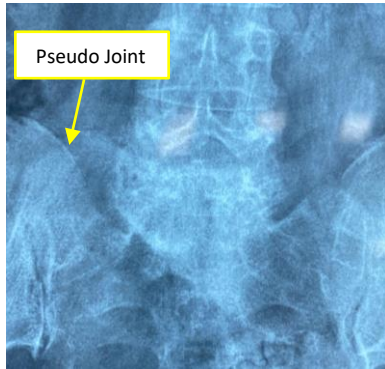


Figure 10: X-ray lumbosacral spine showing pseudo joint

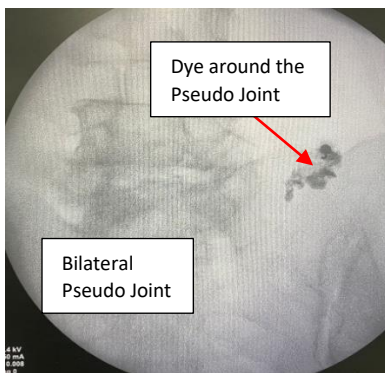


Figure 11: Fluoroscopy guided infiltration of LA with steroid in the pseudo joint

Case 10

A 45-year-old lady, presented with 5 y history of LBP. On examination under fluoroscopic, there was a finding of BS along with deformed/displaced coccyx bone. X ray confirmed the diagnosis of coccydynia and BS. Using fluoroscopy, pseudo joint between L5 transverse process and ileum was injected with local anesthetic and steroid (Figure 12). VAS score improved from 8/10 to 2/10. At follow-up, she was symptom free without any medication.

Case 11

A 25-y old male presented with complaint of LBP on and off since last 4 y. Pain was mostly in the midline and paramedian region, non-radiating, with increasing intensity in past 3 months. It was so severe

that patient was unable to perform his routine tasks. On presentation his VAS score was 9/10, FABER test was positive. Bilateral SI joint and L4, L5 facet tenderness. Provisional diagnosis of SI joint arthropathy and lumbar facet joint syndrome was made. On radiological examination lumbar transitional vertebra was found making pseudo joint with sacrum. Pseudo joint and facets were injected with LA with steroid and VAS score decreased from 9/10 to 2/10. At two weeks and one-year follow-up patient was symptom free without any medication.

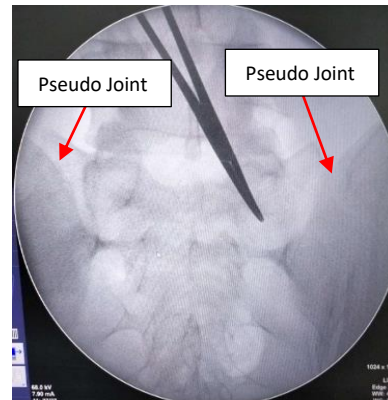


Figure 12: Fluoroscopy showing pseudo joint

3. RESULTS

In this series of cases, patients sought medical attention due to LBP and were subsequently diagnosed with BS based upon clinical presentations as well as radiological and fluoroscopic findings. Among the 11 patients, 3 had bilateral joint involvement while the remaining 8 had unilateral joint involvement (Table 1).

Among the 11 cases, 7 (64%) were females and 4 (36%) were males, with 72% falling within the age group of 25-50 y, and the remaining 28% in whom the diagnosis was delayed (due to misdiagnosis) in the age group > 50 y (Table 2). This distribution indicates a higher prevalence of BS in the younger population.

Local anesthetic infiltration was administered, and the VAS scores were recorded before and after the

Table 1: Location of the pseudo-joint involvement among the patients.			
Involvement	Between transverse process and ala of sacrum	Between transverse process and ileum	Between transverse process, ileum and sacral ala
Unilateral (08)	4 (R) 1 (L)	1 (R)	2 (R)
Bilateral (03)	1	2	0

Table 2: Demographic variables of Study population.

Cas e	Age (years)	Sex	Length of history (Months)	VAS Before LAI	VAS after LAI at 30 min interval	VAS after LAI at 2 weeks interval
1	40	M	3	8/10	2/10	1/10
2	28	F	12	7/10	1/10	1/10
3	60	F	60	9/10	2/10	1/10
4	58	M	24	8/10	1/10	1/10
5	85	F	120	8/10	1/10	1/10
6	46	F	2	8/10	1/10	1/10
7	27	F	0.5	7/10	2/10	1/10
8	49	M	0.5	9/10	1/10	1/10
9	47	F	0.5	8/10	2/10	1/10
10	45	F	60	8/10	2/10	1/10
11	25	M	48	9/10	2/10	1/10

procedure. The application of a paired t-test yielded a T value of 24.486 and a P = 0.000. The results were considered statistically significant.

4. DISCUSSION

Bertolotti was the first person who demonstrated anomalous anatomic enlargement of most caudal lumbar vertebra in 1917.² Enlarged transverse process of lumbar vertebrae may articulate with sacrum or ilium and cause LBP. Quinlan et al. reported a higher incidence of LBP, up to 11%, in young individuals afflicted with this syndrome. In the examination of LBP in young individuals, it is essential to include BS as one of the potential differential diagnoses.³ Definitive mechanism of pain in this syndrome is still unknown. Spinal stenosis and nerve root canal stenosis exhibited a higher prevalence at or near the interspace above the transitional vertebra compared to other levels. Degenerative changes at the junction between the transverse process of the transitional vertebra and the pelvis were infrequent. When observed, there was no significant correlation with the reported side of pain. The hypothesis suggests that hypermobility and altered stresses may concentrate in the spine at the level immediately above a lumbar transitional vertebra. Elster et al. concluded that the incidence of spinal stenosis and degenerative disc disease was almost nine times higher at level adjacent to transitional vertebra.⁴ These changes lead to abnormal biomechanical stress and cause LBP. Vergauwen et al. suggested that the presence of a lumbo-sacral transitional vertebra alone does not pose a risk factor for degenerative changes in the spine. However, if degeneration does occur, it is more inclined to manifest

at the disc level above the lumbo-sacral transitional vertebrae.⁵

The detection and classification of lumbo-sacral transitional vertebrae are frequently prone to inaccuracies in standard AP radiographs and MRI. Enhanced accuracy can be achieved through the utilization of whole-spine images and consideration of geometric relationships between the sacrum and lumbar vertebra. A positive radionuclide study,

coupled with a favorable response to a diagnostic local anesthetic injection, aids in identifying the transitional vertebra as a noteworthy pain source. Surgical resection is selectively considered for a subset of lumbo-sacral transitional vertebrae patients, who do not respond to conservative treatment and for whom the pain is conclusively linked to the anomalous pseudoarticulation.⁶ The existence of sclerosis and/or osteoarthritis at the pseudoarticulation correlated with higher pain scores. Female participants reported experiencing more severe pain.⁷ Conservative approaches for managing BS encompass modifications in activity, pharmacologic therapy, physical therapy, and interventional treatment. It is crucial to initiate treatment with conservative approaches, such as activity modification, physiotherapy, steroid injections, and LA injections.⁸ If these methods prove ineffective, it may be necessary to consider interventional or surgical management. Surgical options, although only marginally more effective than non-surgical approaches, vary based on the preoperative degeneration of the spine. Both resection and posterolateral fusion are equally viable methods, albeit carrying general surgical risks and the potential for revision surgery and further degeneration of the adjacent level. Various forms of radiofrequency ablation (continuous RFA, pulsed RFA, cold RFA, or bipolar RFA) may present effective treatment options for individuals with BS.⁹ Afana H, et al. suggested in a recent case report that the newly proposed modified mini-open tubular microsurgical transverse processotomy (MO-TMTP), guided by 3D intraoperative imaging and intraoperative neuromonitoring (IONM), appears to be a secure and efficient procedure for specific patients with BS. This

approach is recommended for individuals who have not responded to conservative treatments and have encountered temporary pain relief following the injection of pseudo articulation with steroids and local anesthetics.¹⁰

5. CONCLUSIONS

When investigating low back pain in young individuals, it is important to include Bertolotti's syndrome in the list of potential differential diagnoses. Radiographic investigation is usually required to confirm or rule out the diagnosis of Bertolotti's syndrome. The debate between conservative and operative treatment persists. In our case series, the symptoms were successfully resolved through the infiltration of local anesthetic and steroids into the pseudo-arthrosis, guided by fluoroscopy.

6. Conflict of Interest

None declared by the authors.

7. Authors' contribution

LA: Supervisor, managed the patients in case series, manuscript review

MAB: Case management, data accumulation.

HH, SN, UA: literature review, manuscript writing

8. REFERENCES

1. Barkhane Z, Belaaroussi S, Foudail M. Bilateral Bertolotti's Syndrome: A Case Report of an Uncommon Presentation of Chronic Low Back Pain in an Elder Patient. *Cureus*. 2022;14(7):e26569. [PubMed] DOI: [10.7759/cureus.26569](https://doi.org/10.7759/cureus.26569)
2. Miller AE, Zhang A. Bertolotti Syndrome. In: StatPearls [Internet]. Treasure Island (FL): StatPearls Publishing; 2023. Available from: <http://www.ncbi.nlm.nih.gov/books/NBK585032/>
3. Quinlan JF, Duke D, Eustace S. Bertolotti's syndrome: A cause of back pain in young people. *J Bone Joint Surg Br*. 2006;88-B(9):1183–6. [PubMed] DOI: [10.1302/0301-620X.88B9.17211](https://doi.org/10.1302/0301-620X.88B9.17211)
4. Elster AD. Bertolotti's syndrome revisited. Transitional vertebrae of the lumbar spine. *Spine (Phila Pa 1976)*. 1989 Dec;14(12):1373–7. [PubMed]
5. Vergauwen S, Parizel PM, van Breusegem L, Van Goethem JW, Nackaerts Y, Van den Hauwe L, et al. Distribution and incidence of degenerative spine changes in patients with a lumbo-sacral transitional vertebra. *Eur Spine J*. 1997 May;6(3):168–72. [PubMed] DOI: [10.1007/BF01301431](https://doi.org/10.1007/BF01301431)
6. Jancuska JM, Spivak JM, Bendo JA. A review of symptomatic lumbosacral transitional vertebrae: Bertolotti's syndrome. *Int J Spine Surg*. 2015;9:42. [PubMed] DOI: [10.14444/2042](https://doi.org/10.14444/2042)
7. Stebbings S, White C, Doyle T. Bertolotti syndrome: an under recognized cause of inflammatory back pain? *Ann Rheum Dis*. 2023;82(Suppl 1):1754. DOI: [10.1136/annrheumdis-2023-eular.2128](https://doi.org/10.1136/annrheumdis-2023-eular.2128)
8. McGrath K, Schmidt E, Rabah N, Abubakr M, Steinmetz M. Clinical assessment and management of Bertolotti Syndrome: a review of the literature. *Spine J*. 2021;21(8):1286–96. [PubMed] DOI: [10.1016/j.spinee.2021.02.023](https://doi.org/10.1016/j.spinee.2021.02.023)
9. Crane J, Cragon R, O'Neill J, Berger AA, Kassem H, Sherman WF, et al. A Comprehensive Update of the Treatment and Management of Bertolotti's Syndrome: A Best Practices Review. *Orthop Rev (Pavia)*. 2021;13(2):24980. [PubMed] DOI: [10.52965/001c.24980](https://doi.org/10.52965/001c.24980)
10. Afana H, Raffat M, Figueiredo N. Surgical pitfalls in Bertolotti's syndrome management: a case report. *Medicine (Baltimore)*. 2022;101(50). [PubMed] DOI: [10.1097/MD.000000000032293](https://doi.org/10.1097/MD.000000000032293)