

CASE REPORT

PERIOPERATIVE MEDICINE

Double trouble – refractory hypertension during adrenalectomy due to an accessory vein: a case report

Catarina Morgado¹, Rita Inácio², Catarina Nunes Marques³

Author affiliations:

1. Catarina Morgado, Fellow of Intensive Care, IC19 2720-276, Amadora, Portugal; E-mail: catinarf Morgado@hotmail.com; ORCID: {0000-0002-8090-2818}
2. Rita Inácio, Hospital Attendant of Anesthesiology, IC19 2720-276, Amadora, Portugal; E-mail: rita.g.inacio@gmail.com; ORCID: {0000-0001-6368-6466}
3. Catarina Nunes Marques, Hospital Attendant of Anesthesiology, IC19 2720-276, Amadora, Portugal; E-mail: cfnmarques@hotmail.com; ORCID: {0000-0002-9889-6604}

Correspondence: Catarina Nunes Marques; E-mail: cfnmarques@hotmail.com

ABSTRACT

Pheochromocytoma is a rare tumor that releases catecholamines. The symptoms include hypertension, paroxysmal headaches, diaphoresis and palpitations. The diagnosis is made with elevated catecholamines and a suprarenal mass in abdominal CT scan. The treatment includes pharmacological preparation, with suppression of the adrenergic receptors, and adrenalectomy. The most important step during surgery is the resection of adrenal vein. After that, the release of catecholamines is totally suppressed. This results in hypotension or even shock. We present an adrenalectomy, in which invasive arterial pressure monitoring acknowledge hemodynamic changes that were not expected. This allowed surgeons to realize there was an accessory vein.

Keywords: Adrenalectomy; Anatomical variation; Hypertension; Pheochromocytoma; Adrenal vein.

Citation: Morgado C, Inácio R, Marques CN. Double trouble – refractory hypertension during adrenalectomy due to an accessory vein: a case report. *Anaesth. pain intensive care* 2024;28(2):388–390; DOI: [10.35975/apic.v28i2.2414](https://doi.org/10.35975/apic.v28i2.2414)

Received: October 06, 2023; **Revised:** February 27, 2024; **Accepted:** March 06, 2024

1. INTRODUCTION

Pheochromocytoma is generally a benign catecholamine-producing tumor located in the adrenal glands with an annual incidence in Europe of 0.2 per 100,000 people.^{1,2} Arterial hypertension occurs in about 90% of cases. Other symptoms include tachycardia, palpitations, diaphoresis, cold skin, headache, nausea and/or vomiting.³ The diagnosis is laboratory based, with elevated serum and urinary levels of catecholamine metabolites, accompanied by imaging evidence of the tumor.³

Adrenalectomy is the main treatment, which is curative in more than 90% of cases, with resection of the adrenal vein being a crucial moment of the surgery, suppressing the release of catecholamines in the surgical manipulation of the gland.²

In the preoperative preparation, patients should undergo a period of pharmacological treatment, with α -adrenergic blockade and later, if necessary, β -adrenergic blockade.³

The objectives of the preoperative preparation include blood pressure (BP) < 160/90 mmHg, orthostatic hypotension with systolic BP decrease >15%, electrocardiogram without changes in repolarization and hematocrit normalization.² We present an interesting case of pheochromocytoma of the left adrenal gland. She had paroxysmal episodes of sweating and palpitations, without associated headache and history of weight loss. After resection of the main adrenal vein, there was a sudden elevation of the BP. On exploration an accessory adrenal vein was found, which was resected and the patient got stabilized.

2. CASE REPORT

A female, 74 years old, was followed up in endocrinology for pheochromocytoma of the left adrenal gland. She had paroxysmal episodes of sweating and palpitations, without associated headache and history of weight loss of 20 kg in 5 y. The blood and urine analysis demonstrated an increase in catecholamine metabolites,

10 times above the upper limit of normal. It was identified a left adrenal mass measuring approximately 6.3 x 4.3 x 4.7 cm on abdominal CT, confirmed by metaiodobenzylguanidine (MIBG) scintigraphy. She was considered for left adrenalectomy and was started pharmacological preparation with α and β -adrenergic blockade. She was medicated with doxazosin 4 mg OD and atenolol 25 mg OD, with the need to increase doxazosin to 6 mg OD, due to inadequate blood pressure control.

After 3 months of pharmacological preparation, the patient was asymptomatic, with a sitting blood pressure of 107/60 mmHg, heart rate of 72 bpm, sinus rhythm, without orthostatic hypotension or new electrocardiographic alterations. Hematocrit, glycemia and ionogram were adequate. The transthoracic echocardiogram showed no major changes.

In the operating room, prior to anesthetic induction, she was sedated with target-controlled infusion (TCI) of remifentanyl, proceeding with the placement of an arterial line for adequate blood pressure monitoring. To stabilize the myocardial cell membrane and decrease the hemodynamic response to orotracheal intubation, we administered 2 g of magnesium sulfate. She was also given 100 mg of hydrocortisone to prevent acute adrenal insufficiency. Anesthetic induction was performed with TCI of remifentanyl and propofol. After adequate neuromuscular blockade with rocuronium (TOF 0/4), intubation was performed by direct videolaryngoscopy, preceded by periglottic anesthesia with 10 mL of 2% lidocaine + 1% ropivacaine. Prior to the surgical incision, we performed ultrasound-guided blockade of the transversus abdominis plane bilaterally and infiltration of the laparoscopic ports. During anesthetic induction, the patient remained hemodynamically stable without significant changes in BP (Figure 1).

After placing a central venous catheter, infusions of isosorbide dinitrate, sodium nitroprusside and esmolol were connected. During the first part of the surgery, the patient remained hemodynamically stable, through the titration of the referred infusions. After one hour of the surgery, there was a gradual increase in the BP profile, resistant to the increase of infusions, compatible with the release of catecholamines from tumor manipulation, with a maximum value of 168/80 mmHg, recorded at the time of resection of the adrenal vein.

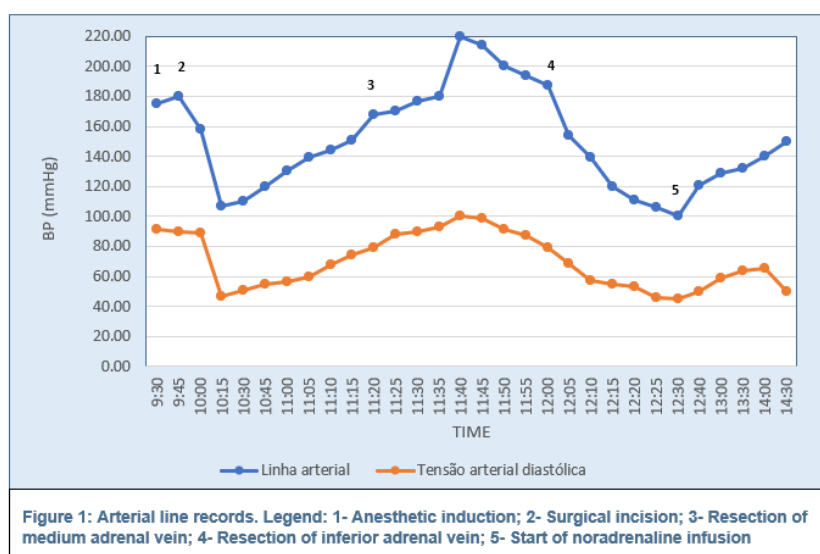


Figure 1: Arterial line records. Legend: 1- Anesthetic induction; 2- Surgical incision; 3- Resection of medium adrenal vein; 4- Resection of inferior adrenal vein; 5- Start of noradrenaline infusion

After venous resection, contrary to expectations, the patient maintained an increasing hypertensive profile and the need to increase doses of antihypertensives to the maximum doses allowable. After excluding the residual effect of circulating catecholamines, the surgical team was asked to interrupt tumor manipulation and bolus of labetalol was administered (5-15 mg) until blood pressure was controlled.

The surgery was resumed and in the face of this intercurrent, a review of the surgical procedure was carried out with the detection of an accessory adrenal vein. The resection of this vein was performed with a subsequent significant decrease in the hemodynamic profile. At that moment, antihypertensive infusions were suspended and noradrenaline infusion was started to maintain a mean BP > 65 mmHg (Figure 1).

The noradrenaline infusion rate remained below 10 $\mu\text{g}/\text{min}$, with normalization of the blood pressure profile. At the end of the surgical procedure, extubation was performed and noradrenaline infusion was stopped. The patient was transferred to the Intensive Care Unit.

3. DISCUSSION

The surgical approach to a patient with pheochromocytoma represents an anesthetic challenge. In the past, adrenalectomies were associated with mortality rates of 45%, usually from cardiovascular causes.^{2,4}

Blood pressure should be controlled at least 15 days before surgery. As first-line drugs are α -receptor antagonists (doxazosin or phenoxybenzamine) that should be suspended 12 and 24 h before surgery, respectively.⁵ Selective β_1 blockers (atenolol,

metoprolol) can be added, after adequate α blockade, in patients who develop reflex tachycardia and to minimize tachyarrhythmias.^{2,4,5} This preoperative BP optimization has resulted in a marked reduction in perioperative mortality to 0 - 6% nowadays.⁴

2 During surgery, invasive monitoring of BP is essential due to the high blood pressure instability and risk of adverse cardiovascular events. The stimulation of catecholaminergic receptors leads⁵ to peripheral vasoconstriction, arterial hypertension, intravascular volume depletion, hyperglycemia, predisposition to myocardial ischemia, increased automaticity and ventricular ectopy, ventricular hypertrophy and heart failure.²

The anesthetic technique should minimize the use of drugs that release histamine (atracurium) and catecholamines (ketamine, ephedrine). Furthermore, it is essential to avoid catecholamine release induced by anesthetic and surgical maneuvers. The use of magnesium sulfate, remifentanyl or dexmedetomidine is effective to control pain and maintain hemodynamic stability.⁴

2 Currently, laparoscopic surgery is preferable reducing recovery time, but maintaining the risk of hemodynamic instability. The use of high pneumoperitoneum pressures contributes to a greater release of catecholamines release.⁵

Intraoperative catecholaminergic storms are frequent, especially during tumor manipulation.⁵ When dealing with hypertensive crises, priority is to use vasodilators that release nitrogen monoxide (sodium nitroprusside, isosorbide dinitrate, nitroglycerin). Drugs with a rapid onset of action and short duration may also be used (phentolamine, urapidil, labetalol). When tachyarrhythmias are encountered, esmolol, a selective β_1 antagonist, is preferred.⁴

After resection of the adrenal vein, there is an abrupt decrease in the activity of the sympathetic system, which can lead to severe hypotension.⁵ These episodes can be attenuated with interruption of vasodilators, fluid therapy and, if necessary, vasopressor support with noradrenaline. In cases of refractory hypotension, vasopressin can be considered.²

The anatomy of the adrenal glands must be previously studied by computed tomography angiography (CTA) or MR angiography (MRA). Anatomical variants of the adrenal gland are rare (5-10%), but in the cases described it is more common to identify an accessory vein on the right (28% vs 1%).⁶ In our patient, an undisclosed accessory vein led to continued hypertension even after

ligation of the main adrenal vein, and its surgical removal relieved the uncontrolled hypertension. Postoperative surveillance is carried out in an Intensive Care Unit for at least 24 h. Continuous monitoring and therapeutic approach to situations of hemodynamic, ventilatory or metabolic instability must be ensured.^{2,3}

4. CONCLUSION

In adrenalectomy, it is the invasive monitoring of arterial pressure that ensures a safety procedure, for both surgical and anesthetic teams. Hemodynamic changes can identify adverse circumstances during surgery. Anatomic variations of adrenal vein are rare but should be considered when the diagnosis is done.

5. Ethical issues

Institutional ethical committee approved this case report. Written consent was obtained from the patient to publish it for educational purposes.

6. Conflict of interest

The study utilized the hospital resources only.

7. Authors' contribution

CM: Literature review, draft of the manuscript

RI: Draft and critical review of the manuscript

CNM: Critical review of the manuscript

8. REFERENCES

1. Castro J, Garcia J. Feocromocitoma. *Acta Med Port.* 1994; 7: 703-709. PMID: [7717117](#), [[Free article](#)]
2. Connor D, Boumphrey S. Perioperative care of pheochromocytoma. *BJA Education.* 2016;16 (5):153-158. DOI: [10.1093/bjaed/mkv033](#) [[Free article](#)]
3. Plouin PF, Gimenez-Roqueplo AP. Pheochromocytomas and secreting paragangliomas. *Orphanet J Rare Dis.* 2006 Dec 8;1:49. PMID: [17156452](#), PMID: [PMC1702343](#), DOI: [10.1186/1750-1172-1-49](#)
4. Serralheiro I, Medeiros L, Teles I, editors. *Abordagem anestésica dos tumores neuroendócrinos.* In: *Manual de procedimentos Oncoanestesia.* 1st ed. Lisboa: Instituto português de Oncologia; 2017. p. 259-271.
5. Fagundes G, Almeida M. Perioperative Management of pheochromocytomas and sympathetic paragangliomas. *Journal of the Endocrine Society.* 2022; 6; 1-8. PMID: [38292595](#), PMID: [PMC10825829](#), DOI: [10.1210/jendso/bvae004](#)
6. Omura K, Ota H, Takahashi Y, Matsuura T, Seiji K, Arai Y, et al. Anatomical Variations of the Right Adrenal Vein: Concordance Between Multidetector Computed Tomography and Catheter Venography. *Hypertension.* 2017 Mar;69(3):428-434. PMID: [28137990](#), DOI: [10.1161/HYPERTENSIONAHA.116.08375](#)