

## CASE REPORT

## CARDIAC ANESTHESIA

# Addressing challenges in anesthesia management for patent ductus arteriosus ligation in a preterm baby: a case report

M. Yusuf Sidang Amin<sup>1</sup>, Ratna Farida Soenarto<sup>2</sup>

**Author affiliations:**

1. M. Yusuf Sidang Amin, Jl. Diponegoro No. 71, Jakarta Pusat, DKI Jakarta 10430, Indonesia; E-mail: [m.yusufsidang@gmail.com](mailto:m.yusufsidang@gmail.com); ORCID: {0009-0008-9141-8782}
2. Ratna Farida Soenarto, Jl. Diponegoro No. 71, Jakarta Pusat, DKI Jakarta 10430, Indonesia; E-mail: [fida.soenarto@gmail.com](mailto:fida.soenarto@gmail.com); ORCID: {0000-0002-6728-7179}

**Correspondence:** M. Yusuf Sidang Amin; **E-mail:** [m.yusufsidang@gmail.com](mailto:m.yusufsidang@gmail.com); **Phone:** +6285255666123

## ABSTRACT

Patent ductus arteriosus (PDA) is a cardiac anomaly where the ductus arteriosus, a blood vessel connecting the pulmonary artery and the aorta, fails to close completely after birth. Anesthesia management during bedside PDA ligation in the Neonatal Intensive Care Unit (NICU) presents unique challenges and higher risks compared to the operating room environment. Manual cardiovascular and respiratory monitoring may be inefficient and challenging for the anesthesiologists. This case report aims to discuss the anesthetic management of a one month and four days old male infant, who presented with respiratory distress since birth, was diagnosed with moderate PDA, respiratory distress syndrome, and in need of surfactant therapy. This report focuses on the utilization of total intravenous anesthesia (TIVA) without inhalation anesthesia for PDA ligation via left posterolateral thoracotomy performed at the bedside in the NICU.

**Keywords:** Ligation; Patent ductus arteriosus; Preterm; Respiratory distress syndrome; Surfactant; Total intravenous anesthesia

**Citation:** Amin MYS, Soenarto RF. Addressing challenges in anesthesia management for patent ductus arteriosus ligation in a preterm baby: a case report. *Anaesth. pain intensive care* 2024;28(2):391–394; DOI: [10.35975/apic.v28i2.2412](https://doi.org/10.35975/apic.v28i2.2412)

**Received:** February 04, 2024; **Revised:** February 04, 2024; **Accepted:** February 04, 2024

## 1. INTRODUCTION

Patent ductus arteriosus (PDA) is a cardiac anomaly resulting from the incomplete closure of the ductus arteriosus, a blood vessel connecting the pulmonary artery and the aorta, after childbirth. In cases of PDA, this conduit remains open, leading to the aberrant flow of blood from the aorta to the pulmonary artery and vice versa.<sup>1</sup>

Respiratory tract infection symptoms, dyspnea, difficulty in feeding, and failure to thrive are commonly observed in PDA patients. Clinical signs may include a continuous murmur, low diastolic blood pressure, widened pulse pressure, bounding pulses, elevated serum creatinine, oliguria, and hepatomegaly.<sup>2,3,4</sup>

The management of PDA typically involves two steps: pharmacological intervention with NSAIDs and surgical ligation therapy if pharmacological treatment proves ineffective.<sup>5</sup> The surgical ligation of PDA is a procedure wherein the ductus arteriosus is tied off to cease the blood flow from the pulmonary artery to the aorta. Special attention to anesthesia management is warranted when performing bedside ligation procedures rather than in the operating room. Bedside anesthesia management may carry higher risks compared to anesthesia management in the operating room. Potential complications include an increased risk of infection, bleeding, and a higher incidence of postoperative respiratory disturbances.<sup>2,4</sup>

Strict perioperative cardiovascular and respiratory monitoring is essential in both settings. Continuous invasive monitoring can be employed in the operating room, integrated with the operating room's monitoring systems. Conversely, during bedside procedures, cardiovascular and respiratory monitoring may be partially conducted manually. This case report will review the anesthesia management during bedside PDA ligation.<sup>2,4</sup>

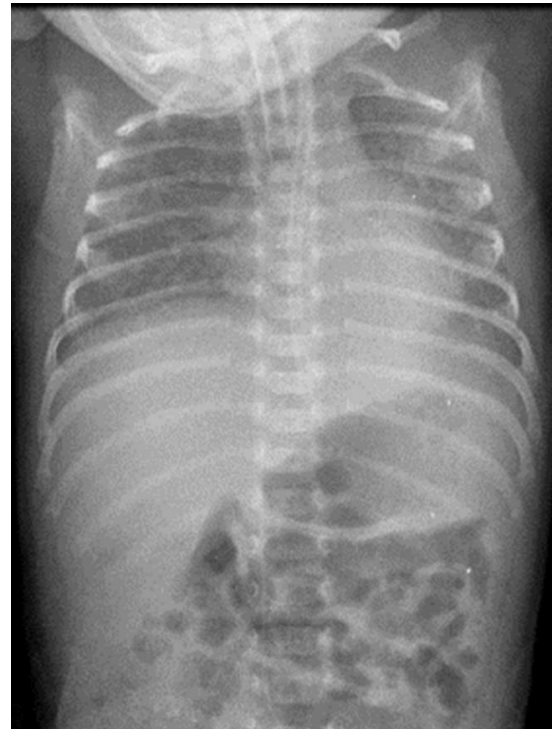
## 2. CASE REPORT

A male infant, one month and 4 days old, presented clinically with respiratory distress since birth. The maternal history indicated a 22-year-old primigravida (G1P0A0) who underwent a cesarean section at 28 weeks due to premature rupture of membranes (PROM) three days after oligohydramnios was diagnosed. The Apgar score was 5/9, with a birth weight of 1280 grams and crown to rump (CR) length of 36 cm. Antenatally, fetal lung maturation was achieved through the administration of dexamethasone (2x6 mg) for two days before pregnancy termination. The mother, known to be HIV-positive since 2020, received antiretroviral therapy (ARV) with an undetected viral load (VL) in December 2021 and a CD4 count of 621 cells/ $\mu$ L in August 2021. Additionally, she had a history of tuberculosis, which was declared resolved in 2022.

Postnatally, the infant exhibited chest retractions and nasal flaring, necessitating non-invasive positive pressure ventilation (NIPPV) and surfactant administration in the operating room. Subsequently, the patient was admitted to the Neonatal Intensive Care Unit (NICU), breathing with non-invasive ventilation (NIV) at a rate of 40 breaths per minute,  $FiO_2$  21%, peak inspiratory pressure (PIP) 16 cmH<sub>2</sub>O, and positive end-expiratory pressure (PEEP) 6 cmH<sub>2</sub>O. During treatment, the patient experienced gastrointestinal bleeding and clinical deterioration, prompting fasting and intubation. ARV prophylaxis was withheld within the first 72 h due to hemodynamic instability and gastrointestinal bleeding. While in the NICU, the patient's clinical condition improved, and there was no further gastrointestinal bleeding. The patient was subsequently transferred to the neonatal ward with oxygen supplementation through NIPPV, receiving ceftazidime 180 mg 8 hourly and tigecycline 3 mg 12 hourly.

During the pre-anesthesia assessment, the patient was found to be active with an endotracheal tube (ETT) in place, ventilated in pressure control-assist control (PC-AC) mode with an I:E ratio of 1:1.5,  $FiO_2$  30%, PEEP 5 cmH<sub>2</sub>O, respiratory rate of 60 breaths per min, oxygen saturation 99%, blood pressure 83/40 mmHg, heart rate 180 beats per min, and a temperature range of 36.2-36.4°C. Norepinephrine at 0.05  $\mu$ g/kg/min was

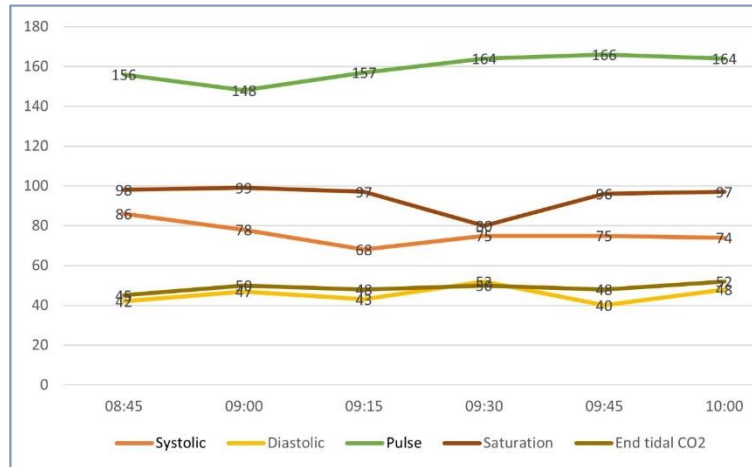
administered. Physical examination revealed hyperactive precordial pulsations, regular heart sounds, a grade 3/6 continuous murmur at the left lower sternal border, and no gallop sounds. Laboratory results were within normal limits. Chest and abdominal X-rays indicated bronchopneumonia, bronchopulmonary dysplasia (BPD), hepatomegaly, and gastric dilatation. Sputum culture revealed *Pseudomonas aeruginosa*, sensitive to ceftazidime (Figure 1).



**Figure 1. Pre-operative anteroposterior (AP) chest and abdomen X-ray: reveals bilateral lung infiltrates suggestive of pneumonia, bronchopulmonary dysplasia (BPD), hepatomegaly, and dilation with thickening of the stomach wall.**

Confirmation of PDA was made via echocardiography. Despite NSAID administration in the hope of spontaneous closure, reevaluation revealed persistent PDA. Echocardiography results indicated atrioventricular-ventriculoatrial (AV-VA) concordance, dilation of the left atrium-left ventricle (LA-LV), a 3-4 mm PDA, left-to-right (L-R) shunt, and a patent foramen ovale (PFO), leading to a diagnosis of moderate PDA with LA-LV volume overload. The patient was recommended for surgical PDA ligation alongside antibiotic therapy for pneumonia.

Bedside PDA ligation was performed in the NICU due to the patient's non-transportable condition. General anesthesia included ketamine 1 mg/kg IV, fentanyl 1  $\mu$ g/kg, and rocuronium 1 mg/kg IV for induction.



**Figure 2. Intraoperative Hemodynamic changes**

Maintenance comprised continuous morphine at 20  $\mu\text{g}/\text{kg}/\text{min}$  and intermittent fentanyl at 1  $\mu\text{g}/\text{kg}$ . Ventilation was in pressure control-assist control (PC-AC) mode with a fraction of inspired oxygen ( $\text{FiO}_2$ ) of 40%, PEEP 6  $\text{cmH}_2\text{O}$ , respiratory rate of 60 breaths per minute, and an I:E ratio of 1:1.5. A peripherally inserted central catheter (PICC) was placed in the left foot. Continuous monitoring included EKG and  $\text{SpO}_2$ , while noninvasive blood pressure (NIBP) was intermittently measured.

Preoperatively, the patient's NBP was 74/28 (43) mmHg, heart rate 182 beats per minute, ventilator-assisted respiratory rate 56 breaths per minute, and temperature 36.2°C. The operation, performed in the right lateral decubitus position through a left posterolateral thoracotomy incision, identified a 5 mm PDA. Double ligation successfully increased the diastolic pressure from 28 mmHg before the procedure to 37 mmHg after ligation (BP: 74/37 (56) mmHg), with a heart rate of 190 beats per minute, sinus rhythm (SR) without support, respiratory rate of 62 breaths per minute, and temperature of 36.4°C. Intraoperative bleeding was 5 mL, and urine output was 4 mL/kg/h. Fluid intake during the operation included packed red cells (PRC) 10 mL and crystalloid solution 40 mL.

Postoperatively, the patient continued care in the NICU under morphine sedation at 10  $\mu\text{g}/\text{kg}/\text{h}$  and intermittent fentanyl at 5  $\mu\text{g}/\text{kg}/\text{min}$ . Blood pressure remained stable with norepinephrine support at 0.1  $\mu\text{g}/\text{kg}/\text{min}$ . On the second day postoperatively (POD 1), morphine at 10  $\mu\text{g}/\text{kg}/\text{hour}$  was continued, and fentanyl was discontinued.

### 3. DISCUSSION

Patent ductus arteriosus (PDA) is a common cardiac anomaly in premature infants, with an incidence rate of

80-90% in infants with very low birth weight and gestational age less than 26 weeks. The mechanism linking acute respiratory distress to PDA is associated with the occurrence of hypoxemia and pulmonary hyperperfusion, leading to disrupted surfactant production in alveolar cells. PDA itself can result in interstitial and alveolar pulmonary edema, reducing lung compliance and necessitating higher and prolonged ventilator usage. Thus, PDA and acute respiratory distress are bidirectionally interrelated. PDA is also associated with necrotizing enterocolitis (NEC), prolonged mechanical ventilation, bronchopulmonary dysplasia (BPD), intraventricular hemorrhage, and developmental disturbances.<sup>2</sup>

In this case, several risk factors align with previous studies, including the patient being a very premature infant with a gestational age of 28 weeks, low birth weight of 1880 grams, low Apgar score (5/9), and the presence of respiratory distress syndrome (RDS) at birth. The patient received surfactant therapy at birth and experienced gastrointestinal bleeding within 72 hours after delivery. Consistent with studies by Clyman et al., this case also revealed BPD on chest X-ray examination.

When administering anesthesia to premature neonates, surgical procedures may not always be feasible in the operating room. Sometimes, the critical or non-transportable condition of the patient may necessitate bedside surgery in the NICU. Common bedside procedures requiring anesthesia supervision include exploratory laparotomy and PDA ligation. These patients often require unconventional ventilation or more precise ventilation than standard anesthesia machines provide. Although suboptimal due to NICU's differing infection control and air exchange standards compared to the operating room, bedside procedures may be the best option to avoid transporting critically ill or unstable patients.<sup>4,6</sup>

Patient transportation poses risks such as hypothermia, infusion disruptions, loss of vascular access, unintended extubation, and ventilation disturbances, potentially leading to higher mortality. A study by Lisa et al. comparing postoperative outcomes of PDA ligation in 189 patients in the operating room versus the NICU found that NICU ligation was not associated with a higher incidence of infection and mortality ( $p > 0.05$ ). However, there was a significantly higher incidence of hemodynamic instability, 9.67 times more likely during transportation back to the NICU for patients operated in the operating room (OR=9.67, 95% CI: 1.95-47.89).<sup>6</sup> In this case, PDA ligation was performed at the NICU due

to the patient's severe and unstable general condition, making transport to the operating room impractical.

Preoperative management for bedside PDA ligation in the NICU includes preoperative echocardiography, adjustment of ventilator settings, FiO<sub>2</sub>, infusion, and vascular access before anesthesia administration. Most patients receive intravenous access before surgery, and some are intubated (depending on the patient's condition and shunt size). High-dose fentanyl has been used since 1981 as the preferred anesthesia for neonates due to its stable hemodynamic effects and adequate analgesic properties. To date, fentanyl and paralytic agents remain the preferred anesthesia for ductal ligation and other neonatal surgeries.<sup>6</sup>

Anesthesia for PDA ligation via thoracotomy generally requires two intravenous lines, pre- and post-ductal pulse oximetry, and non-invasive blood pressure (NIBP) measurements every 3 minutes. Monitoring cerebral oximetry and lower extremity blood pressure cuffs are also valuable. The size of the PDA may be as large as or larger than the aorta or pulmonary artery, often necessitating a clamp test to secure and ensure the correct vessel (ductus arteriosus). Any drop in saturation or distal perfusion should be promptly reported to the surgeon during the clamp test. After successful ductal ligation, an increase in diastolic blood pressure should be observed.<sup>4,6</sup> In this case, there was an increase in diastolic blood pressure from 28 mmHg to 37 mmHg and a decrease in oxygen saturation from 94% to 89% post-ligation.

Challenges encountered in anesthesia management for this patient during bedside NICU care included a limited workspace shared with the surgical team, restricted anesthesia equipment, meticulous monitoring of hemodynamics, particularly respiratory status without anesthesia machines, blood pressure control due to frequent changes in circulation, prevention of hypothermia, and maintaining optimal sterile conditions during bedside NICU procedures.

In a study by Lisa et al., like this case, the use of high-frequency oscillatory ventilation (HFOV)/high-frequency jet ventilation (HFJV) was more prevalent in the NICU group compared to the operating room group (49% vs. 1.1%,  $P < 0.001$ ). In another study by Lisa et al., the NICU group, received fentanyl infusion or bolus, and intermediate-acting paralytics such as rocuronium were administered.<sup>6</sup> In a study by Joshi et al., preoperative preparation involved the placement of peripheral intravenous access at two sites for parenteral

nutrition and/or fluid maintenance therapy, induction with opioid agents (fentanyl 2 µg/kg, titrated to a maximum of 5 µg/kg), and muscle relaxation (pancuronium 0.1 mg/kg titrated).<sup>4</sup>

## 4. CONCLUSION

The anesthesia management utilizing TIVA without inhalation anesthesia proves to be safe and effective in the context of PDA ligation procedures in the NICU. Numerous studies have explored bedside PDA ligation in the NICU, demonstrating its safety and efficacy, while also emphasizing the importance of perioperative anesthesia management.

## 5. Conflict of interest

Nil declared by the authors.

## 6. Authors contribution

MYS: Concept, administrative support, provision of study materials, collection of data, manuscript writing

RF: Concept, manuscript editing, final approval of manuscript

## 7. References

- Gillam-Krakauer M, Mahajan K. Patent Ductus Arteriosus. 2022 Aug 8. In: StatPearls. Treasure Island (FL): StatPearls Publishing; 2023 Jan-. PMID: [28613509](#). Bookshelf ID: [NBK430758](#)
- Kritzmire SM, Boyer TJ, Singh P. Anesthesia for Patients With Patent Ductus Arteriosus. 2022 Aug 9. In: StatPearls [Internet]. Treasure Island (FL): StatPearls Publishing; 2024 Jan-. PMID: [34283429](#).
- Al-Nemri AMH. Patent ductus arteriosus in preterm infant : Basic pathology and when to treat. Sudan J Paediatr. 2014;14(1):25–30. PMID: [27493386](#), PMCID: [PMC4949912](#)
- Joshi RK, Aggarwal N, Agarwal M, Joshi R. Anesthesia protocols for "bedside" preterm patent ductus arteriosus ligation: A single-institutional experience. Ann Pediatr Cardiol. 2021 Jul-Sep;14(3):343-349. PMID: [34667406](#), PMCID: [PMC8457282](#), DOI: [10.4103/apc.apc\\_41\\_21](#)
- de Klerk JCA, Engbers AGJ, van Beek F, Flint RB, Reiss IKM, Völler S, Simons SHP. Spontaneous Closure of the Ductus Arteriosus in Preterm Infants: A Systematic Review. Front Pediatr. 2020 Sep 11;8:541. PMID: [33014935](#), PMCID: [PMC7516116](#), DOI: [10.3389/fped.2020.00541](#)
- Lee CS, Shinn HK, Lim HK, Song JH, Jung JK, Han JU, et al. Anesthetic Management of Early Ligation of Patent Ductus Arteriosus for Premature Infants in the Neonatal Intensive Care Unit. Korean J Anesthesiol. 2008;54(1):53-57. DOI: <https://doi.org/10.4097/kjae.2008.54.1.53>