

## ORIGINAL RESEARCH

## INTRAVASCULAR TECHNIQUES

# Experience of permacath placement in patients with end stage renal failure in a tertiary hospital

Liaquat Ali<sup>1</sup>, Tehniat Ali<sup>2</sup>, Syed Ihlal Mustafa<sup>3</sup>, Ali Ahmed Qureshi<sup>4</sup>

**Author affiliation:**

1. Liaquat Ali, FCPS, MSc (Pain Medicine), Professor & Head, Dept of Anesthesia, Intensive Care & Pain Medicine, Fauji Foundation Hospital / Foundation University, Rawalpindi, Pakistan; E-mail: [liaquatanaes@gmail.com](mailto:liaquatanaes@gmail.com)
2. Tehniat Ali, FCPS, Senior Registrar Anaesthesia, Fauji Foundation Hospital / Foundation University, Rawalpindi, Pakistan; E-mail: [tehniat\\_ali\\_zaman@hotmail.com](mailto:tehniat_ali_zaman@hotmail.com)
3. Syed Ihlal Mustafa, MBBS Student, Internee at Anesthesia Department, Fauji Foundation Hospital Rawalpindi, Pakistan; E-mail: [ihlalmustafa@gmail.com](mailto:ihlalmustafa@gmail.com)
4. Ali Ahmed Qureshi, MBBS, Resident Anesthesia, Fauji Foundation Hospital Rawalpindi, Pakistan; E-mail: [aliahmed.moq@gmail.com](mailto:aliahmed.moq@gmail.com)

**Correspondence:** Prof. Maj Gen (Retd) Liaquat Ali, **Mobile:** +92 321 5836898, **E-mail:** [liaquatanaes@gmail.com](mailto:liaquatanaes@gmail.com)

## ABSTRACT

**Background & objective:** Renal failure patients often need hemodialysis to optimize the deranged fluid and electrolyte balance in their blood. It involves drawing patients' venous blood, route it through the hemodialysis (HD) machine and pump it back into the blood circulation. Frequent HD is conveniently performed through large bore, double lumen catheters and to prevent infection it is tunneled for a few centimeters. We conducted this retrograde study to determine the frequency of complications of tunneled permacath insertions in patients with end stage renal disease (ESRD) undergoing hemodialysis in our tertiary hospital

**Methodology:** This retrograde descriptive study was conducted at Department of Anesthesiology, Fauji Foundation Hospital, Rawalpindi. from 1st Jan, 2019 – 1st Jan 2023. We searched and included data from the patient records of 804 patients in whom permacath was inserted for hemodialysis under ultrasound guidance and follow-up was done for 8 weeks. Data was retrieved and stored on a Performa and was analyzed on SPSS version 16.

**Results:** Out of 812 permanent catheters passed in 804 patients, 19% had complications. The most common complication was catheter thrombosis (8%), followed by local site bleeding (5%), infection (3%), arterial prick (2%) and hematoma formation (1%).

**Conclusion:** Tunneled permacath central venous catheter can be used in patients undergoing hemodialysis until maturation of arteriovenous fistula. It is quite a safe procedure under ultrasound guidance, but strict vigilance is required to prevent short-term and long-term complications.

**Key words:** Central Venous Catheters; Renal Dialysis; Thrombosis; Hematoma; Kidney Failure, Chronic; Fluoroscopy; Ultrasonography.

**Citation:** Ali L, Ali T, Mustafa SI, Qureshi AA. Experience of permacath placement in patients with end stage renal failure in a tertiary hospital. *Anaesth. pain intensive care* 2022;27(2):726–730; DOI: [10.35975/apic.v27i2.2357](https://doi.org/10.35975/apic.v27i2.2357)

**Received:** June 24, 2023; **Revised:** September 26, 2023; **Accepted:** November 15, 2023

## 1. INTRODUCTION

A considerable number of people in our community are suffering from end stage renal disease (ESRD).<sup>1</sup> Despite the fact that renal transplant is the primary choice of treatment in patients with ESRD, non-availability of organ donors and suppression of immune system remain

a constant problem.<sup>2</sup> Therefore dialysis is required to reduce mortality, which primarily includes hemodialysis.<sup>2</sup> Vascular access is of prime importance in patients with ESRD undergoing hemodialysis. There are three different ways of vascular access, Autogenous Arteriovenous fistula (AVF) being the primary access, but requires a time of 4-6 weeks to mature.<sup>3</sup> Prosthetic Arteriovenous Grafts (AVG), although not preferred as

primary vascular access due to graft thrombosis, can be cannulated within 2-3 weeks. However, AVF and AVG are not indicated in patients with severe heart failure, chronic respiratory failure and respiratory steal syndrome.

Tunneled and non-tunneled double lumen central venous catheters (CVC) are used in patients requiring immediate vascular access for hemodialysis or those having contraindications to AVF.<sup>4,5</sup> Tunneled catheters have lower rate of complications (e.g. malfunction, thrombosis and infection) as compared to non-tunneled catheters, hence they are more useful, especially when required for more than one month.

Right internal jugular vein is the preferred site due to its ease of cannulation and reduced risk of complications,<sup>6,7</sup> followed by left internal jugular vein, femoral vein and subclavian vein. Use of real-time Ultrasonography increases the success rate of venous puncture and reduces risk of arterial puncture.<sup>8-10</sup> Furthermore, with fluoroscopic guidance location of catheter tip can be confirmed.<sup>11</sup>

There is limited data available on placement of permacath insertions in our country. We aimed to document the success rate, immediate and delayed complications of ultrasound and fluoroscopy-guided tunneled catheters in our tertiary hospital.

## 2. METHODOLOGY

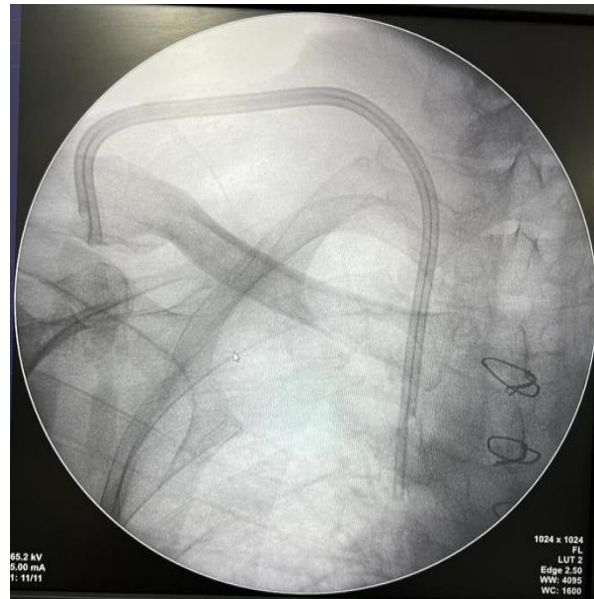
After approval from the hospital ethical committee, a retrospective descriptive study was conducted at Fauji Foundation Hospital, Rawalpindi from January 01, 2019 to January 01, 2023. A total of 812 permacaths were placed in 804 patients with ESRD, requiring hemodialysis. Patients with coagulopathy (INR > 1.5) and thrombocytopenia (platelet count < 50,000/ $\mu$ L) were excluded from the study.

All catheters were inserted by trained senior postgraduate trainee anesthesiology under supervision of consultant anesthesiologist, in operating room, using sterile techniques. A standard technique was adopted for every patient. Coagulation profile were checked before the procedure, including the prothrombin time, partial thromboplastin time. INR and platelet count. After applying standard monitoring i.e., pulse oximeter, non-invasive blood pressure, 3 lead ECG, patients were placed in supine position, exposed, scrubbed and draped. I/V midazolam 0.02 mg/kg was be given for intraoperative sedation, with inj. ceftriaxone 1gm I/V as antibiotic prophylaxis.

Real time ultrasonography was used in all cases to verify the patency of the central veins, to mark an appropriate puncture site, introduce needle in to central vein and to

advance J wire up to junction of SVC and right atrium. Tunnel was made and the catheter was passed through the tunnel. Venotomy site was dilated, peel away sheath was placed and catheter was passed through peel away sheath. Adequate flow was assessed through both ports and catheter hubs

were flushed with inj. TauroLock™. Fluoroscope imaging was used to confirm the correct location of catheter tip in all cases. (Figure 1).



**Figure 1: Confirmation of position of catheter via fluoroscopy**

All patients were observed for one hour in recovery room for any early complications. Follow-up was done after four and eight weeks to analyze early and late complications.

### Data analysis

After collection, all data was entered and analyzed using SPSS Version 16. Mean and SD were calculated for quantitative variables i.e., age, mean arterial pressure, and dose of midazolam. Frequency and percentages were calculated for qualitative variables i.e., gender, presence of vomiting, nausea and respiratory complications.

## 3. RESULTS

Data of all patients undergone permacath insertion during the study period was retrieved from the patient records. Out of a total of 804 patients, there were 635 (79%) females and 169 (21%) males establishing a female predominance. The mean age of the patients was  $45 \pm 12.74$  y (Table 1).

**Table 1: Demographic and laboratory data of the patients (n = 804)**

| Parameters                 |                  | N (%)      |
|----------------------------|------------------|------------|
| Sex                        | Male             | 169 (21)   |
|                            | Female           | 635 (79)   |
| Age (y)                    | Mean age         | 45 ± 12.74 |
|                            | Above 45         | 458 (57)   |
|                            | Below 45         | 346 (43)   |
| Reason for Catheterization | Hemodialysis     | 804 (100)  |
| Laboratory investigations  |                  |            |
| PT (sec)                   | Normal (10.8)    | 458 (57)   |
|                            | 10.9-11.5        | 141 (18)   |
|                            | 11.6-13          | 153 (19)   |
|                            | >13              | 52 (6)     |
| APTT (sec)                 | Normal (27.1)    | 497 (62)   |
|                            | 27.2-30          | 115 (14)   |
|                            | 31-35            | 1039 (13)  |
|                            | 35               | 89 (11)    |
| INR                        | Normal (1)       | 458 (57)   |
|                            | 1.1-1.2          | 294 (37)   |
|                            | 1.3-1.5          | 52 (6)     |
|                            | >1.5             | 0 (0)      |
| Serum Potassium (mEq/L)    | Normal (3.3-5)   | 483 (60)   |
|                            | 5.1-5.5          | 306 (38)   |
|                            | 5.6-5.7          | 15 (2)     |
|                            | >5.7             | 0 (0)      |
| Creatinine (µmol/L)        | Normal (60-120)  | 13 (2)     |
|                            | 121-200          | 8 (1)      |
|                            | 201-300          | 92 (11)    |
|                            | >300             | 690 (86)   |
| S. Urea (mmol/L)           | Normal (3.3-8.3) | 26 (3)     |
|                            | 8.4-12           | 154 (19)   |
|                            | 12.1-150         | 154 (19)   |
|                            | >15              | 471 (59)   |

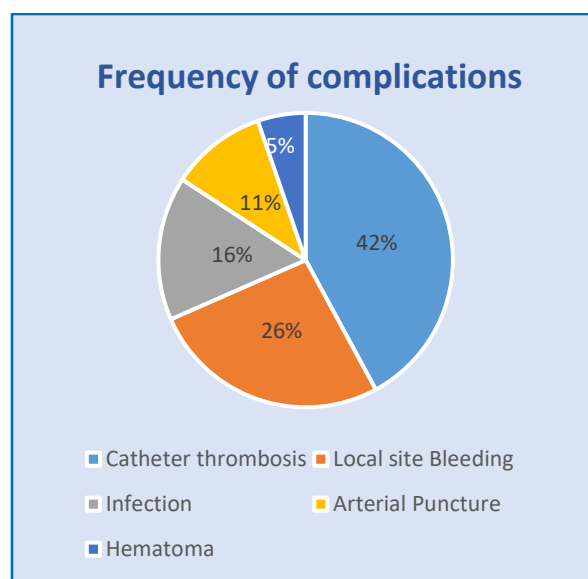
In 90% of the cases, venous access was established in first attempt. In the remaining 10% the venous access was made in second attempt within the same session.

**Figure 2: Complications associated with permacath insertion**

| Complications       | Number of patients |
|---------------------|--------------------|
| Catheter thrombosis | 64 (8%)            |
| Local site Bleeding | 40 (5%)            |
| Infection           | 24 (3%)            |
| Arterial Puncture   | 16 (2%)            |
| Hematoma            | 8 (1%)             |

The right internal jugular vein was accessed in 78% while 20% catheters were placed through the left internal jugular vein and the remaining 2% were placed in right femoral vein. Sites other than right IJV were chosen in cases which had contraindications to placement in right IJV, such as, thrombosed right IJV (5%), right sided AVF (12%), infection at the right side of neck (3%) and arterial puncture in attempt to catheterize right IJV (2%). There were no immediate complications like vomiting, nausea, respiratory complications.

The percentage of complications is depicted as Figure 1. It shows that arterial thrombosis was the most common (42%) and the hematoma formation was the least common (5%) complication of the total of 152 (19%) patients who developed complications.

**Figure 1: Frequency of complications associated with permacath insertion**

All the patients were followed-up after 4 and 8 weeks. Out of 804 procedures, 152 (19%) had complications. In 16 (2%) patients, there was accidental common carotid artery puncture. The needle was removed immediately in these cases and catheter was placed at an alternate site. However, in 8 (1%) cases a small hematoma developed, compression was applied, and the hematoma resolved on the follow-up scan (Table 2).

In 40 (5%) patients local site bleeding was seen, that resolved within 10 min of manual compression.

Thrombosis in the catheter was noted in 64 (8%) patients, presented with Inability to perform hemodialysis within one month of placement of the catheter. In all these patients, we used heparinized saline to open the catheter; the trial was successful in 3% patients while in 5% patients, the patency of the catheter

could not be established, so they had to be replaced by catheterization at left IJV. Twenty-four patients presented with pain, fever, redness, and pus discharge at the site of catheter insertion within 4 weeks. Antibiotics were given to all patients and catheters were removed to be re-inserted in left IJV later on.

## 4. DISCUSSION

Although arteriovenous fistula is the primary mode of vascular access for hemodialysis, but for immediate access tunneled and non-tunneled venous catheters are used.<sup>12</sup> Non-tunneled venous catheters were most commonly used in our set up due to easy availability, low cost and lack of expertise. However these non-tunneled catheters are associated with high risk of infection and increased chances of dislodgement.<sup>13</sup> Therefore we started placing tunneled venous catheter in our operating rooms, using strict aseptic measures.

The success rate of catheter insertion in our study was 100%, which was comparable to other studies which used real time ultrasonography,<sup>14</sup> 90% of the venous access was established at first attempt, while the remaining 10% was done at second attempt within the same session. The rate of arterial puncture in our study came out to be 2%, as compared to 7% reported by Zeki Ayedin et al.<sup>15</sup>

Several studies have shown that late complications, particularly infection and thrombosis, remain problematic and can lead to catheter dysfunction and significant morbidity.<sup>16,17</sup>

In our study most common complication seen was catheter thrombosis (8%) leading to removal and re-insertion of catheter at the alternative sites. Local site bleeding was seen in 5% of cases that settled with manual compression, none of the patients required any further management. This was comparable to the results shown in a study carried out at SQUH showing mild hemorrhage in 5.4% of procedures.<sup>18</sup>

Our infection rate came out to be 3% which was much lower as compared to a study carried out by Hyder et al. who reported an infection rate of 13%.<sup>1</sup> Our low rate could be attributable to better aseptic conditions available in the OR.

During the first six months of our study a total of 60 tunneled catheters were placed. Among the reasons of catheter failure, catheter thrombosis was the commonest (8%), followed by infection (2%).

## 5. CONCLUSION

Tunneled permanent central venous catheter (permacath) can be safely inserted under ultrasound guidance in patients undergoing multiple sessions of hemodialysis

due to end stage renal failure until arteriovenous fistula is made and gets mature.

## 6. Data availability

The numerical data generated during this research is available with the authors.

## 7. Acknowledgement

We gratefully thank staff of Department of Anesthesiology, Intensive Care & Pain Management, for their help in retrieval of patient record files and recording the required data.

## 8. Conflict of interest

There was no conflict of interest by the authors. We did not receive any financial support.

## 9. Authors' contribution

LA: Concept, conduct of the study

TA: Conduct of study work and procedure

SIM: Data collection, conduct of study work

AAQ: Manuscript editing and follow up

## 10. REFERENCES

- Hyder SMS, Iqbal J, Lutfi IA, Shazlee MK, Hamid K, Rashid S. Complications Associated with Permanent Internal Jugular Hemodialysis Catheter: A Retrospective Study. *Cureus*. 2019 Apr 22;11(4):e4521. [PubMed] DOI: [10.7759/cureus.4521](https://doi.org/10.7759/cureus.4521)
- Lee HJ, Son YJ. Prevalence and Associated Factors of Frailty and Mortality in Patients with End-Stage Renal Disease Undergoing Hemodialysis: A Systematic Review and Meta-Analysis. *Int J Environ Res Public Health*. 2021 Mar 27;18(7):3471. [PubMed] DOI: [10.3390/ijerph18073471](https://doi.org/10.3390/ijerph18073471)
- Tordoir J, Canaud B, Haage P, Konner K, Basci A, Fouque D, et al. EBPG on Vascular Access. *Nephrol Dial Transplant*. 2007 May 1;22(suppl\_2):ii88–117. [PubMed] DOI: [10.1093/ndt/gfm021](https://doi.org/10.1093/ndt/gfm021)
- Dinh LD, Nguyen DH. Vascular access for hemodialysis: Current practice in Vietnam. *J Vasc Access*. 2019 May 1;20(1\_suppl):20–3. [PubMed] DOI: [10.1177/1129729818771883](https://doi.org/10.1177/1129729818771883)
- Allon M. Quantification of Complications of Tunneled Hemodialysis Catheters. *Am J Kidney Dis*. 2019 Apr;73(4):462–464. [PubMed] DOI: [10.1053/j.ajkd.2018.12.032](https://doi.org/10.1053/j.ajkd.2018.12.032)
- Lussier BL, Pham DT, Ratti GA, Patel J, Mitchell BC, Chen C. Catheterization Without Supination—A Series of 36 Prone Position Internal Jugular Vein Cannulations. *Crit Care Explor*. 2022 Dec 30;5(1):e0831. [PubMed] DOI: [10.1097/CCE.0000000000000831](https://doi.org/10.1097/CCE.0000000000000831)
- Vafek V, Skříšovská T, Kosinová M, Klabusayová E, Musilová T, Kramplová T, et al. Central Venous Catheter Cannulation in Pediatric Anesthesia and Intensive Care: A Prospective Observational Trial. *Children*. 2022 Nov;9(11):1611. [PubMed] DOI: [10.3390/children9111611](https://doi.org/10.3390/children9111611)

8. Anagnostopoulos D, Saranteas T, Papadimos T, Kostroglou A, Kouki P. Ultrasound-Guided Internal Jugular Catheter Insertion in Prone Position. *J Cardiothorac Vasc Anesth*. 2020 May 1;34(5):1388–90. [PubMed] DOI: [10.1053/j.jvca.2019.10.008](https://doi.org/10.1053/j.jvca.2019.10.008)
9. Patel AR, Patel AR, Singh S, Singh S, Khawaja I. Central Line Catheters and Associated Complications: A Review. *Cureus*. 2019 May 22;11(5):e4717. [PubMed] DOI: [10.7759/cureus.4717](https://doi.org/10.7759/cureus.4717)
10. Kächele M, Bettac L, Hofmann C, Herrmann H, Brandt A, Schröppel B, et al. Feasibility Analysis of Ultrasound-Guided Placement of Tunneled Hemodialysis Catheters. *Kidney Int Rep*. 2023 Aug 11;8(10):2001-2007. [PubMed] DOI: [10.1016/j.ekir.2023.07.038](https://doi.org/10.1016/j.ekir.2023.07.038)
11. Kartsouni V, Moschouris H, Bersimis F, Gkeneralis G, Gkeli M, Dodoura S, et al. Complications of Totally Implantable Central Venous Catheters (Ports) Inserted via the Internal Jugular Vein Under Ultrasound and Fluoroscopy Guidance in Adult Oncology Patients: A Single-Center Experience. *Cureus*. 2022 Jul 30;14(7):e27485 [PubMed] DOI: [10.7759/cureus.27485](https://doi.org/10.7759/cureus.27485)
12. Faponle AE, Olatise OO, Igbokwe M, Asaolu SO. Outcomes of Tunneled and Non-tunneled Internal Jugular Catheters for Hemodialysis at Zenith Medical and Kidney Centre, Nigeria. *Niger J Med*. 2020 Oct 8;29(3):455–9. [FreeFullText]
13. Chouhani BA, Kabbali N, Chiba Bennani S, El Bardai G, Sqalli Houssaini T. Tunneled catheters in hemodialysis: Indications and complications. *J Médecine Vasc*. 2022 Apr 1;47(2):87–93. [PubMed] DOI: [10.1016/j.jdmv.2022.04.007](https://doi.org/10.1016/j.jdmv.2022.04.007)
14. Chew SC, Beh ZY, Hakumat Rai VR, Jamaluddin MF, Ng CC, Chinna K, et al. Ultrasound-guided central venous vascular access—novel needle navigation technology compared with conventional method: A randomized study. *J Vasc Access*. 2020 Jan 1;21(1):26–32. [PubMed] DOI: [10.1177/1129729819852057](https://doi.org/10.1177/1129729819852057)
15. Aydin Z, Gursu M, Uzun S, Karadag S, Tatli E, Sumnu A, et al. Placement of Hemodialysis Catheters with a Technical, Functional, and Anatomical Viewpoint. *Int J Nephrol*. 2012 Aug 26;2012:e302826. [PubMed] DOI: [10.1155/2012/302826](https://doi.org/10.1155/2012/302826)
16. Wang L, Jia L, Jiang A. Pathology of catheter-related complications: what we need to know and what should be discovered. *J Int Med Res*. 2022 Oct 1;50(10):03000605221127890. [PubMed] DOI: [10.1177/03000605221127890](https://doi.org/10.1177/03000605221127890)
17. Miller LM, MacRae JM, Kiaii M, Clark E, Dipchand C, Kappel J, et al. Hemodialysis Tunneled Catheter Noninfectious Complications. *Can J Kidney Health Dis*. 2016 Jan 1;3:2054358116669130. [PubMed] DOI: [10.1177/2054358116669130](https://doi.org/10.1177/2054358116669130)
18. Hamid RS, Kakaria AK, Khan SA, Mohammed S, Al-Sukaiti R, Al-Riyami D, et al. Safety and Complications of Double-Lumen Tunnelled Cuffed Central Venous Dialysis Catheters: Clinical and radiological perspective from a tertiary centre in Oman. *Sultan Qaboos Univ Med J*. 2015 Nov;15(4):e501-6. [PubMed] DOI: [10.18295/squmj.2015.15.04.010](https://doi.org/10.18295/squmj.2015.15.04.010)
19. Flick AI, Winters R. Vascular Tunneled Central Catheter Access. 2023 Jul 4. In: *StatPearls* [Internet]. Treasure Island (FL): StatPearls Publishing; 2023. [PubMed]