

ORIGINAL RESEARCH

REGIONAL ANESTHESIA

Bilateral ultrasound guided erector spinae plane block vs. preoperative pregabalin for postoperative pain management in lumbar spine surgery

Rabab Mohamed Mohamed¹, Islam Morsy², Jehan Mohammad Darwish Hamed³

Authors' Affiliation:

1. Rabab Mohamed Mohamed, MD, Assistant Professor of Anesthesiology, Surgical Intensive Care & Pain Medicine, Faculty of Medicine, Tanta University, Tanta, Egypt; Email: rabmoh_30@outlook.com
2. Islam Morsy, MD, Lecturer of Anesthesiology, Surgical Intensive Care & Pain Medicine, Faculty of Medicine, Tanta University, Egypt; Email: eslam.morsy@med.tanta.edu.eg
3. Jehan Mohammad Darwish Hamed, MD, Assistant Professor of Anesthesiology, Surgical Intensive Care & Pain Medicine, Faculty of Medicine, Tanta University, Tanta, Egypt; Email: jehan.darwish@yahoo.com

Correspondence: Rabab Mohamed Mohamed, MD, Email: rabmoh_30@outlook.com; Telephone: +201069122935

ABSTRACT

Background & Objective: Injecting local anesthetics into the erector spinae plane and obstructing the dorsal and ventral rami could reduce the pain. Pregabalin and gabapentin are used to reduce neuropathic pain; however, pregabalin has demonstrated greater analgesic potency than gabapentin. This work aimed to compare the analgesic effects and complications between preoperative pregabalin and erector spinae plane block (ESPB) for lumbar spine surgery under general anesthesia.

Methodology: Sixty patients were allocated to the 2 groups using a computer-generated random number that was hidden in sealed, opaque envelopes. In Group 1, the patients received pregabalin 150 mg twice daily for 3 days before surgery. After preoxygenation and before induction of anesthesia, dexmedetomidine 1 µg/kg was given in both of the groups. In Group 2, after the patient was placed in the prone position for the operation and after the induction of general anesthesia, ESPB was carried out bilaterally under ultrasound guidance. Ropivacaine hydrochloride was administered at a quantity of 20 mL upon confirmation of the needle's proper insertion. Numerical Rating Scale (NRS) was used to assess the pain intensity.

Results: There was a longer-lasting analgesia in the ESPB group with significantly lower NRS only at 12 h and 18 h ($P = 0.001$) compared to the pregabalin group, but they were comparable at 24 h ($P = 0.407$). The time to request first rescue analgesic and the total morphine consumption were significantly different; a significantly longer time for the first rescue analgesic (17.10 vs. 11.73 h) and a significantly reduced amount of morphine consumption (6.30 vs. 10.33 mg) in ESPB group.

Conclusion: Both bilateral erector spinae plane block and preoperative pregabalin seem to be helpful for providing adequate pain management postoperatively for lumbar spine surgery; however, bilateral erector spinae plane block was superior in pain management during the first 24 h postoperatively with fewer side effects.

Abbreviations: ESPB - Erector Spinae Plane Block; α 2-AR - Alpha 2 Adrenoreceptors; NRS - Numerical Rating Scale; ACE - Angiotensin Converting Enzyme; NaCl - Normal Saline; MAP - Mean Arterial Blood Pressure; IV - Intravenous; PACU - Post-Anesthesia Care Unit; χ^2 - Chi-square; IQR - Interquartile Range; MAC - Minimum Alveolar Concentration;

Preregistration: The study had approval from the Ethical Committee and Institutional Review Board of the Faculty of Medicine, Tanta University with approval code (35692/9/22).

Key words: US-ESPB; Ultrasound Guided; Erector Spinae Plane Block; Pregabalin; Lumbar Spine Surgery

Citation: Mohamed RM, Morsy I, Hamed JMD. Bilateral ultrasound guided erector spinae plane block vs. pregabalin for postoperative pain management in lumbar spine surgery. *Anaesth. pain intensive care* 2023;27(5):513–520; DOI: [10.35975/apic.v27i5.2306](https://doi.org/10.35975/apic.v27i5.2306)

Received: April 07, 2023; Reviewed & Accepted: July 01, 2023

1. INTRODUCTION

One of the more prevalent orthopedic procedures is spinal surgery. The various surgical techniques applied have the potential to mutilate many tissue types.¹ Inadequate postoperative pain management in spinal cord patients hinders physical recovery after surgery, aggravates postoperative thrombotic complications risk, and might lead to chronic pain. It also decreases the patient's satisfaction and raises financial burdens at both social and personal levels.² As a result, proper pain management in patients who undergo spinal surgery is a gratifying but complex and challenging mission.

Regional anesthesia can be applied with the erector spinae plane block (ESPB). Injecting local anesthetics underneath the erector spinae muscle and obstructing the dorsal and ventral rami could reduce the pain.³

Pregabalin and its developmental form, gabapentin, are constitutional analogs of gamma-aminobutyric acid (GABA), which works as an inhibitory neurotransmitter; however, they are unrelated to it functionally.⁴ Pregabalin has demonstrated greater analgesic potency than gabapentin in rodent models with chronic neuropathic pain.⁵

Dexmedetomidine is a selective alpha-2 adrenoreceptor (α_2 -AR) agonist that has just been introduced into anesthetic practice. It provides an anxiolytic effect, dose-dependent sedation and analgesia (in supraspinal and spinal areas) without causing respiratory depression.^{6,7} Dexmedetomidine enhances anesthesia induced by other anesthetic agents, produces a perioperative sympatholytic effect, and reduces blood pressure by activating imidazoline and central alpha 2 receptors.^{8,9}

We compared analgesic effects and complications between pregabalin given three days preoperative and a peripheral nerve block, in the form of ESPB, as two different methods of multimodal analgesia in lumbar spine surgery.

2. METHODOLOGY

This study was carried out in Tanta University Hospitals from June to December 2022 on 60 adult patients of both sexes aged 21-60 y, ASA physical status I-III, scheduled for elective lumbar spine surgery, including laminectomy and spinal fixation. Exclusion criteria were patient's refusal, history of sensitivity to local anesthetics or pregabalin medications, and patients with coagulation disorders.

After patients signed written consent and institutional ethical committee approval with approval (code

35692/9/22), the selected patients were divided into two groups of 30 patients in each group, using computer-generated random numbers hidden in sealed, opaque envelopes. Preoperative pregabalin was administered in that group by a blinded physician who was not a participant in the trial. One anesthesiologist performed the ESPB and general anesthesia, and another one, who was not informed about group assignments, collected the data. All operations were done by the same team.

All enrolled patients received proper pre-anesthetic visits according to their history and physical and laboratory examinations. Diabetic and hypertensive patients were maintained on their medications. Patients under oral hypoglycemic or angiotensin converting enzyme (ACE) inhibitor and were assigned to the pregabalin group were sent to adjust their doses in the internal medicine clinic. Patients with pulmonary diseases were maintained on their medical treatments, and all patients continued their regimen postoperatively.

The use of Numerical Rating Scale (NRS), which is used to assess pain severity (0 = no pain, 10 = suffering from pain), was taught to patients.

A peripheral intravenous (IV) cannula of 20 G was inserted. The following parameters were continuously observed and recorded: electrocardiogram (ECG), peripheral oxygen saturation, noninvasive mean arterial blood pressure (MAP), and body temperature. After preoxygenation, 1 μg / kg dexmedetomidine was given before induction of anesthesia, then fentanyl 1 -2 $\mu\text{g}/\text{kg}$ was administered for analgesia, propofol in a dose of 2 mg/ kg for anesthesia and atracurium 0.5 mg/ kg was given to ease endotracheal intubation. The patients were mechanically ventilated, and anesthesia was sustained by using 1.24% end-tidal sevoflurane and 50% oxygen in the air, in a semi-closed circuit maintaining 32-35 mmHg end-tidal CO₂. Patients were placed in prone positioning, and an infusion of 0.2 μg kg/h of dexmedetomidine was started to be ceased 30 min before the end of surgery.

Group 1 patients received pregabalin 150 mg twice daily for 3 days before surgery. In Group 2 after the induction of anesthesia, the patients were placed in the prone position for the operation and ESPB was carried out. The erector spinae muscles were identified in connection to the transverse processes of T12 using ultrasound (Philips Sparq, Amsterdam, the Netherlands) and a high-frequency curved array probe. The probe was positioned in a longitudinal alignment 2-3 cm laterally to the spinal column. The integration of a 10-cm, 21-gauge ultrasonography needle (Pajunk SonoPlex STIM, Geisingen, Germany) was done cephalad to caudal. The needle was gently removed after establishing a bone connection with the transverse process. To locate and

Table 1: Enrollment data of patients in both groups:

Variables	Group 1	Group 2	Test	P value
Age (y)	45.27 ± 8.95	43.43 ± 10.43	0.731	0.468
Sex	Male	10 (33.3)	X ² : 0.287	0.592
	Female	18 (60)		
BMI (kg/m ²)	28.98 ± 2.04	29.50 ± 2.13	0.972	0.335
ASA physical status	• I	7 (23.3)	X ² : 0.667	0.716
	• II	16 (53.3)		
	• III	7 (23.3)		
Type-2 diabetes mellitus	3 (10)	4 (13.3)	X ² : 0.162	0.688
FBG (mg/dL)	141.77 ± 7.76	145.57 ± 7.86	1.884	0.065
PP-BG (mg/dL)	221.80 ± 13.37	218.50 ± 14.06	0.932	0.355
Hypertension	6 (20)	7 (23.3)	X ² : 0.098	0.754
SAP (mmHg)	136.87 ± 13.12	140.20 ± 12.24	1.018	0.313
DAP (mmHg)	90.93 ± 10.58	92.50 ± 9.35	0.608	0.546
Chronic lung disease	3 (10)	2 (6.7)	X ² : 0.218	0.640
NSAID use	12 (40)	11 (36.7)	X ² : 0.071	0.791
Narcotic use	6 (20)	7 (23.3)	X ² : 0.098	0.754

Data presented as mean ± SD, ratio, numbers & percentages; BMI: Body mass index; ASA: American Society of Anesthesiologists; FBG: Fasting blood glucose, PP: postprandial blood glucose, SAP: Systolic arterial pressure, DAP: Diastolic arterial pressure, NSAID: non-steroidal anti-inflammatory drugs.

* Significant P < 0.05

open up the correct plane, a hydro dissection using normal saline (NaCl 0.9%) was performed. Ropivacaine hydrochloride 20 mL was administered upon confirmation of the needle's proper insertion. On the other side, the identical procedure was followed.

After completion of the procedure, the inhalational anesthetic agent was discontinued. Neostigmine 0.05 mg/kg and atropine 0.01 mg/kg were used to reverse residual neuromuscular block before patients were extubated and sent to the post-anesthesia care unit (PACU). Postoperative analgesia was given as an IV morphine supplement as per the patients' demand.

2.1. The outcome measures

The primary outcome was postoperative NRS, and it

was evaluated and documented by an anesthesiologist who was blind to the treatment groups upon admission to the Recovery Unit, at 4, 8, 12, 18, and 24 h following the surgery.

Secondary outcomes were the amount of sevoflurane consumed during surgery, the time to awaken (the period between stopping anesthetic drugs till the patients became awake and extubated), time for PACU transfer (time passed between awakening till transfer to PACU), time of the first dose of rescue analgesia (morphine), the number of patients who received rescue analgesia and total consumption of rescue analgesia.

2.2. Sample size calculation

The sample size was calculated based on the following considerations: confidence limit of 95 %, 90% power of the study, and 1:1 group-to-group ratio to be ≥ 26 in each group, using GPower 3.1. We included 30 patients in each group.

2.3. Statistical analysis

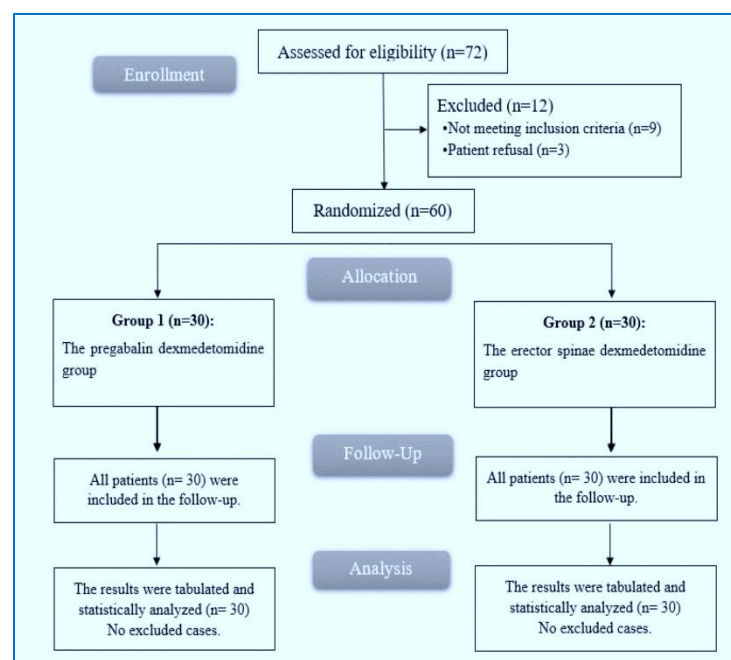


Figure 1: CONSORT flowchart of the enrolled patients

The numerical data was recorded in SPSS 24, IBM, Armonk, NY, USA. Mean and standard deviations were used to represent quantitative data. When comparing two means, the independent-samples t-test was used. Frequency (percentage) was used to describe qualitative data. To compare percentages between two qualitative factors, the Chi-square (X^2) test was used. Data which was abnormally distributed, is represented as a

median and interquartile range (IQR), and the Mann-Whitney was used to compare the two research groups. $P \leq 0.05$ is considered significant.

3. RESULTS

Initially, 72 patients were screened for eligibility; 7 patients declined to participate and 5 patients did not meet the inclusion criteria. The remaining 60 patients were randomly allocated into two equal groups: the pregabalin group (Group 1) and the erector spinae group (Group 2) (Figure 1).

Demographic characteristics of the enrolled participants regarding age, sex, body mass index and ASA classification showed no significant statistical difference in both groups (Table 1).

Intraoperatively, the sevoflurane consumption was significantly less in the pregabalin group compared to the ESPB group ($P = 0.033$), and the emergence time to awakening and time to being ready for PACU transfer were also significantly shortened in Group 1, compared to the Group 2, ($P = 0.022$ and 0.014) respectively. Surgery time was equivalent in both studied groups (Table 2).

Postoperatively, NRS scores during rest and movement were recorded on arrival at PACU, then at 4, 8, 12, 18, and 24 h. The analgesia was prolonged in the Group 2,

expressed in significantly lower NRS only at 12 and 18 h ($P = 0.001$) compared to Group 1. It was comparable at 24 h ($P = 0.407$) as shown in Table 3. The time to the first rescue analgesic and the total number of morphine doses were significantly higher in Group 2 ($P < 0.05$) (Table 4). More patients from Group 1 (8 patients, 26.7%) needed rescue analgesics compared to Group 2 (4 patients, 13.3%) (Table 4).

Table 2: Intraoperative data measured in both groups.

Variables	Group 1	Group 2	T-test	P value
Intraoperative Sevoflurane consumption (mL)	31.63 ± 3.11	33.40 ± 3.16	2.182	0.033*
Emergence time to awakening (min)	3.42 ± 1.15	4.10 ± 1.09	2.352	0.022*
Time till being ready to PACU transfer (min)	4.44 ± 1.09	5.15 ± 1.08	2.536	0.014*
Total OR time (min)	124.0 ± 14.12	129.23 ± 15.31	1.377	0.174

Data are presented as mean ± SD; * Significant $P < 0.05$

Table 3: NRS scores in both groups

Time	Group 1 N = 30	Group 2 N = 30	Z test	P value
On arrival at PACU	1 (1-2)	1.5 (1-2)	0.772	0.440
4h	2 (1-3)	2 (1-3)	0.183	0.855
8h	2 (1-5)	2 (1-3)	0.338	0.736
12h	3 (2-5)	2 (1-4)	3.344	0.001*
18h	3 (2-5)	2 (1-4)	3.450	0.001*
24h	2 (1-3)	2 (1-3)	0.830	0.407

Data are presented as mean ± SD; PACU = post anesthesia care unit, NRS = Numerical rating scale.

* Significant $P < 0.05$.

Table 4: Time of first rescue analgesic in hours, Total doses of rescue analgesic (Morphine in mg) and Number of patients who need rescue analgesia.

Parameter	Group 1 N = 30	Group 2 N = 30	T-test	P value
Time of first rescue analgesic (h)	11.73 ± 2.52 (8-16)	17.10 ± 3.06 (12-21)	7.424	0.001*
Total doses of rescue morphine (mg).	10.33 ± 2.68 (5-15)	6.30 ± 2.14 (3-10)	6.443	0.001*
No. of patients who needed rescue analgesia	8 (26.7)	4 (13.3)	Chi-square 1.667	0.197

Data are presented as mean ±SD or number (percentage); * Significant $P < 0.05$

Table 5: Complications in both groups

Complication	Group 1 N = 30	Group 2 N = 30	X2	P value
Bradycardia	4 (13.3)	0 (0)	4.286	0.038*
Hypotension	2 (6.7)	0 (0)	2.069	0.150
Nausea and vomiting	0 (0)	2 (6.7)	2.069	0.150
Sedation and dizziness	4 (13.3)	0 (0)	4.286	0.038*

*Data are presented as numbers (percentages); * Significant P < 0.05.*

Intraoperatively, 4 (13.3%) patients developed bradycardia, and 2 (6.7%) patients developed hypotension. In the Group 1, two patients had more sedation and dizziness, and 2 patients had postoperative nausea and vomiting in Group 2 (Table 5).

4. DISCUSSION

Severe pain caused by surgical injury to different anatomical structures results in the activation of different processes that include nociceptors, inflammatory mediators, and mechanoreceptors;¹ and may produce different types of pain, such as nociceptive or neuropathic pain, which may persist as long as third postoperative day.^{13,14}

Prompt mobilization and hospital discharge are goals of good surgical outcomes, that are in turn directly related to suitable pain management. Thus, reducing postoperative morbidity and mortality through declining thromboembolic and pulmonary complications.

In our study, we used two different modes of multimodal analgesia: one using pregabalin and the other one using a peripheral nerve block as ESPB. A multimodal analgesia regimen provides effective, safe and high-quality analgesia with a lower extent of vomiting, nausea, and respiratory depression united to high doses of opioids.¹⁴

Our results showed a comparable reduction in NRS on arrival at PACU, and at 4, 8 and 24 h after surgery, with a significant decrease in NRS at 12 h and 18 h in the ESPB group versus the pregabalin group. These findings were accompanied by a significant reduction in sevoflurane consumption (P = 0.033) with a significant early recovery time records (P = 0.022 and 0.014), respectively.

In our study, bilateral ESPB and preoperative administration of pregabalin as preemptive painkiller techniques resulted in a significant reduction in intraoperative and postoperative opioid use in patients having lumbar spine operations. However, the ESPB group was better in a more prolonged time to first

analgesic request, as well as decreased number of patients who needed postoperative analgesia.

According to a meta-analysis by Cliff K.-S. Ong et al., preventive analgesic therapies may diminish postoperative pain scores, reduce the need for further postoperative analgesics, and prolong the time before the first rescue analgesic request.¹⁶

According to the literature, pregabalin and gabapentin have anti-hyperalgesia and antiallodynic properties that are effective for treating neuropathic pain and have a beneficial function in the management of acute postoperative pain.^{17,18} Our results agreed with a meta-analysis that studied the effects of administering pregabalin 2h and 24 h after the procedure in different types of surgeries, demonstrating a strong directory to consider pregabalin use in postoperative pain.^{19,20} A prior meta-analysis on 11 RCTs concluded that preoperative pregabalin administration reduced 2-h pain scores and postoperative opioid demand. The authors grouped the trials under review by pregabalin dose, more than 300 mg or less than 300 mg, and reported that the higher dose reduces opioid usage more than the lower dose. Pregabalin significantly reduced opioid-related side effects like vomiting, but the visual instability risk was dominant and recommended further studies for chronic pain.²¹

This could explain why no patient had post-surgical vomiting and nausea in the pregabalin group, although both groups were given dexmedetomidine Intraoperatively, irrespective of opioid consumption.

Another meta-analysis of 55 RCTs found that when all dosages and administration methods were combined, pregabalin was related to a major reduction in pain scores during movement and at rest, as well as opioid consumption at 24 h, when compared to placebo.²² Another meta-analysis found that pregabalin causes statistically significant reductions in pain scores 2 h after surgery.²³⁻²⁵ Lara Giansello et al. And SSJoshi et al. Demonstrated a reduction in VAS after using pregabalin 300 mg and 150 mg 1 h and 2 h in the preoperative time and persisted pregabalin medication for 48 h after surgery.^{26,27}

Müller J, Plöchl W, et al. performed a recent meta-analysis that concluded that using 300 mg of pregabalin reduced the MAC of sevoflurane by 33%. However, 150 mg pregabalin administration did not substantially reduce the MAC of sevoflurane.²⁸

Ultrasound-guided ESPB has been studied in many works of literature and reported its role in postoperative analgesia, but still, there is no strong proof for its effectiveness as these studies vary whether it compared this block with a control or other type of block.

S. Singh et al. and Ahmet Murat Yayik et al. conducted bilateral preoperative US-ESPB and affected worse effects on pain control compared to traditional postoperative analgesia following lumbar spine procedures.^{29,30} Similar findings were noted by G. TRAN et al., who concluded that US-ESPB minimized analgesic consumption and amended analgesia.³¹ The majority of authors agree that ESPB offers significant benefits over traditional methods used in close proximity to the neuroaxis. Firstly, it is a simple procedure to use as it is easier to visualize the goal using ultrasound and straight forward to direct the needle in that direction. Secondly, the risk of complications from the procedure is quite low.

The target of the blockage is far from important structures (such as pleura, medulla, or main vessels) whose destruction might result in catastrophic consequences. Although it has been suggested by a number of authors that the ESP block and retrolaminar block are the same approaches.^{32,33}

Additionally, when the epidural or paravertebral block is contraindicated due to the patient's refusal, an ESP block has been recommended as an effective substitute.^{34,35}

Cheung CW et al. studied the effects of using dexmedetomidine in a loading dose of 1 µg/kg for 1 min and then continuous infusion at 0.5 µg/kg/h in laparoscopic colorectal surgery, and reported reduce in NRS up to 48 h after surgery.³⁶ This was manifested in our findings through lowering fentanyl intraoperative use and total morphine in the postoperative time. This is in contrast to the study literature that reported that dexmedetomidine and pregabalin together showed no synergistic effect when compared to dexmedetomidine on its own.³⁷

Premedication with 150 mg of oral pregabalin for adults before optional spinal surgery made it easier to induce hypotension. It also greatly reduces the stress response to tracheal intubation and can provide postoperative analgesia.³⁸ In a separate study, Gupta et al. used the same dosage of oral pregabalin and found that it significantly reduced HR and MAP during laryngoscopy while maintaining intraoperative stability when compared to the control group.³⁹ This stability caused by pregabalin might be explained by its appropriate analgesic and sedative properties, which include the modulation of central sensitization and visceral pain.^{40,41}

5. LIMITATIONS

The sample size was small. More randomized trials need to be conducted on larger samples of patients using different concentrations of studied medications to verify and support our findings.

6. CONCLUSIONS

Both bilateral ultrasound guided erector spinae plane block and preoperative use of pregabalin seems to be useful methods for providing adequate pain management during both intra-operative and postoperative periods for patients undergoing lumbar spine surgery. However, ultrasound guided erector spinae plane block was superior in pain management during the first 24 h postoperative with fewer side effects.

7. Conflict of Interest

All authors have no conflict of interest. No funding was received for this research.

8. Availability of data

The datasets generated and/or analyzed during the current study are available from the corresponding author upon reasonable request.

9. Ethical approval

The study was approved by the Ethical Committee and Institutional Review Board of the Faculty of Medicine, Tanta University with approval code (35692/9/22).

10. Author contributions

All authors contributed to the study conception and design. Material preparation, data collection and analysis were performed by Rabab M. Mohamed and Jehan M. Darwish. The first draft of the manuscript was written by Rabab M. Mohamed, and all authors commented on previous versions of the manuscript. All authors read and approved the final manuscript.

11. REFERENCES

1. Bajwa SJ, Haldar R. Pain management following spinal surgeries: an appraisal of the available options. *J Craniovertebr Junction Spine.* 2015;6(3):105–10. [PubMed] DOI: [10.4103/0974-8237.161589](https://doi.org/10.4103/0974-8237.161589)
2. Kurd MF, Kreitz T, Schroeder G, Vaccaro AR. The role of multimodal analgesia in spine surgery. *J Am Acad Orthop Surg.* 2017;25:260–8. [PubMed] DOI: [10.5435/JAAOS-D-16-00049](https://doi.org/10.5435/JAAOS-D-16-00049)
3. Forero M, Adhikary SD, Lopez H, Tsui C, Chin KJ. The erector spinae plane block: a novel analgesic technique in thoracic neuropathic pain. *Reg Anesth Pain Med.* 2016;41:621–7. [PubMed] DOI: [10.1097/AAP.0000000000000451](https://doi.org/10.1097/AAP.0000000000000451)

4. Ben-Menachem E. Pregabalin pharmacology and its relevance to clinical practice. *Epilepsia*. 2004;45 Suppl 6:13-8. [PubMed] DOI: [10.1111/j.0013-9580.2004.455003.x](https://doi.org/10.1111/j.0013-9580.2004.455003.x)
5. Bryans JS, Wustrow DJ. 3-substituted GABA analogs with central nervous system activity: a review. *Med Res Rev*. 1999 Mar;19(2):149-77. [PubMed] DOI: [10.1002/\(sici\)1098-1128\(199903\)19:2<149::aid-med3>3.0.co;2-b](https://doi.org/10.1002/(sici)1098-1128(199903)19:2<149::aid-med3>3.0.co;2-b)
6. Khan ZP, Ferguson CN, Jones RM. alpha-2 and imidazoline receptor agonists. Their pharmacology and therapeutic role. *Anaesthesia*. 1999 Feb;54(2):146-65. [PubMed] DOI: [10.1046/j.1365-2044.1999.00659.x](https://doi.org/10.1046/j.1365-2044.1999.00659.x)
7. Maze M, Scarfani C, Cavaliere F. New agents for sedation in the intensive care unit. *Crit Care Clin*. 2001 Oct;17(4):881-97. [PubMed] DOI: [10.1016/s0749-0704\(05\)70185-8](https://doi.org/10.1016/s0749-0704(05)70185-8)
8. Bekker AY, Kaufman B, Samir H, Doyle W. The use of dexmedetomidine infusion for awake craniotomy. *Anesth Analg*. 2001 May;92(5):1251-3. [PubMed] DOI: [10.1097/0000539-200105000-00031](https://doi.org/10.1097/0000539-200105000-00031)
9. Mack PF, Perrine K, Kobylarz E, Schwartz TH, Lien CA. Dexmedetomidine and neurocognitive testing in awake craniotomy. *J Neurosurg Anesthesiol*. 2004 Jan;16(1):20-5. [PubMed] DOI: [10.1097/00008506-200401000-00005](https://doi.org/10.1097/00008506-200401000-00005)
10. Scheinin H, Aantaa R, Anttila M, Hakola P, Helminen A, Karhuvaara S. Reversal of the sedative and sympatholytic effects of dexmedetomidine with a specific alpha 2-adrenoceptor antagonist atipamizole: A pharmacodynamic and kinetic study in healthy volunteers. *Anesthesiology*. 1998;89:574. DOI: [10.1097/0000542-199809000-00005](https://doi.org/10.1097/0000542-199809000-00005)
11. Fusco P, Di Carlo S, Scimia P, Luciani A, Petrucci E, Marinangeli F. Could the new ultrasound-guided erector spinae plane block be a valid alternative to paravertebral block in chronic chest pain syndromes?. *Minerva Anesthesiol*. 2017 Oct;83(10):1112-1113. [PubMed] DOI: [10.23736/S0375-9393.17.12109-7](https://doi.org/10.23736/S0375-9393.17.12109-7)
12. Gerbershagen HJ, Aduckathil S, van Wijck AJ, Peelen LM, Kalkman CJ, Meissner W. Pain intensity on the first day after surgery: a prospective cohort study comparing 179 surgical procedures. *Anesthesiology*. 2013 Apr;118(4):934-44. [PubMed] DOI: [10.1097/ALN.0b013e31828866b3](https://doi.org/10.1097/ALN.0b013e31828866b3)
13. Aqua K, Gimbel JS, Singla N, Ma T, Ahdieh H, Kerwin R. Efficacy and tolerability of oxymorphone immediate release for acute postoperative pain after abdominal surgery: a randomized, double-blind, active- and placebo-controlled, parallel-group trial. *Clin Ther*. 2007 Jun;29(6):1000-12. [PubMed] DOI: [10.1016/j.clinthera.2007.06.001](https://doi.org/10.1016/j.clinthera.2007.06.001)
14. Bianconi M, Ferraro L, Ricci R, Zanoli G, Antonelli T, Giulia B, et al. The pharmacokinetics and efficacy of ropivacaine continuous wound installation after spine fusion surgery. *Anesth Analg*. 2004;98:166-172. [PubMed] DOI: [10.1213/01.ANE.0000093310.47375.44](https://doi.org/10.1213/01.ANE.0000093310.47375.44)
15. Loftus RW, Yeager MP, Clark JA, Brown JR, Abdu WA, Sengupta DK, et al. Intraoperative ketamine reduces perioperative opiate consumption in opiate-dependent patients with chronic back pain undergoing back surgery. *Anesthesiology*. 2010;113:639-646 [PubMed] DOI: [10.1097/ALN.0b013e3181e90914](https://doi.org/10.1097/ALN.0b013e3181e90914)
16. Ong CK, Lirk P, Seymour RA, Jenkins BJ. The efficacy of preemptive analgesia for acute postoperative pain management: a meta-analysis. *Anesth Analg*. 2005 Mar;100(3):757-773. [PubMed] DOI: [10.1213/01.ANE.0000144428.98767.0E](https://doi.org/10.1213/01.ANE.0000144428.98767.0E)
17. Tiippana EM, Hamunen K, Kontinen VK, Kalso E. Do surgical patients benefit from perioperative gabapentin/pregabalin? A systematic review of efficacy and safety. *Anesth Analg*. 2007;104(6):1545-56. [PubMed] DOI: [10.1213/01.ane.0000261517.27532.80](https://doi.org/10.1213/01.ane.0000261517.27532.80)
18. Rorarius MG, Mennander S, Suominen P, Rintala S, Puura A, Pirhonen R, et al. Gabapentin for the prevention of postoperative pain after vaginal hysterectomy. *Pain*. 2004;110:175-81. [PubMed] DOI: [10.1016/j.pain.2004.03.023](https://doi.org/10.1016/j.pain.2004.03.023)
19. Lam DMH, Choi SW, Wong SSC, Irwin MG, Cheung CW. Efficacy of Pregabalin in acute postoperative pain under different surgical categories: a meta-analysis. *Medicine (Baltimore)*. 2015 Nov;94(46):e1944. [PubMed] DOI: [10.1097/MD.0000000000001944](https://doi.org/10.1097/MD.0000000000001944)
20. Mishriky BM, Waldron NH, Habib AS. Impact of pregabalin on acute and persistent postoperative pain: a systematic review and meta-analysis. *Br J Anaesth*. 2015 Jan;114(1):10-31. [PubMed] DOI: [10.1093/bja/aeu293](https://doi.org/10.1093/bja/aeu293)
21. Zhang J, Ho KY, Wang Y. Efficacy of Pregabalin in acute postoperative pain: a meta-analysis. *Br J Anaesth*. 2011;106:454-462. [PubMed] DOI: [10.1093/bja/aer027](https://doi.org/10.1093/bja/aer027)
22. Fassoulaki A, Melemini A, Tsaroucha A, Paraskeva A. Perioperative pregabalin for acute and chronic pain after abdominal hysterectomy or myomectomy: a randomised controlled trial. *Eur J Anaesthesiol*. 2012 Nov;29(11):531-6. [PubMed] DOI: [10.1097/EJA.0b013e32835800e0](https://doi.org/10.1097/EJA.0b013e32835800e0)
23. Aydoğan H, Kucuk A, Yuce HH, Karahan MA, Ciftci H, Gulum M, et al. Adding 75 mg pregabalin to analgesic regimen reduces pain scores and opioid consumption in adults following percutaneous nephrolithotomy. *Rev Bras Anesthesiol*. 2014 Sep-Oct;64(5):335-42. [PubMed] DOI: [10.1016/j.bjan.2013.08.001](https://doi.org/10.1016/j.bjan.2013.08.001)
24. Eskandar AM, Ebeid AM. Effect of Pregabalin on postoperative pain after shoulder arthroscopy. *Egypt J Anaesth*. 2013;29:363-367. DOI: [10.1016/j.egja.2013.07.001](https://doi.org/10.1016/j.egja.2013.07.001)
25. Lee JK, Chung KS, Choi CH. The effect of a single dose of preemptive Pregabalin administered with cox-2 inhibitor: a trial in total knee arthroplasty. *J Arthroplasty*. 2015;30:38-42. [PubMed] DOI: [10.1016/j.arth.2014.04.004](https://doi.org/10.1016/j.arth.2014.04.004)
26. Giansello L, Pavoni V, Barboni E, Galeotti I, Nella A. Perioperative pregabalin for postoperative pain control and quality of life after major spinal surgery. *J Neurosurg Anesthesiol*. 2012 Apr;24(2):121-6. [PubMed] DOI: [10.1097/ANA.0b013e31823a885b](https://doi.org/10.1097/ANA.0b013e31823a885b)
27. Joshi SS, Jagadeesh AM. Efficacy of perioperative pregabalin in acute and chronic post-operative pain after off-pump coronary artery bypass surgery: a randomized, double-blind placebo controlled trial. *Ann Card Anaesth*. 2013 Jul-Sep;16(3):180-5. [PubMed] DOI: [10.4103/0971-9784.114239](https://doi.org/10.4103/0971-9784.114239)
28. Müller J, Plöchl W, Mühlbacher P, Graf A, Stimpfl T, Hamp T. The Effect of Pregabalin on the Minimum Alveolar Concentration of Sevoflurane: A Randomized, Placebo-Controlled, Double-Blind Clinical Trial. *Front Med (Lausanne)*. 2022 May 3;9:883181. [PubMed] DOI: [10.3389/fmed.2022.883181](https://doi.org/10.3389/fmed.2022.883181)
29. Singh S, Choudhary NK, Lalin D, Verma VK. Bilateral Ultrasound-guided Erector Spinae Plane Block for Postoperative

- Analgesia in Lumbar Spine Surgery: A Randomized Control Trial. *J Neurosurg Anesthesiol.* 2020 Oct;32(4):330-334. [PubMed] DOI: [10.1097/ANA.0000000000000603](https://doi.org/10.1097/ANA.0000000000000603)
30. Yayik AM, Cesur S, Ozturk F, Ahiskalioglu A, Ay AN, Celik EC, et al. Postoperative Analgesic Efficacy of the Ultrasound-Guided Erector Spinae Plane Block in Patients Undergoing Lumbar Spinal Decompression Surgery: A Randomized Controlled Study. *World Neurosurg.* 2019 Jun;126:e779-e785. [PubMed] DOI: [10.1016/j.wneu.2019.02.149](https://doi.org/10.1016/j.wneu.2019.02.149)
 31. Tran G, Vyncke N, Montupil J, Bonhomm V, Defrense A. Is the Erector Spinae Plane block useful for antinociception and analgesia In lumbar spine surgery? A narrative review of the literature and opinion paper. *Acta Anaesth Bel.* 2022;73(2):109-118. DOI: [10.56126/73.2.13](https://doi.org/10.56126/73.2.13)
 32. Ueshima H, Otake H. Similarities Between the Retrolaminar and Erector Spinae Plane Blocks. *Reg Anesth Pain Med.* 2017 Jan/Feb;42(1):123-124. [PubMed] DOI: [10.1097/AAP.0000000000000526](https://doi.org/10.1097/AAP.0000000000000526)
 33. Bonvicini D, Tagliapietra L, Giacomazzi A, Pizzirani E. Bilateral ultrasound-guided erector spinae plane blocks in breast cancer and reconstruction surgery. *J Clin Anesth.* 2018;44:3-4. [PubMed] DOI: [10.1016/j.jclinane.2017.10.006](https://doi.org/10.1016/j.jclinane.2017.10.006)
 34. Adhikary SD, Pruet A, Forero M, Thiruvankatarajan V. Erector spinae plane block as an alternative to epidural analgesia for post-operative analgesia following video-assisted thoracoscopic surgery: A case study and a literature review on the spread of local anaesthetic in the erector spinae plane. *Indian J Anaesth.* 2018 Jan;62(1):75-78. [PubMed] DOI: [10.4103/ija.IJA_693_17](https://doi.org/10.4103/ija.IJA_693_17)
 35. Ueshima H, Hara E, Otake H. Retraction notice to " Clinical experiences of erector spinae plane block for children" [*J. Clin. Anesth.* 44(2018)41]. *J Clin Anesth.* 2022 Sep;80:110806. [PubMed] DOI: [10.1016/j.jclinane.2022.110806](https://doi.org/10.1016/j.jclinane.2022.110806)
 36. Cheung CW, Qiu Q, Ying AC, Choi SW, Law WL, Irwin MG. The effects of intra-operative dexmedetomidine on postoperative pain, side-effects and recovery in colorectal surgery. *Anaesthesia.* 2014 Nov;69(11):1214-21. [PubMed] DOI: [10.1111/anae.12759](https://doi.org/10.1111/anae.12759)
 37. Lee C, Lee J, Lee G, Lee H, Koh E, Hwang J. Pregabalin and Dexmedetomidine Combined for Pain After Total Knee Arthroplasty or Total Hip Arthroplasty Performed Under Spinal Anesthesia. *Orthopedics.* 2018 Nov 1;41(6):365-370. [PubMed] DOI: [10.3928/01477447-20181023-04](https://doi.org/10.3928/01477447-20181023-04)
 38. Mazy A, Abo-Zeid MA. Pregabalin effects on hypotensive anesthesia during spine surgery. *Res Opinion Anesth Intensive Care.* 2020;7(2):161-166. DOI: [10.4103/roaic.roaic_64_19](https://doi.org/10.4103/roaic.roaic_64_19)
 39. Gupta K, Bansal P, Gupta PK, Singh YP. Pregabalin premedication - A new treatment option for hemodynamic stability during general anesthesia: A prospective study. *Anesth Essays Res.* 2011 Jan-Jun;5(1):57-62. [PubMed] DOI: [10.4103/0259-1162.84192](https://doi.org/10.4103/0259-1162.84192)
 40. Ben-Menachem E. Pregabalin pharmacology and its relevance to clinical practice. *Epilepsia.* 2004;45 Suppl 6:13-8. [PubMed] DOI: [10.1111/j.0013-9580.2004.455003.x](https://doi.org/10.1111/j.0013-9580.2004.455003.x)
 41. Stawicki SP. Sedation scales: very useful, very underused. *OPUS 12 Scientist.* 2007;1(2):10-12. [FreeFullText]