

CASE REPORT

PERIOPERATIVE MEDICINE

A pregnant lady (G3P2A0) with fetal distress and brain tumor

Ardana Tri Arianto¹, Mohamad Ismu Heryadi²

Author affiliations;

1. Ardana Tri Arianto, Lecturer & Staff, Department of Anesthesia and Intensive Therapy, UNS Faculty of Medicine UNS, Dr. Moewardi Hospital, Surakarta, Central Java, Indonesia
2. Mohamad Ismu Heryadi, Resident, Department of Anesthesia and Intensive Therapy, UNS Faculty of Medicine, Dr. Moewardi Hospital, Surakarta, Central Java, Indonesia; E-mail: ismuadit90@gmail.com

Correspondence: Mohamad Ismu Heryadi, E-mail: ismuadit90@gmail.com; Phone: +62 821-1141-9662

ABSTRACT

Intracranial tumors or brain tumors are one of the most feared diseases because the brain is an important central organ. Brain tumors share several pathophysiologic features and may present with a variety of signs and symptom.

A 39-year-old female patient, G3P2A0 of 28 weeks gestation complained of frequent throbbing headaches for the last 2 y. On physical examination, she had decreased consciousness, fever and anisocor pupil. Laboratory tests found leukocytosis. Cerebral multi-slice computed tomography (MSCT) found heterodense lesion at intraaxial supratentorial region with irregular border, necrotic components and bleeding in the right basal ganglia to the right temporal lobe. There were signs of fetal distress on cardiotocography (CTG).

Management during pregnancy depends on the nature of the tumor. There may be some conflict between maternal and fetal interests in the patient with increased ICP. The patient was diagnosed with brain tumor in the right basal ganglia and undergoing treatment in the ICU. As a 28-week pregnant patient with fetal distress diagnosed with brain tumor, she needed to be observed and periodically evaluated. However, the patient's prognosis was *dubia ad malam*.

Key words: Brain Tumor; Fetal Distress; Pregnancy

Citation: Arianto AT, Heryadi MI. A pregnant lady (G3P2A0) with fetal distress and brain tumor. *Anaesth. pain intensive care* 2023;27(6):772-775; DOI: [10.35975/apic.v27i6.2233](https://doi.org/10.35975/apic.v27i6.2233)

Received: May 22, 2023; **Revised:** August 08, 2023; **Accepted:** October 22, 2023

1. INTRODUCTION

Intracranial neoplasms vary in incidence, histology, clinical presentation, and prognosis. Intracranial tumors or brain tumors are one of the most feared diseases because the brain is a very important central organ. The incidence of brain tumors is 14,800 per 100,000 person-years, with about half being histologically benign. Women have a slightly higher incidence (15.1/100,000 people per year) than men (14.3/100,000 people per year), probably because of the high incidence of meningiomas in women. Brain neoplasms in pregnant women appear to occur with the same relative frequency as in nonpregnant women; however, the physiologic alterations that occur during pregnancy can have profound implications for symptomatology and

management. Gliomas are the most common intracranial neoplasms, accounting for approximately 39% of all primary intracranial tumors. These tumors, which result from anaplasia of astrocytes, exhibit diversity in invasive potential and include glioblastoma multiforme, astrocytomas, ependymomas, and oligodendrocytomas. Glioblastoma multiforme is the most lethal, whereas oligodendrocytomas have a better prognosis.^{1,2}

Meningiomas account for approximately one-third of all primary brain tumors. These benign tumors originate from the dura mater or arachnoid. Surgery typically is curative. Pituitary adenomas account for 7% of diagnosed primary brain neoplasms. Only a small fraction of these tumors cause symptoms (e.g., visual field deficits). These tumors may secrete prolactin, growth hormone, or adrenocorticotrophic hormone.

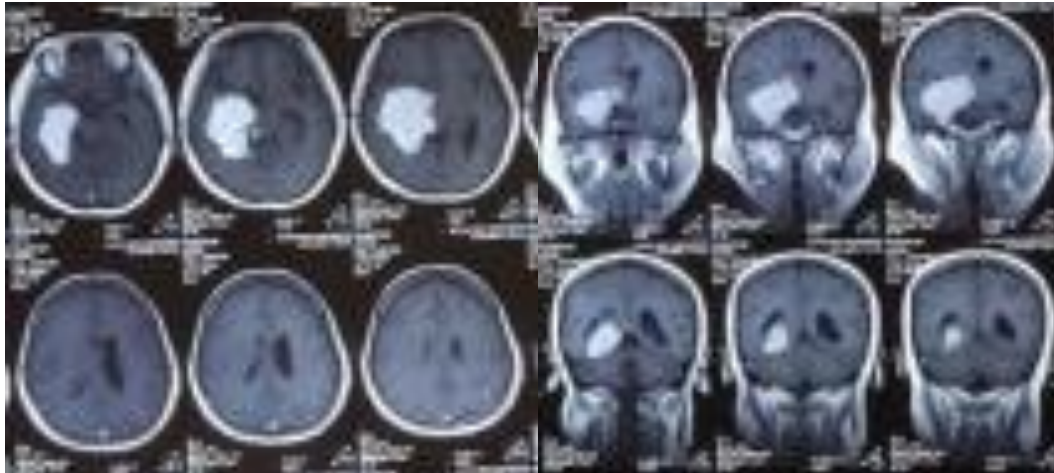


Figure 1: Result of MSCT examination of head with reformat 3D without contrast

Tumor growth is physically limited by the sella turcica of the sphenoid bone and the hypothalamus. The resulting compression of the hypothalamus or pituitary gland may cause decreases in the production or release of vasopressin, leading to diabetes insipidus. The pituitary gland normally enlarges during pregnancy, and this additional growth may cause symptoms in a woman who was previously asymptomatic. Women with known microadenomas should be carefully monitored during pregnancy to detect symptoms of pituitary compression. Growth of pituitary tumors can be triggered by breastfeeding.¹

Bromocriptine often provides effective medical therapy for prolactin-secreting adenomas and has a track record of use during pregnancy; its continued use during breastfeeding must be balanced against its suppressive effect on lactation. Surgery is indicated for tumors that do not respond to medical management. Schwannomas, also called neurinomas, account for 7% of all brain tumors. These lesions originate in the Schwann cells surrounding the nerve. Clinical presentation depends on the location of the tumor. Acoustic neuromas result when the eighth cranial nerve is involved; these lesions are often seen in patients with neurofibromatosis. The treatment is surgical excision. Metastatic carcinomas account for a significant number of brain neoplasms. Common primary cancers include those of the lung, breast, and colon. Prognosis and therapy depend on the tumor of origin.^{1,2}

Brain tumors share several pathophysiologic features. Neurologic deficits can result from a mass effect or increased ICP, even if the tumor is benign. Brain edema, which may result from a combination of vasogenic and cytotoxic mechanisms, is a prominent feature of cerebral neoplasms. The potential for herniation must be considered in any patient with a mass lesion. The brain

is divided into three basic compartments. The falx cerebri separates the cerebrum into right and left halves, and the tentorium isolates the cerebellum. High pressure from a mass can cause shifts from one compartment to another with devastating effects.¹ The anesthetists must acquire adequate knowledge about different types of intracranial tumors and their behavior.

2. CASE REPORT

A 39-year-old female patient came was referred from PKU Muhammadiyah Solo Hospital with decreased consciousness for one day. The family stated that the patient complained of frequent headaches and felt intermittent cranial throbbing since the last 2 y. The patient had been planned for surgery but not scheduled for it. She was 28 weeks pregnant with G3P2A0. On physical examination, GCS consciousness E1VxM1 with anisocor pupil, BP-131/78 mmHg, HR-108 bpm regular, CRT < 2" and regular heart sound, body temperature -37.9°C.

Laboratory investigations showed leukocytosis. multi-slice computed tomography (MSCT) of head with reformat 3D without contrast found heterodense lesion (23-36 HU) intraaxial supratentorial irregular border with necrotic components and bleeding in the right basal ganglia to the right temporal lobe, size 4.2 x 6.7 x 5.09 cm with surrounding vasogenic edema.

The lesion appeared to press and constrict the anterior temporal and posterior horns of the right lateral ventricle and caused dilatation of the anterior horn, posterior et temporalis of the left lateral ventricle and midline shifting to the left as far as 0.6 cm. Hyperdense blood density (60 HU) lesions appeared in the posterior horn of the right lateral ventricle.

The patient was treated in the ICU of Dr. Moewardi Hospital and received therapy in the form of oxygen on mechanical ventilator, mannitol 100 ml/6 h, RF infusion 30 ml/h, Ampicillin sulbactam 1.5 G/8 h, paracetamol 1G/8 h, dexamethasone 5 mg/6 h and ranitidine 50 mg/12 h. Patient was also monitored for EtCO₂ and level maintained in the range of 31-36 mmHg. The patient was evaluated by the obstetrics department and still found FHR at 113-129 beats/min with signs of fetal distress on CTG images.

During treatment in the ICU the patient experienced hemodynamic instability with blood pressure tending to fall below 80/50 mmHg with MAP less than 65 and HR increasing to 120-130/min. SpO₂ 92-93% with cold extremities and CRT >2 sec, so the patient was started on norepinephrine at a dose of 0.05 µg/kg/min titrated according to BP. Evaluation of FHR was also carried out periodically, with periods when FHR reached 80-90/min. After starting vasopressor administration, the patient was hemodynamically stable with 100-130 systolic and 60-90 mmHg diastolic BP and HR 80-90/min and FHR at 120-130/min.

3. DISCUSSION

Brain tumors present different clinical problems from other tumors because of their effects and the limitations of available therapies. Brain tumors that cause damage to brain tissue directly will cause functional disorders of the central nervous system. The mass effect caused by a brain tumor will also pose a serious problem considering that the tumor is in the skull cavity which in adults is a closed space with a fixed size. Patients with a history of brain tumors, often complain of severe headaches that come and go but feel that the intensity is getting more frequent and getting more severe. Previously, our patient was known to have experienced gushing vomiting before slowly losing consciousness. The patient's condition did not allow for surgery at the time because the current GCS E1VxM1 and being the hemodynamically unstable.^{1,3}

During treatment in the ICU, the patient experienced hemodynamic instability with blood pressure tending to fall below 80/50 mmHg with a MAP < 65 mmHg, thus requiring vasopressor support in the form of norepinephrine titrated gradually from 0.05 µg/kg/min, so that the MAP was adequate and still able to maintain uteroplacental blood flow to reduce fetal distress. Ventilation of the patient was also maintained to avoid hypocapnia which would cause vasoconstriction of the uterine arteries. Although pregnancy does not affect the incidence of brain tumors, some of these lesions appear to grow faster during pregnancy. Visual field defects from pituitary adenomas worsen as a result of tumor enlargement during pregnancy, and symptoms have been observed to improve during the postpartum period.

Edema and the increased blood volume may account for some of these symptoms. Pregnancy-induced hormonal changes also may play a role because estrogen and progesterone receptors are present in meningiomas and some gliomas.^{1,3}

Management during pregnancy depends on the nature of the tumor. Surgery for benign tumors (e.g., meningiomas) with mild symptoms can often be delayed until after delivery. Women with more aggressive, malignant tumors or with tumors causing seizures or severe visual impairment may require urgent surgery during pregnancy to avoid acute neurologic deterioration. Delivery also may be recommended as soon as reasonable fetal survival can be expected, sometimes by cesarean delivery immediately before neurosurgery. For women with pregnancies far from fetal viability, radiation therapy or stereotactic radiosurgery can be considered. Cranial radiation therapy is generally administered as a first therapeutic procedure to reduce the size of the mass in cases of aggressive neoplasm. However, radiation therapy, and particularly systemic chemotherapy, can pose significant hazards to the fetus, especially when administered during the first trimester. Some women may opt for surgery after an elective abortion.^{1,4}

There may be some conflict between maternal and fetal interests in the patient with increased ICP. Moderate mechanical hyperventilation may be used to reduce the increased ICP that occurs in nonpregnant patients with a brain tumor or brain injury. Minute ventilation increases during normal pregnancy, resulting in a maternal PaCO₂ of 28-32 mmHg, additional hyperventilation and hypocapnia may cause uterine artery vasoconstriction and a leftward shift in the maternal oxyhemoglobin dissociation curve. Another physiological change is an increase in blood volume reaching 30-50%, followed by an increase in cardiac output.^{1,3,4,5} For pregnant women with an acute increase in ICP, Wang and Paech have suggested a target PaCO₂ range of 25-30 mmHg; however, data are currently insufficient to support evidence-based recommendations specific to pregnant women undergoing intracranial surgery. In pregnant patients with increased ICP, we recommend maintenance of maternal PaCO₂ in the middle or at the lower end of the normal range for pregnancy.^{1,3,4}

4. CONCLUSION

The patient was diagnosed with a brain tumor in the right basal ganglia and is currently undergoing treatment in the ICU. The patient is also currently diagnosed as being 28 weeks pregnant G3P2A0 with fetal distress and is under observation and periodic evaluation clinically of the patient and the fetus. However, the patient's

prognosis remains *dubia ad malam* (doubtful, tend to be bad).

5. Conflict of interest

The authors declare no conflict of interest, and there was no external funding was involved.

6. Authors' contribution

All authors were involved in the conduct of the case and manuscript preparation.

7. REFERENCES

1. Chestnut DH. Chestnut's obstetric anesthesia: principles and practice. Philadelphia: Elsevier; 2009.

2. Norman SW, Christopher JKB. Bailey & Love's Short Practice of Surgery. 25th ed. Arnold; 2008. p. 631-635.
3. Mezzacappa FM, Thorell W. Neuronal Brain Tumors. Treasure Island (FL): StatPearls Publishing; 2022. Available from: <https://www.ncbi.nlm.nih.gov/books/NBK576406/>
4. Abdel Razek AAK, Elsebaie NA, Zamora C, Castillo M. Imaging of Neuronal and Mixed Glioneuronal Tumors. J Comput Assist Tomogr. 2020 May/Jun;44(3):356-369. [PubMed] DOI: [10.1097/RCT.0000000000001010](https://doi.org/10.1097/RCT.0000000000001010)
5. Yudhatama Y. Anesthesia management in pregnancy with heart disorder using walking epidural analgesia (WELA). Solo J Anesthesi Pain Criti Care. 2022 Oct;2(2):69-73. DOI: [10.20961/soja.v2i2.59805](https://doi.org/10.20961/soja.v2i2.59805)