

ORIGINAL RESEARCH

ORTHOPEDIC ANESTHESIA

Impact of femoral nerve block versus fascia iliaca block on postoperative pain control after hip arthroscopy: a prospective randomized trial

Amin M. Alasnsary^{1*}, Mohamed O Elgouhary², Mohamed M Rashed³, Mohamed M Ali⁴

Author affiliations:

1. Amin Mohammed Alansary, Assistant Professor of Anesthesia, Intensive Care & Pain Management, Faculty of Medicine, Ain Shams University, Cairo, Egypt; E-mail: aminalansary@yahoo.com; ORCID : 0000-0002-6615-186X
2. Mohamed O Elgouhary .Lecturer of Anesthesia, Intensive Care & Pain Management, Faculty of Medicine, Ain Shams University, Cairo, Egypt; E-mail: drelgouhary2008@gmail.com
3. Mohamed Mohsen Rashed, Lecturer of Anesthesia, Intensive Care & Pain Management, Faculty of Medicine, Ain Shams University, Cairo, Egypt; E-mail: Mohsen.Mohamed1983@gmail.com; ORCID : 0000-0001-9649-5930
4. Mohamed Mourad Ali, Lecturer of Anesthesia, Intensive Care & Pain Management, Faculty of Medicine, Ain Shams University, Cairo, Egypt; E-mail: Mohamed_mourad@med.asu.edu.eg; ORCID: 0000-0003-4667-5719

Correspondence: Amin Mohamed Alansary; E-mail: Aminalansary@yahoo.com; Tel: +20 1007962192

Abstract

Background & Objectives: Hip arthroscopy is a minimally invasive technique that has been widely used to treat a variety of hip joint diseases. However, severe postoperative pain usually follows these surgeries, necessitating the use of multimodal pain control strategies. Regional blocks like femoral nerve block (FNB) and fascia iliaca compartment block (FICB) allow for better postoperative analgesia while using less parenteral opioids. The purpose of this study was to evaluate and compare the efficacy of ultrasound guided FNB versus ultrasound guided FICB for postoperative analgesia.

Methodology: A total of 60 patients, planned for hip arthroscopy, aged 21–65 y, of either sex and ASA I–II were randomly divided into two groups: Group FICB (n = 30), in which FICB with 40 mL levobupivacaine 0.25% was done after induction of general anesthesia (GA) and Group FNB (n = 30) in which FNB with 20 mL levobupivacaine 0.25% was done after induction of GA. Time to the first analgesic use was the primary outcome, whereas total pethidine consumption as rescue analgesic in the first 24 h postoperatively, VAS scores, and the assessment of postoperative early ambulation were the secondary outcomes.

Results: Patients in the Group FICB experienced a significantly shorter time to ambulation compared to Group FNB; 17.2 ± 2.1 vs. 19.8 ± 2.1 h respectively ($P < 0.001$). There were no significant differences between the two groups regarding time to first analgesic requirement (pethidine), total pethidine consumption, and the VAS scores. No cases of drug allergy were reported in both groups.

Conclusion: Both fascia iliaca compartment block and femoral nerve block were effective in reducing postoperative pain; however, fascia iliaca compartment block was superior regarding early ambulation.

Abbreviations: FNB: Femoral Nerve Block; FICB: Fascia Iliaca Compartment Block; GA: General Anesthesia; US: Ultrasound; VAS: Visual Analog Scale

Key words: Hip arthroscopy; Fascia iliaca compartment block; Femoral Nerve Block; Pain; Pain Management; Postoperative pain

Citation: Alasnsary AM, Elgouhary MO, Rashed MM, Ali MM. Impact of femoral nerve block versus fascia iliaca block on postoperative pain control after hip arthroscopy: a prospective randomized trial. *Anaesth. pain intensive care* 2022;27(1):23–30; DOI: 10.35975/apic.v27i1.2120

Received: September 10, 2022; **Reviewed:** November 05, 2022; **Accepted:** November 16, 2022

1. Introduction

Hip arthroscopy is a minimally invasive technique and is now being used more frequently.¹ Hip arthroscopy is safer and has a quicker recovery time and fast return to function and activity than open surgical procedures.² The primary indication for arthroscopic hip surgery is femoro-acetabular impingement syndrome.^{3,4} Branches of the lumbar plexus, the femoral nerve (FN), the obturator nerve (ON), and the sciatic nerve (SN) all innervate the hip joint. The skin at the arthroscopic portal entry sites is innervated by the lateral femoral cutaneous nerve (LFCN).⁵

Regional anesthetic techniques underwent a revolution following the development of ultrasound. Every nerve block can be carried out under ultrasound (US) guidance. The use of US enables the visualization of nerves, nearby structures, needles, and local anesthetic spread.

FNB provides anesthesia and analgesia through the saphenous nerve to the anterior thigh, hip, femur, knee, and medial lower leg and foot. It is a quite basic technique with an elevated success rate, minimal complications, and wide clinical utility for postoperative analgesia in hip arthroscopy, after hip fracture fixation and hip arthroplasty.⁶ In order to perform FICB, a significant amount of local anesthetic solution must be injected deep to the fascia iliaca and spread to the terminal branches of the lumbar plexus.^{7,8} Without bringing the needle close to the nerves, the FN and possibly the LFCN can be blocked using the FICB.⁹

Postoperative analgesia has a significant effect on early ambulation, decreasing the risk of thrombotic events, and quicker recovery.¹⁰ Multi-modal analgesia regimens with peripheral nerve blocks are strongly recommended for pain management in hip joint arthroscopy and arthroplasty.¹¹

The current clinical trial was aimed to evaluate the efficacy of FNB vs. FICB for intraoperative and postoperative pain control in hip arthroscopy as well as the effect on the motor activity required for early rehabilitation.

2. Methodology

The University of Ain Shams Institutional Ethics Board reviewed and approved this prospective, randomized, double-blinded clinical study (No. FMASU R 143/2021), and the study was registered with Clinicaltrials.gov (No. NCT05010499). Every patient signed a written informed consent. The study was conducted from July 28, 2021 to December 30, 2021.

Using PASS software version 11. NCSS, LLC. Kaysville, Utah, USA (Hintze, 2011). A sample size of 22 in each group satisfies an equivalence test with

equivalence limits ± 1 using two one-sided tests at power = 0.80 and $\alpha = 0.05$, when VAS of pain at hour 36 means $\pm 95\%$ CI for FICB and FNB groups was 1.8 ± 0.4 and 2.1 ± 0.3 respectively (McMeniman, et al.)¹². We raised the sample size to 30 in each group for possible attrition.

We enrolled sixty patients who were undergoing elective hip arthroscopy and were of either sex, between the ages of 2–65 y, with an ASA physical status of I or II and a BMI less than 30 kg/m².

Exclusion criteria included patients who refused to participate in the study, infection at the injection site, femoral artery aneurysm, coagulation profile abnormalities, patients who had emergency surgery, or patients scheduled for complicated surgeries, history of neuromuscular disease or polyneuropathy, and those who had known allergy to levobupivacaine. The method used for randomization and patient allocation involved sealed, opaque, sequentially-numbered envelopes.

A single shot block was administered to eligible patients after GA according to the group allocation. The regional blocks were carried out by an experienced anesthetist who was not blinded to the study's objectives and who also prepared the drug mixtures.

After the consent and explanation of the steps of the research, all patients had a routine pre-anesthetic assessment on the day before surgery and were informed about the usage of VAS.

Peripheral cannulation was performed with an 18-G catheter in the patient's hand upon entry to the operating room, and standard monitoring was set up and readings of SpO₂, mean blood pressure (MBP), and heart rate (HR) were recorded.

Ringer's solution of 10 mL/kg was infused to all patients. General anesthesia was induced in the form of preoxygenation using O₂/air mixture (FiO₂ = 0.8) for 3–5 min, fentanyl 1–2 µg/kg IV, followed by slow injection of propofol 1.5–2 mg/kg until the loss of verbal communication with the patient. Then cis-atracurium 0.2 mg/kg IV was injected to facilitate muscle relaxation and endotracheal intubation. After securing the endotracheal tube in place, end-tidal carbon dioxide (EtCO₂) measurement using capnography was connected, and the appropriate ventilation parameters were used to keep normal EtCO₂. Isoflurane 1.5–2 MAC was used for maintenance of GA. Cis-atracurium was injected at 0.02 mg/kg according to nerve stimulator monitoring.

Intraoperatively, monitoring of the anesthetic depth was mediated by Root® with Next Generation SedLine® Brain Function Monitor (Masimo™), with a processed EEG parameter; patient state index (PSi), and maintained at a value of 25–50.

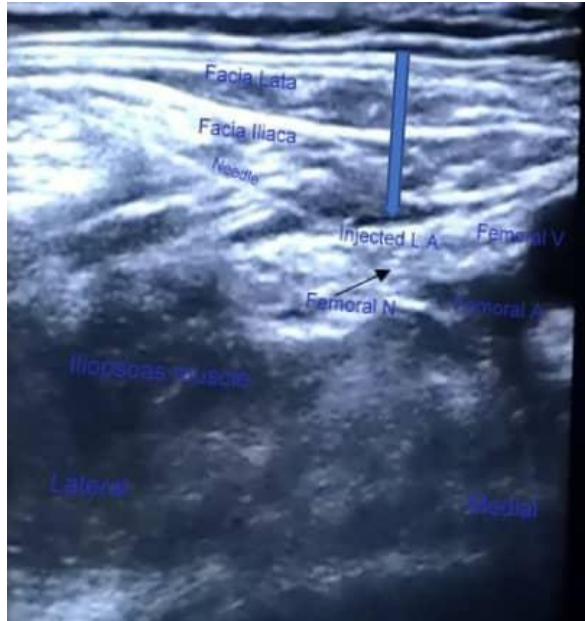


Figure 1: Ultrasound scan of fascia iliaca compartment block

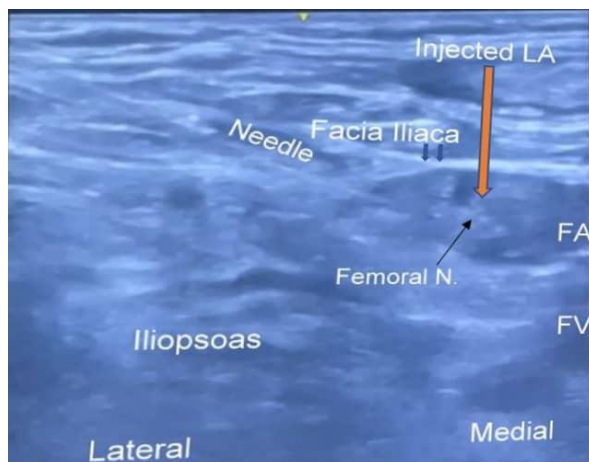


Figure 2: US scan of US-guided femoral nerve block.

According to the block technique patients were divided into two groups. In Group FICB the femoral artery, fascia iliaca, and iliopsoas muscle were visualized using a sterilized US high-frequency linear transducer (8–12 MHz) (model USAP-770A; Toshiba™, Tokyo, Japan) after GA induction and with the patient lying supine. The sartorius muscle was visible after lateral scanning of the fascia iliaca.

In order to achieve a proper block, an echogenic needle (Pajunk Sonoplex®; 20GX120mm, Germany) was advanced in-plane from lateral to medial direction. Following a negative aspiration, 40 mL of 0.25% levobupivacaine was injected beneath the fascia iliaca

after 1–2 mL of normal saline were first injected to confirm the correct injection plane between the fascia and the iliopsoas muscle. The success of the nerve block was expected by visualizing the spread of local anesthetic toward the FN medially and deep to the sartorius muscle laterally (Figures 1 & 2)..

In Group FNB the skin over the femoral crease was disinfected and a sterilized US high-frequency linear transducer (8–12MHz) was used to view the femoral artery and vein covered by fascia iliaca while the patient was in the supine position following the induction of GA. The FN typically appears as a spindle-shaped structure lateral to the artery and deep to the fascia iliaca. An echogenic needle was inserted lateral to the outer edge of the US probe using an in-plane technique. The sartorius muscle was penetrated deep to the fascia iliaca by the needle as it was moved from lateral to medially until it was just lateral to the FN. Levobupivacaine 0.25% 20 ml was then injected after confirming proper needle position by injecting 1–2 mL of normal saline. Nerve stimulator was not used in conjunction with US as patients were given a muscle relaxant.

After performing either block, patients were carefully and gradually placed in the optimum surgical position. The HR, MBP, and SpO₂ were monitored during patient positioning to prevent significant adverse events.

At the end of the surgery, suction of oral secretions was done, and neuromuscular blockade was reversed after full recovery of neuromuscular function. Extubation was done after recovery of awareness and the T4/T1 ratio to be 90%.

Patients were moved to the post-anesthesia care unit (PACU) once they had fully recovered, where a blinded observer anesthesiologist used a VAS (ranging from 0–10 cm: where 0 = no pain, 10 = worst pain) to record the patients' pain levels. If the VAS was greater than 4, the first rescue analgesic was administered in the form of pethidine 25 mg IV. Total amount of pethidine consumed was measured hourly for the first four hours following surgery, then every four hours for the next 8 h, and then at 24 h postoperatively.

Early ambulation was evaluated with the quadriceps femoris muscle's power, which was tested by the patient's capacity to stand unassisted.

The primary outcome was the time to the first analgesic requirement; whereas the secondary outcomes were the total pethidine consumption in the first 24 h postoperatively, the VAS scores, and the time to postoperative ambulation.

Statistical analysis

The blinded data were coded and analyzed using statistical software SPSS (Statistical Package for Social Sciences) version 22.0, IBM Corp., Chicago, USA,

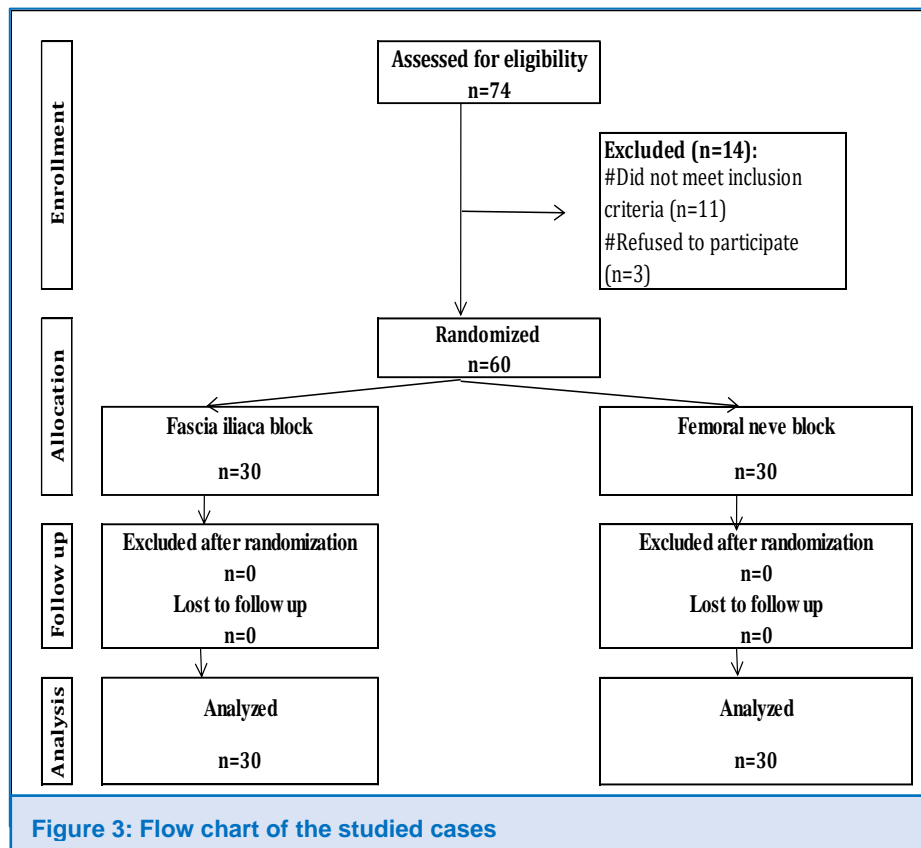


Figure 3: Flow chart of the studied cases

2013. Descriptive statistics were done for normally distributed quantitative data as mean \pm SD (standard deviation), while it was done for categorical data as numbers and percentages. Inferential analyses were done for quantitative variables using the Shapiro-Wilk test for normality testing, an independent t-test in cases of two independent groups with normally distributed data. In qualitative data, inferential analyses for independent variables were done using the Chi-square test for differences between proportions and Fisher's Exact test for variables with small expected numbers. The long Rank test was used to compare rates. $P < 0.050$ was considered significant.

3. Results

A total of 74 patients were scheduled for surgical hip arthroscopy, out of which 11 patients were excluded because they did not fulfill the inclusion criteria, and 3 patients refused to participate in the study. Finally, 60 patients were included in this study. All patients received general anesthesia and were randomly allocated into 2 groups (30 patients in each group) according to the

adjuvant nerve block given for postoperative analgesia (Figure 3).

There was no significant difference between the 2 groups regarding demographic data (age, sex, BMI, ASA), baseline characteristics, and type of surgery (Table 1). Time to ambulation was significantly earlier in the Group FICB (Table 2; Figure 4). Pain perception was lower and time to rescue analgesia was delayed in the Group FICB, but the differences were with statistically non-significant. Rescue analgesia was less frequent in the Group FICB (Figure 5).

4. Discussion

This prospective, randomized study tried to compare the effect of FICB

and FNB in the intra- and postoperative period in patients undergoing hip arthroscopy as regards pain control, motor power, and early ambulation.

In the current study, the combination of GA and US-guided FICB or FNB had a similar effect in decreasing postoperative pain. However, FICB was superior to FNB regarding the preservation of motor power (quadriceps muscle strength) and early ambulation. Our findings are in agreement with McMeniman et al.¹² who reported

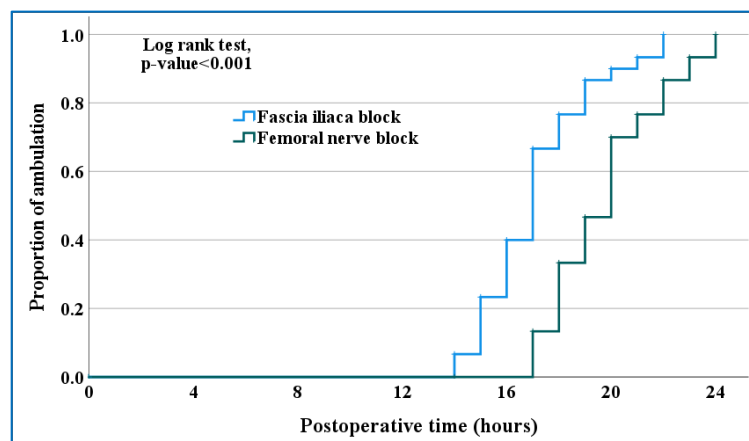
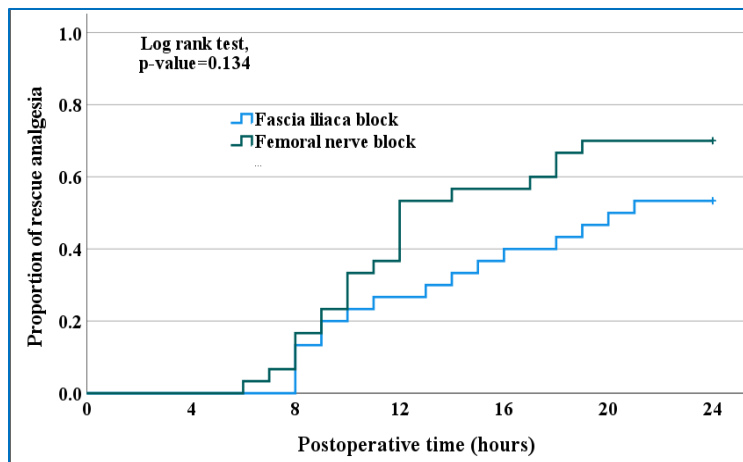


Figure 4: Kaplan Meier curve for postoperative ambulation

Table 1: Comparative demographic and baseline characteristics

Variables	Fascia iliaca block (N = 30)	Femoral nerve block (N = 30)	P-value
Age (y)	44.4 ± 7.1	45.8 ± 7.2	^0.431
Gender			
Male	16 (53.3)	19 (63.3)	#0.432
Female	14 (46.7)	11 (36.7)	
BMI (kg/m ²)	27.0 ± 1.8	27.2 ± 1.8	^0.732
Hypertension	2 (6.7)	4 (13.3)	§0.671
Diabetes mellitus	2 (6.7)	3 (10.0)	§0.999
Bronchial asthma	2 (6.7)	1 (3.3)	§0.999
Femoroacetabular impingement	8 (26.7)	6 (20.0)	#0.761
Type of surgery			
Anterior inferior iliac spine decompression	9 (30.0)	10 (33.3)	§0.974
Synovectomy	8 (26.7)	7 (23.3)	
Femoral osteotomy	6 (20.0)	5 (16.7)	
Lengthening of iliotibial band	2 (6.7)	4 (13.3)	
Femoral chondroplasty	3 (10.0)	2 (6.7)	
Acetabular chondroplasty	2 (6.7)	2 (6.7)	

^Independent t-test. #Chi square test. §Fisher's Exact test
Data presented as Mean ± SD or n (%)

**Figure 5: Kaplan Meier curve for first rescue analgesia**

postoperative low pain scores in both groups of patients who received FNB and FICB after total knee replacement. McMeniman et al. did not examine the effect of nerve blocks on motor power, however, in our study, the group of FNB experienced motor weakness and delayed time to ambulation.

Arthroscopic procedures for hip joint diseases are increasingly performed as ambulatory procedures. GA is

safe and effective for arthroscopic hip interventions but unfortunately, it is associated with increased postoperative pain. Multiple analgesic regimens have been developed for effective postoperative pain control. These modalities include lumbar plexus block (LPB), FNB, FICB, and intra- and periarticular injection of local anesthetic.^{13,14}

Causes of postoperative pain experienced by patients after hip arthroscopy include leg traction, prolonged over distension of the joint capsule, extravasation of fluid to the nearby tissues, uncorrected pathology in the joint, the type of procedure performed, surgical trauma after the procedure, and the patient profile.¹⁵

Several studies have illustrated that specific nerve blocks induced sufficient analgesic effects with subsequent reduction of postoperative opioid consumption. However, FNB has been linked to an increased incidence of postoperative falls, femoral nerve injury and neuritis, and occasionally intravascular injection.¹⁶

LPB is an effective block for postoperative pain control; however, it may be associated with serious

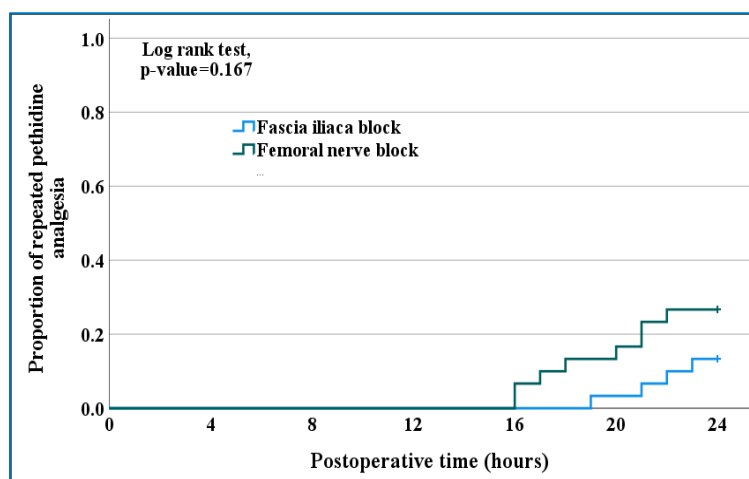
Table 2: Comparison according to postoperative ambulation, pain perception, and analgesia

Variables	Fascia iliaca block (N=30)	Femoral nerve block (N=30)	p-value	Effect of FICB relative to FNB	
				Mean ± SE	95% CI
Ambulation time (h)	17.2 ± 2.1	19.8 ± 2.1	^<0.001*	-2.6 ± 0.5	-3.7– -1.5
Postoperative pain perception (VAS-10), Mean ± SD					
H-1	0.4 ± 0.5	0.5 ± 0.5	^0.612	-0.1 ± 0.1	-0.3–0.2
H-2	0.8 ± 0.6	0.9 ± 0.4	^0.612	-0.1 ± 0.1	-0.3–0.2
H-3	1.1 ± 0.5	1.4 ± 0.7	^0.089	-0.3 ± 0.2	-0.6–0.0
H-4	1.3 ± 0.4	1.5 ± 0.6	^0.064	-0.3 ± 0.1	-0.5–0.0
H-8	2.8 ± 1.1	3.2 ± 1.1	^0.174	-0.4 ± 0.3	-1.0–0.2
H-12	3.8 ± 0.8	4.2 ± 0.9	0.054	-0.4 ± 0.2	-0.9–0.0
H-24	2.7 ± 0.9	3.2 ± 1.4	^0.107	-0.5 ± 0.3	-1.1–0.1
Analgesia					
Variable	Fascia iliaca block (N=30)	Femoral nerve block (N=30)	p-value	RR	95% CI
Rescue analgesia (pethidine)	16 (53.3%)	21 (70.0%)	#0.184	0.76	0.51–1.15
Repeated pethidine analgesia	4 (13.3%)	8 (26.7%)	#0.197	0.50	0.17–1.48
Time to 1 st rescue analgesia (h)	12.9 ± 4.7	11.5 ± 3.8	^0.318	1.4 ± 1.4	-1.4–4.2
Time to repeat pethidine (h)	21.3 ± 1.7	18.9 ± 2.4	^0.112	2.4 ± 1.4	-0.7–5.4
^Independent t-test. #Chi square test. *Significant. RR: Relative risk. CI: Confidence interval					

complications such as epidural spread, retroperitoneal hematoma, and renal injury.¹⁷

The FICB induces anesthesia of the anterior, lateral, and medial aspects of the thigh, as it blocks the femoral,

lateral cutaneous femoral nerve and obturator nerve. FICB avoids possible complications of the FNB by blocking the FN away from the major neurovascular structures, thereby minimizing the risk of complications related to nerve damage.¹⁸

**Figure 6: Kaplan Meier curve for repeated pethidine analgesia**

Our study found that patients who received FICB had non-significant lower VAS than patients who received FNB, as a result, Rescue analgesia statistically was non-significantly less frequent in the Group FICB and time to rescue analgesia statistically was non-significantly longer in the Group FICB.

Our results in group FICB are in agreement with Krych et al., who studied the efficacy of the FICB for acute pain management following hip arthroscopy and concluded that there was a significant reduction in postoperative pain, low opioid consumption as well as increased patient satisfaction.¹⁹ On the other hand, in a systematic review, Smith JH et al. concluded that FICB in patients undergoing hip arthroscopy was not superior

to other forms of analgesics in the immediate postoperative period. Therefore, it is not recommended as a part of multimodal analgesia hip arthroscopies.²⁰

Garner et al. reported that local anesthetic infiltration after hip arthroscopy had better analgesia and reduced opioid consumption and a lower rate of side effects when compared with FICB. The authors explained these results that FICB failed to control pain in the posterior aspect of the hip capsule, which is innervated by the sacral plexus and escaped the FICB.²¹ Also, Golmest et al. found that US-guided FICB for hip arthroscopy did not provide any clinical advantage when compared with intra-articular local anesthetic injection.²²

In another study, Blackwell et al. reported that patients receiving quadratus lumborum block for hip arthroscopy experienced lower total opioid consumption, shorter PACU stays, and lower pain scores at discharge than patients receiving preoperative FICB without adverse events.²³

In this study, we found that the time to early ambulation was significantly shorter in the Group FICB than in the Group FNB.

A potential side effect of peripheral nerve blocks of the lower extremity is a motor weakness that could increase the risk for postoperative falls. Xing et al. found that FNBs can improve postoperative pain early after hip arthroscopy, but at the same time, the study demonstrated an increase in the risk of postoperative falls in this group.²⁴ YaDeau et al. reported that LPB had statistically significant reductions in PACU resting pain after hip arthroscopy, no improvements in analgesia in hip arthroscopy in patients who received preoperative LPB when compared to control patients, and increased the risk of postoperative falls. Lower-extremity nerve blocks that affect the FN can result in quadriceps weakness.²⁵

5. Limitation of the study

The current study was a single-center study, so multi-center studies are believed to provide us with more accurate results, especially with a larger number of patients involved in the study giving more reliable results.

6. Conclusion

Both US-guided fascia iliaca compartment block and femoral nerve block were effective in reducing postoperative pain and were easy to perform in hip arthroscopy. However, fascia iliaca compartment block was associated with early ambulation and preservation of motor power.

7. Clinical trial registration.

The study was registered with ClinicalTrials.gov ID: NCT05010499

8. Conflict of Interests

No conflict of interest was declared by the authors. No funding, either internal or external, was involved in this study.

9. Ethical Approval

This prospective, randomized, double-blinded clinical study was approved by the University of Ain Shams Institutional ethics board review (FMASU R 143/2021).

10. Data availability

The numerical data is available with the corresponding author and can be provided on request.

12. Authors' Contribution

AA: data acquisition and analysis

AA, MM, ME, MM: Designed the study protocol; Literature search; Manuscript drafting

All authors provided revision for intellectual content and final approval of the manuscript.

References

- Ganz R, Parvizi J, Beck M, Leunig M, Nötzli H, Siebenrock KA. Femoroacetabular impingement: a cause for osteoarthritis of the hip. *Clin Orthop Relat Res.* 2003;(417):112–20. [PubMed] DOI: [10.1097/01.blo.0000096804.78689.c2](https://doi.org/10.1097/01.blo.0000096804.78689.c2)
- Griffin DR, Dickenson EJ, O'Donnell J, Agricola R, Awan T, Beck M, et al. The Warwick Agreement on femoroacetabular impingement syndrome (FAI syndrome): an international consensus statement. *Br J Sports Med.* 2016;50(19):1169–76. [PubMed] DOI: [10.1136/bjsports-2016-096743](https://doi.org/10.1136/bjsports-2016-096743)
- Sampson TG. Arthroscopic treatment of femoroacetabular impingement. *Am J Orthop (Belle Mead NJ).* 2008;37(12):608–12. [PubMed]
- Matsuda DK, Carlisle JC, Arthurs SC, Wierks CH, Philippon MJ. A comparative systematic review of the open dislocation, mini-open, and arthroscopic surgeries for femoroacetabular impingement. *Arthroscopy.* 2011 Feb;27(2):252–69. [PubMed] DOI: [10.1016/j.arthro.2010.09.011](https://doi.org/10.1016/j.arthro.2010.09.011)
- Hargett MJ, Beckman JD, Liguori GA, Neal JM; Education Committee in the Department of Anesthesiology at Hospital for Special Surgery. Guidelines for regional anesthesia fellowship training. *Reg Anesth Pain Med.* 2005;30(3):218–25. [PubMed] DOI: [10.1016/j.rapm.2005.02.008](https://doi.org/10.1016/j.rapm.2005.02.008)
- Szucs S, Morau D, Iohom G. Femoral nerve blockade. *Med Ultrason.* 2010 ;12(2):139–44. [PubMed]
- Dalens B, Vanneville G, Tanguy A. Comparison of the fascia iliaca compartment block with the 3-in-1 block in children. *Anesth Analg.* 1989;69(6):705–13. [PubMed]
- Kaloul I, Guay J, Côté C, Fallaha M. The posterior lumbar plexus (psoas compartment) block and the three-in-one femoral nerve block provide similar postoperative analgesia after total knee

- replacement. *Can J Anaesth*. 2004;51(1):45–51. [PubMed] DOI: [10.1007/BF03018546](https://doi.org/10.1007/BF03018546)
9. Murgatroyd H, Forero M, Chin KJ. The efficacy of ultrasound-guided fascia iliaca block in hip surgery: a question of technique? *Reg Anesth Pain Med*. 2013 Sep-;38(5):459–60. [PubMed] DOI: [10.1097/AAP.0b013e31829d27fa](https://doi.org/10.1097/AAP.0b013e31829d27fa)
 10. Duellman TJ, Gaffigan C, Milbrandt JC, Allan DG. Multi-modal, pre-emptive analgesia decreases the length of hospital stay following total joint arthroplasty. *Orthopedics*. 2009;32(3):167. [PubMed]
 11. Bendtsen TF, Moriggl B, Chan V, Børglum J. The Optimal Analgesic Block for Total Knee Arthroplasty. *Reg Anesth Pain Med*. 2016;41(6):711–719. [PubMed] DOI: [10.1097/AAP.0000000000000485](https://doi.org/10.1097/AAP.0000000000000485)
 12. Brisbane Orthopaedic & Sports Medicine Centre Writing Committee, McMeniman TJ, McMeniman PJ, Myers PT, Hayes DA, Cavdarski A, Wong MS, et al. Femoral nerve block vs fascia iliaca block for total knee arthroplasty postoperative pain control: a prospective, randomized controlled trial. *J Arthroplasty*. 2010;25(8):1246–9. [PubMed] DOI: [10.1016/j.arth.2009.11.018](https://doi.org/10.1016/j.arth.2009.11.018)
 13. Schroeder KM, Donnelly MJ, Anderson BM, Ford MP, Keene JS. The analgesic impact of preoperative lumbar plexus blocks for hip arthroscopy. A retrospective review. *Hip Int*. 2013;23(1):93–8. [PubMed] DOI: [10.5301/HIP.2013.10613](https://doi.org/10.5301/HIP.2013.10613)
 14. Baker JF, McGuire CM, Byrne DP, Hunter K, Eustace N, Mulhall KJ. Analgesic control after hip arthroscopy: a randomized, double-blinded trial comparing portal with intra-articular infiltration of bupivacaine. *Hip Int*. 2011 May–Jun;21(3):373–7. [PubMed] DOI: [10.5301/HIP.2011.8390](https://doi.org/10.5301/HIP.2011.8390)
 15. Sardesai AM, Garner M, Khanduja V. Editorial Commentary: Pain After Hip Arthroscopy-Are We Truly Addressing the Problem? *Arthroscopy*. 2020;36(4):1045–1047. [PubMed] DOI: [10.1016/j.arthro.2020.02.013](https://doi.org/10.1016/j.arthro.2020.02.013)
 16. Childs S, Pyne S, Nandra K, Bakhsh W, Mustafa SA, Giordano BD. The Effect of Intra-articular Cocktail Versus Femoral Nerve Block for Patients Undergoing Hip Arthroscopy. *Arthroscopy*. 2017;33(12):2170–2176. [PubMed] DOI: [10.1016/j.arthro.2017.06.036](https://doi.org/10.1016/j.arthro.2017.06.036)
 17. Yuan L, Xu C, Zhang Y, Wang G. Comparative efficacy analysis of ultrasound-guided quadratus lumborum block and lumbar plexus block in hip arthroscopy: a pilot prospective randomized controlled trial. *J Hip Preserv Surg*. 2022;9(2):119–125. [PubMed] DOI: [10.1093/jhps/hnac020](https://doi.org/10.1093/jhps/hnac020)
 18. Dai W, Leng X, Hu X, Cheng J, Ao Y. The effect of fascia iliaca block on postoperative pain and analgesic consumption for patients undergoing primary total hip arthroplasty: a meta-analysis of randomized controlled trials. *J Orthop Surg Res*. 2021 Jul 9;16(1):444. [PubMed] DOI: [10.1186/s13018-021-02585-1](https://doi.org/10.1186/s13018-021-02585-1)
 19. Krych AJ, Baran S, Kuzma SA, Smith HM, Johnson RL, Levy BA. Utility of multimodal analgesia with fascia iliaca blockade for acute pain management following hip arthroscopy. *Knee Surg Sports Traumatol Arthrosc*. 2014;22(4):843–7. [PubMed] DOI: [10.1007/s00167-013-2665-y](https://doi.org/10.1007/s00167-013-2665-y)
 20. Smith JH, Kraeutler MJ, Keeling LE, Scillia AJ, McCarty EC, Meidan O. Fascia Iliaca Block for Postoperative Pain Control After Hip Arthroscopy: A Systematic Review of Randomized Controlled Trials. *Am J Sports Med*. 2021;49(14):4042–4049. [PubMed] DOI: [10.1177/0363546521996713](https://doi.org/10.1177/0363546521996713)
 21. Garner M, Alshameeri Z, Sardesai A, Khanduja V. A Prospective Randomized Controlled Trial Comparing the Efficacy of Fascia Iliaca Compartment Block Versus Local Anesthetic Infiltration After Hip Arthroscopic Surgery. *Arthroscopy*. 2017;33(1):125–132. [PubMed] DOI: [10.1016/j.arthro.2016.10.010](https://doi.org/10.1016/j.arthro.2016.10.010)
 22. Glomset JL, Kim E, Turkish JM, Renfro SD, Seckel TB, Adams KJ, et al. Reduction of Postoperative Hip Arthroscopy Pain with an Ultrasound-Guided Fascia Iliaca Block: A Prospective Randomized Controlled Trial. *Am J Sports Med*. 2020 Mar;48(3):682–688. [PubMed] DOI: [10.1177/0363546519898205](https://doi.org/10.1177/0363546519898205)
 23. Blackwell RE, Kushelev M, Norton J, Pettit R, Vasileff WK. A Comparative Analysis of the Quadratus Lumborum Block Versus Femoral Nerve and Fascia Iliaca Blocks in Hip Arthroscopy. *Arthrosc Sports Med Rehabil*. 2020;3(1):e7–e13. [PubMed] DOI: [10.1016/j.asmr.2020.08.002](https://doi.org/10.1016/j.asmr.2020.08.002)
 24. Xing JG, Abdallah FW, Brull R, Oldfield S, Dold A, Murnaghan ML, et al. Preoperative Femoral Nerve Block for Hip Arthroscopy: A Randomized, Triple-Masked Controlled Trial. *Am J Sports Med*. 2015;43(11):2680–7. [PubMed] DOI: [10.1177/0363546515602468](https://doi.org/10.1177/0363546515602468)
 25. YaDeau JT, Tedore T, Goytizolo EA, Kim DH, Green DS, Westrick A, et al. Lumbar plexus blockade reduces pain after hip arthroscopy: a prospective randomized controlled trial. *Anesth Analg*. 2012;115(4):968–72. [PubMed] DOI: [10.1213/ANE.0b013e318265bacd](https://doi.org/10.1213/ANE.0b013e318265bacd)