

## CASE REPORT

## CORONA EXPERIENCE

# Ipsilateral axillary lymphadenopathy after COVID-19 vaccination in a young female; a case report and literature review

Maryam Naseer Butt<sup>1</sup>, Wajida Perveen<sup>2</sup>, Sarosh Malik<sup>3</sup>, Sohail Khan Raja<sup>4</sup>, Rabia Feroz<sup>5</sup>, Roha Asif<sup>6</sup>

**Author affiliation:**

1. Maryam Naseer Butt, DPT, MS-NMPT, Physiotherapist at Muzaffarabad Physical Rehabilitation Centre, Muzaffarabad, AJK; E-mail: [mbutt\\_ajk@yahoo.com](mailto:mbutt_ajk@yahoo.com)
2. Wajida Perveen, BSc (Physiotherapy), t-DPT, MS-OMPT, CRCP, CMT, CMP, CME, PhD Scholar, Associate Professor & HOD, Institute of Dentistry, CMH Lahore Medical College, Lahore, Pakistan; E-mail: [wjda\\_noor@yahoo.com](mailto:wjda_noor@yahoo.com); ORCID: {0000-0002-4833-0928}
3. Sarosh Malik, PhD (Biochemistry), Senior Lecturer at UIRSMIT (FAHS), The University of Lahore, Lahore; E-mail: [saroshmalik12@gmail.com](mailto:saroshmalik12@gmail.com); ORCID: {0000-0002-5186-906X}
4. Sohail Khan Raja, Assistant Professor, Pulmonology Department, AJK Medical College, Muzaffarabad. AJK; E-mail: [drsohailraja@gmail.com](mailto:drsohailraja@gmail.com); Ph: +92-3125609119
5. Rabia Feroz, MBBS, FCPS, Radiologist, CMH Muzaffarabad, AJK; E-mail: [sirius\\_rob@yahoo.com](mailto:sirius_rob@yahoo.com);
6. Roha Asif, MPhil, PhD scholar (Biochemistry), Assistant Professor/ HOD, Biochemistry Department, Sialkot College of Physical Therapy, Amin Welfare & Teaching Hospital, Sialkot, Pakistan; E-mail: [rohachughtai@gmail.com](mailto:rohachughtai@gmail.com); ORCID: {0000-0002-7398-0420}

**Correspondence:** Wajida Perveen; E-mail: [wjda\\_noor@yahoo.com](mailto:wjda_noor@yahoo.com); Ph: +92-333-3507157

## Abstract

It has been two years since vaccination for COVID-19 was launched worldwide. In Pakistan, the vaccination started in the beginning of 2020. Since then, several side effects were reported after vaccination, including soreness of the arm, fever, chills, malaise and diarrhoea. Axillary lymphadenopathy has been found to be associated with several conditions that include autoimmune disorders, infections, malignancy and some idiopathic causes. We present a rare case of a 30-y old female with recent recovery from COVID-19, who developed ipsilateral axillary lymphadenopathy after 15 days of Sinovac vaccination. Ultrasonography was done to confirm the diagnosis and its spread towards breast and cervical region. This case report discusses some key points and recommendations regarding unilateral axillary lymphadenopathy after COVID-19 vaccination.

**Key words:** COVID-19; Lymphadenopathy; Vaccination; Pakistan

**Citation:** Butt MN, Perveen W, Malik S, Raja SK, Feroz R, Asif R. Ipsilateral axillary lymphadenopathy after COVID-19 vaccination in a young female; a case report and literature review. *Anaesth. pain intensive care* 2022;26(6):820-823. DOI: [10.35975/apic.v26i6.2066](https://doi.org/10.35975/apic.v26i6.2066)

**Received:** July 16, 2022; **Reviewed:** August 28, 2022; **Accepted:** September 23, 2022

## 1. Introduction

We are living in the era of the pandemic COVID-19, which was first reported in Wuhan China. On January 30, 2020 the World Health Organization declared it as a public health emergency and by March 2020, it became a pandemic.<sup>1</sup> The virus is SARS-CoV-2 is an enveloped and positive single-stranded RNA virus.<sup>2</sup> The virus mainly affects respiratory system but can also affect

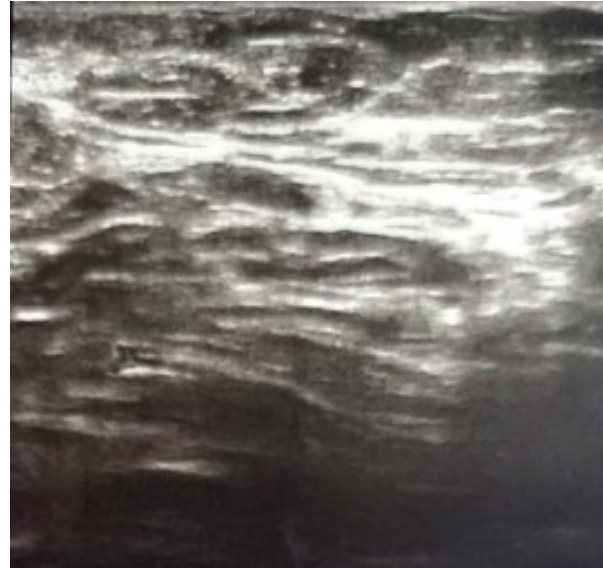
other systems including enteric, hepatic and neurological system.<sup>3</sup> The common symptoms of COVID-19 are fever, cough (mostly dry but can be productive), body aches and loss of sense of taste and smell. The less common symptoms include sore throat, headaches, diarrhoea, malaise, skin rashes and irritated eyes. The more serious symptoms include chest pain and difficult breathing which require urgent medical attention. The

virus transfers from human to human via airborne droplets by coughing and sneezing. There is no treatment of COVID-19 but several studies have been published regarding the use of anti-viral drugs and their effects on the disease progression and prevention.<sup>4,5</sup> Scientists started working on the preparation of vaccines since the outbreak of this pandemic and several vaccines have been marketed so far. The first clinical trial of vaccination in human was conducted in March, 2020 in United States and as of May, 2021 corona vaccination started in Pakistan.<sup>6</sup> These vaccines included AstraZeneca, Sputnik V, CoronaVac, Moderna/NIAID, and BBIBP-CorV etc.<sup>6</sup> Vaccinations of COVID-19 have several side effects that include fever, malaise, diarrhoea, nausea and pain on injection site. Lymphadenopathy has not been reported as side effect to vaccination. But some studies reported it in some vaccination settings.<sup>7-9</sup> Therefore, healthcare professional working in general surgery, radiology and oncology must consider history of recent COVID-19 vaccine as a possible differential diagnosis for the patients with unilateral axillary lymphadenopathy.

## 2. Case Report

A 30 years old unmarried female presented with pain in left axilla, lateral region of her left breast and infra clavicular region in general surgery department. On examination there were palpable swollen lumps found in the axilla with grade 1 tenderness. Thyroid was palpable but not swollen. There was no history of any systemic disease. The detailed history highlighted COVID-19 vaccination with Sinovac received on September 18, 2021 (2 weeks before the onset of symptoms and one week after the end of her menstrual cycle) on ipsilateral site of symptoms. A day after the first shot of the vaccination in the left arm, she started experiencing headache (migraine), nausea, perennial cramps and malaise.

Patient was a known case of migraine, allergic rhinitis and Raynaud's phenomenon. She had a history of hyperthyroidism, bronchitis, dengue fever and COVID-19 (+ve PCR test). She had been taking multivitamins (vitamin B complex, vitamin C, zinc and folic acid) after suffering from COVID-19. For palpable swollen lymph nodes, she was advised ultrasound scan. On ultrasonography, there were multiple large nodes, the largest one measured 26 mm in size and an intact hilum. No similar finding was detected in left breast and infra and supraclavicular regions. Pain was settled after 2 days of medication with clarithromycin 250 mg BID, mefenamic acid 500 mg BID and esomeprazole 40 mg OD. The second shot of vaccine was taken on October 30, 2021 (A week before her menstrual cycle) delayed due to influenza. The second shot was also taken on the left arm. A day after the second shot of vaccination she



**Figure 1: Scan image of axillary nodes after second dose of vaccine**

started to experience headache (migraine), nausea, perennial cramps and malaise. No pain in axillary region or in left breast or infra clavicular region was reported. A follow up ultrasound was done after 2 weeks of second dose; no swollen lymph nodes were detected in any of the previously mentioned regions.

## 3. Discussion

In the past, axillary lymphadenopathy has been reported after several vaccinations that includes seasonal influenza, bacillus Calmette-Guérin, human papillomavirus, and H1N1.<sup>8]</sup> Lymphadenopathy can develop as early as one day,<sup>10</sup> and as late as one month, following the vaccinations.<sup>11</sup> The first case of post-corona vaccination unilateral axillary lymphadenopathy was reported in January 2021 and it was incidental finding in two women that were actually screened for breast masses using ultrasound.<sup>7,8</sup> As COVID-19 vaccines are highly immunogenic in their clinical response in patients, it is very likely to predict the presence of unilateral axillary lymphadenopathy following COVID-19 vaccinations.<sup>8,12</sup> In a recent study it has been reported that axillary lymph node swelling was found in 45.8% of included patients, ipsilateral to the site of injection following COVID-19 vaccination that included including Pfizer/BioNTech BNT162b2 mRNA vaccine, the AstraZeneca ChAdOx1.<sup>13</sup>

Our study highlights the occurrence of axillary lymphadenopathy ipsilateral to the site of injection following Sinovac (CoronaVac) vaccine after almost 15 days. In another study of 37 year old female who presented with palpable lymph nodes in left supraclavicular and left axillary region with the history

of recent Moderna vaccine (mRNA-1273) first dose on ipsilateral side 12 days ago.<sup>14</sup> Another recent study conducted at University of California found that females presenting to the department of radiology for screening and diagnostic breast imaging developed axillary adenopathy after 10 days of COVID-19 vaccination (Pfizer-BioNTech or Moderna) ipsilateral to the site of injection.<sup>15</sup> It was an incidental finding in breast imaging.<sup>15</sup> They found that largest lymph node was only 6 mm in size.<sup>15</sup> In our case study, the maximum size of the largest lymph node was 26 mm. In a recent report of 3 cases who developed axillary lymphadenopathy following mRNA COVID-19 vaccine ipsilateral to the site of injection.<sup>16</sup> Two of them had incidental finding of axillary lymphadenopathy while they were actually on routine appointment for breast cancer imaging and recently had their vaccination.<sup>16</sup> Another study presented the cases of 4 females who were on their routine follow-up of breast cancer screening and had history of recent vaccination with Pfizer-BioNTech COVID-19 vaccine.<sup>7</sup> Three of the four females had no family history of cancer and all of them had no personal history of cancer. They all developed axillary lymphadenopathy ipsilateral to the site of injection of COVID-19 vaccine.<sup>7</sup> Another paper presented the case of 3 patients who developed the lymphadenopathy (supraclavicular, infraclavicular and axillary) following Pfizer-BioNTech COVID-19 vaccine.<sup>17</sup> One of these cases was on routine follow up of breast screening for cancer.<sup>17</sup> In most of the studies Pfizer-BioNTech COVID-19 vaccine is reported to cause the axillary lymphadenopathy than other COVID-19 vaccines. None of the study reported Sinovac (CoronaVac) vaccine as a potential cause of axillary lymphadenopathy.

Although malignancy remains the top priority while dealing with unexplained lymphadenopathy, but it is recommended that COVID-19 vaccine should be considered as one of the differential diagnosis even in patients with positive history of cancer. It is also recommended that there should be good interdisciplinary cooperation between oncologist, radiologist and the healthcare workers working in COVID-19 setting. Data about the vaccination record of all the patients presenting to oncology department should be shared in order to have better understanding of incidental findings while cancer screening. Before breast screening for cancer and biopsy, short history about COVID-19 vaccination must be taken in order to avoid erroneous diagnosis of metastatic nodal disease.

## 4. Conclusion

COVID-19 vaccination can be one of the causes of acute axillary lymphadenopathy in the absence of any other systemic illness. This case study provides information about the possibility of unilateral axillary

lymphadenopathy in Sinovac (CoronaVac) COVID-19 vaccine setting.

Guidelines should be formed to appropriately manage the lymphadenopathy detected in oncology and radiology department during cancer screening of patients with and without family or personal history of cancer to avoid unnecessary biopsies and tests for cancer.

## 5. Conflict of interest

None declared by the authors.

## 6. Patients consent

Written consent was given by the patient, who happens to be the first author of her own case report.

## 7. Author contribution

MNB: Conception and manuscript writing.

WP: Conception and design.

SM: Manuscript drafting & revision.

SKR: conduct of study work.

RF: Final approval.

RA: Manuscript editing.

## 8. References

- GÜNER, H.R., İ. Hasanoğlu, and F. Aktaş, COVID-19: Prevention and control measures in community. *Turkish Journal of medical sciences*, 2020. 50(SI-1):571-577. [PubMed]
- Velavan, T.P. and C.G. Meyer, The COVID-19 epidemic. *Tropical medicine & international health*, 2020. 25(3):278. [Free Full Text]
- He, F., Y. Deg, and W. Li, Coronavirus disease 2019: What we know? *Journal of medical virology*, 2020. 92(7):719-725. [Free Full Text]
- Yavuz, S. and S. Ünal, Antiviral treatment of COVID-19. *Turkish Journal of medical sciences*, 2020. 50(9):611-619. [PubMed]
- Fischer, W.A., et al., Molnupiravir, an oral antiviral treatment for COVID-19. *medRxiv*, 2021. DOI: 10.1101/2021.06.17.21258639
- Perveen, S., et al., Vaccination-hesitancy and vaccination-inequality as challenges in Pakistan's COVID-19 response. *Journal of community psychology*, 2021. [PubMed]
- Mehta, N., et al., Unilateral axillary Adenopathy in the setting of COVID-19 vaccine. *Clinical imaging*, 2021. 75:12-15. DOI: 10.1016/j.clinimag.2021.01.016
- Lehman, C.D., et al., Unilateral Lymphadenopathy After COVID-19 Vaccination: A Practical Management Plan for Radiologists Across Specialties. *Journal of the American College of Radiology*, 2021. 18(6):843-852. [PubMed]
- Brown, A., et al., Unilateral axillary adenopathy following COVID-19 vaccination: a multimodality pictorial illustration and review of current guidelines. *Clinical Radiology*, 2021. [Free Full Text]
- Shirone, N., et al., Axillary lymph node accumulation on FDG-PET/CT after influenza vaccination. *Annals of nuclear medicine*, 2012. 26(3):248-252. [Free Full Text]

11. Becker, A.S., et al., Multidisciplinary recommendations regarding post-vaccine adenopathy and radiologic imaging: radiology scientific expert panel. *Radiology*, 2021;210436. [\[PubMed\]](#)
12. Hanneman, K., R.M. Iwanochko, and P. Thavendiranathan, Evolution of lymphadenopathy at PET/MRI after COVID-19 vaccination. *Radiology*, 2021. 299(3): E282-E282. DOI: [10.1148/radiol.2021210386](https://doi.org/10.1148/radiol.2021210386)
13. Cocco, G., et al., Lymphadenopathy after the anti-COVID-19 vaccine: multiparametric ultrasound findings. *Biology*, 2021. 10(7):652. [\[PubMed\]](#)
14. Washington, T., R. Bryan, and C. Clemow, Adenopathy following COVID-19 vaccination. *Radiology*, 2021. 299(3): p. E280-E281. [\[Full Free Text\]](#)
15. Mortazavi, S., Coronavirus disease (COVID-19) vaccination associated axillary adenopathy: imaging findings and follow-up recommendations in 23 women. *American Journal of Roentgenology*, 2021. [\[Free Full Text\]](#)
16. Ahn, R.W., et al., Axillary lymphadenopathy after mRNA COVID-19 vaccination. *Radiology: Cardiothoracic Imaging*, 2021;3(1):e210008.DOI: [10.1148/ryct.2021210008](https://doi.org/10.1148/ryct.2021210008)
17. Hiller, N., et al., Lymphadenopathy associated with the COVID-19 vaccine. *Cureus*, 2021. 13(2). [\[PubMed\]](#)