

ORIGINAL RESEARCH

PAIN MANAGEMENT

Single cycle, low temperature radiofrequency ablation is effective for trigeminal neuralgia

Trianggoro Budisulistyo¹, Yani Arlina²

Author affiliation:

1. Trianggoro Budisulistyo, Department of Neurology, Pain & Minimally Invasive, Faculty of Medicine, Diponegoro University/ The Dr. Kariadi Central General Hospital, Jl. DR. Sutomo No.16, Randusari, Kec. Semarang Sel., Kota Semarang, Jawa Tengah 50244, Indonesia; E-mail: trianggoro.b@gmail.com; ORCID: {0000-0001-8085-5030}
2. Yani Arlina, Department of Neurology, Faculty of Medicine, Diponegoro University/ The Dr. Kariadi Central General Hospital, Jl. DR. Sutomo No.16, Randusari, Kec. Semarang Sel., Kota Semarang, Jawa Tengah 50244, Indonesia; E-mail: yani.arlina16@gmail.com; ORCID: {0000-0001-6577-2894}

Correspondence: Trianggoro Budisulistyo; E-mail: trianggoro.b@gmail.com; Phone: 62248443239; Mobile: 0 62811272984

Abstract

Background & Objective: Trigeminal neuralgia (TN) is the most common cause of neuropathic pain with few issues regarding medications whereas surgeries need careful consideration. Radiofrequency ablation (RFA) can be used as an intervention treatment bridging the gap of long-term medication and surgical intervention. RFA procedure has its own complications following electrode placement and ablation procedures. We analyzed the effectiveness of low temperature RFA treatment in patients with trigeminal neuralgia.

Methodology: This study was a prospective analysis of the data from the medical records of 21 patients. A single cycle of RFA at 60° C for 90 sec was performed from November 2018 to July 2019. Data collection included preoperative pain scores, analgesics prescribed, pain scores on numerical rating scale (NRS) for 6 months follow up.

Results: The subjects 53.86 ± 10.48 y (43% men and 57% women) observed NRS decrease significantly (mean 2.15, SD 0.9; $p < 0.05$). No significant influence of analgesic combination gabapentin and Amitriptyline, or carbamazepine and Amitriptyline to pain spectrum improvement underwent RFA.

Conclusion: A single cycle of RFA treatment at 60° C for 90 sec among TN patients showed significant improvement of pain at 6 months without complications.

Abbreviations: TN: trigeminal neuralgia; NMDA: N-methyl-d-aspartate GABA: gamma aminobutyric acid; TCA: tricyclic antidepressant; MVD: microvascular decompression; RFA: radiofrequency ablation; PRF: pulsed radiofrequency; NRS: numerical rating score; SNRI: serotonin-norepinephrine reuptake inhibitor

Key words: Trigeminal Neuralgia; Gasserian Ganglion; Radiofrequency; Neuroablation; Pain

Citation: Budisulistyo T, Arlina Y. Single cycle, low temperature radiofrequency ablation for trigeminal neuralgia shows clinical improvement of pain. *Anaesth. pain intensive care* 2022;26(5):669-673.

DOI: [10.35975/apic.v26i5.2024](https://doi.org/10.35975/apic.v26i5.2024)

Received: February 28, 2022; **Reviewed:** May 21, 2022; **Accepted:** July 23, 2022

1. Introduction

The 5th cranial nerve or trigeminal nerve (TG) has two main portions; the trigeminal nucleus and the Gasserian ganglion. The nucleus extends throughout the entire brain stem and the Gasserian ganglion (GG) is located in the Meckel's cave close to the anterior surface of the petrous part of the temporal bone. From here arise three main branches of the TN; the 1st branch, called ophthalmic nerve, lies medioposteriorly, the 2nd branch, the maxillary nerve, lies intermediate, and the 3rd branch, the mandibular

nerve, lies ventrolaterally.¹ Trigeminal neuralgia (TN) can be found in 12.6 to 27 per 100,000 people, annually.¹⁻³ The classical TN (CTN) is caused by vascular compression, and secondary TN (STN) by abnormal structures around foramen ovale.^{2,4,5} Accompanied vessels might cause TG demyelination leading to hyperexcitability and ectopic discharge to the neighboring fibers.⁴

The most commonly used drugs are carbamazepine (CBZ) and oxcarbazepine (OXC), which can reduce 80% of the symptoms as first-line treatment, but long-

term use might alter the mental status and memory, and lead to bone calcium catabolism, weight gain, syndrome of inappropriate antidiuretic hormone (SIADH), hypersensitivity, dizziness, instability state or acute lymphoblastic leukemia.^{6,7} Lamotrigine (LTG) inhibits the glutamate, and baclofen, an gamma-amino-butyric-acid (GABA) receptor agonist, have been used as second-line treatment.^{1,8,9} Botulinum toxin type A (BTX-A) has also been used for pain management.^{1,9-12} Gabapentin (GB) and pregabalin (PG) are less preferred as monotherapy,^{9,10} and need caution regarding the kidney and liver functions and mental status changes.¹³ Tricyclic antidepressants (TCA) have potent anti-arrhythmia action, sedation, coma, or death in long-term medication.^{14,15}

Various interventional procedures have been introduced in the clinical practice of pain management, including microvascular decompression (MVD), and gamma knife radiosurgery (GKRS). Both treatments have level C of evidence-based medicine.^{14,16-22}

Prior treatment by phenol gangliolysis or balloon decompression might cause surrounding tissue damage,^{16,23-25} while radiofrequency ablation (RFA) has less than 1% of complication rate.²⁶⁻²⁸ The initial remission rate of RFA was 85.3% to 97.7%, compared to 94% by pulsed radiofrequency (PRF), and after 5 y the RFA remission was 50.4% to 80.7%.²⁹ The recurrence rate gradually increases with the passage of time, but is reduced after repeated ablation.³⁰ There is no significant differences in pain improvement among patients treated with RFA at 68°C–70°C or 71°C–75°C. However, lower temperatures may be safer than higher temperatures.³¹ The evidence-based medicine categorizes RFA as 2B+ and PRF as 2B for TN treatment.^{32,33}

The local anesthetic block for diagnostic purpose might confuse the exact lesion site(s), so we used sensory stimulation for diagnostic purposes. A local anesthetic can reduce the unpleasant sensation, and the patients might confuse if the sensory stimulation is on the corrected TG branch(es) or not. We hypothesized that if correct lesion site(s) can be found, we may apply lower temperature than the routine with a good result.

2. Methodology

It was a prospective, observational study approved by the Ethical committee: No. 856/EC/KEPK-RSDK/2021 to evaluate the effectiveness of RFA procedure at 60 °C, among twenty-one TN patients, conducted between November 2018 to July 2019. All patients were hospitalized in our hospital. TN patients with unsatisfactory prior analgesic treatment were offered to consent to be involved in the present study, while those who refused to join the study and those who had head or face surgery were excluded.

We analyzed the numerical rating scale (NRS) of subjects prior to and 6 months after the intervention. Twelve subjects had suffered from pain for 6 months

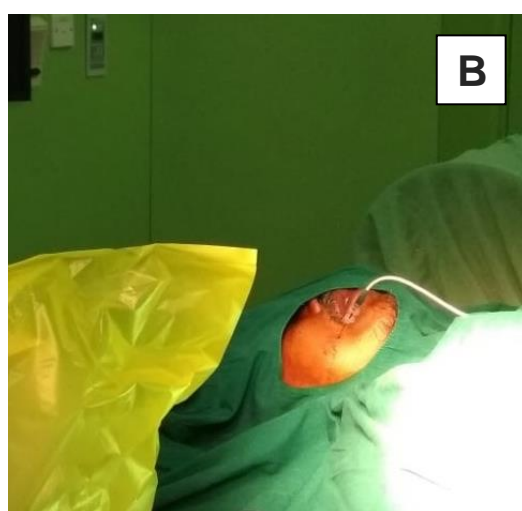
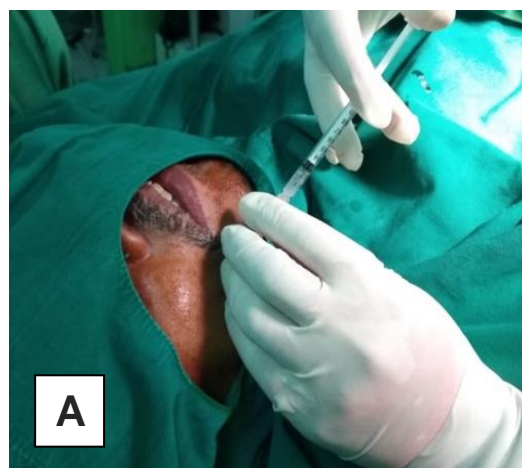
Figure 1. Procedure: (A) administration of 1 mL lidocaine 2%, (B) RFA procedure on the lateral view of C-arm fluoroscopy

and nine subjects had neuralgia for more than 6 months. Drugs used were: CBZ (200 - 400 mg/ day), GB (150 – 600 mg/ day), and TCA (amitriptyline 12.5 – 50 mg/ day). The potential complications were: worsening of the facial motor weakness, diminished corneal reflex, hypoesthesia, persistent pain, hypersensitive reaction to local anesthetic (lidocaine), antibiotic, or RF materials.

Subjects were placed in supine position with hemodynamic monitoring and the head extended head, face scrubbed at 2–3 cm laterally to the lips. C-arm fluoroscopy placed on by slightly oblique rotation 20° to 25°, caudally tilted at 45° to 50° as the lesion site so that the foramen ovale was visualized. Inj. lidocaine 2%, 2 mL was injected for local anesthesia followed by insertion of a 10 cm long needle 22 G, straight toward the pupil (Figure 1), the depth not exceeding 2 mm from the plane of the clivus at the lateral view, and smoothly inserted just after passing through the foramen ovale (Figure 2). The sensory stimulation was performed at 50 Hz and 0.1–1.5 volts, by pulling out the stilet and inserting the electrode's tip through the

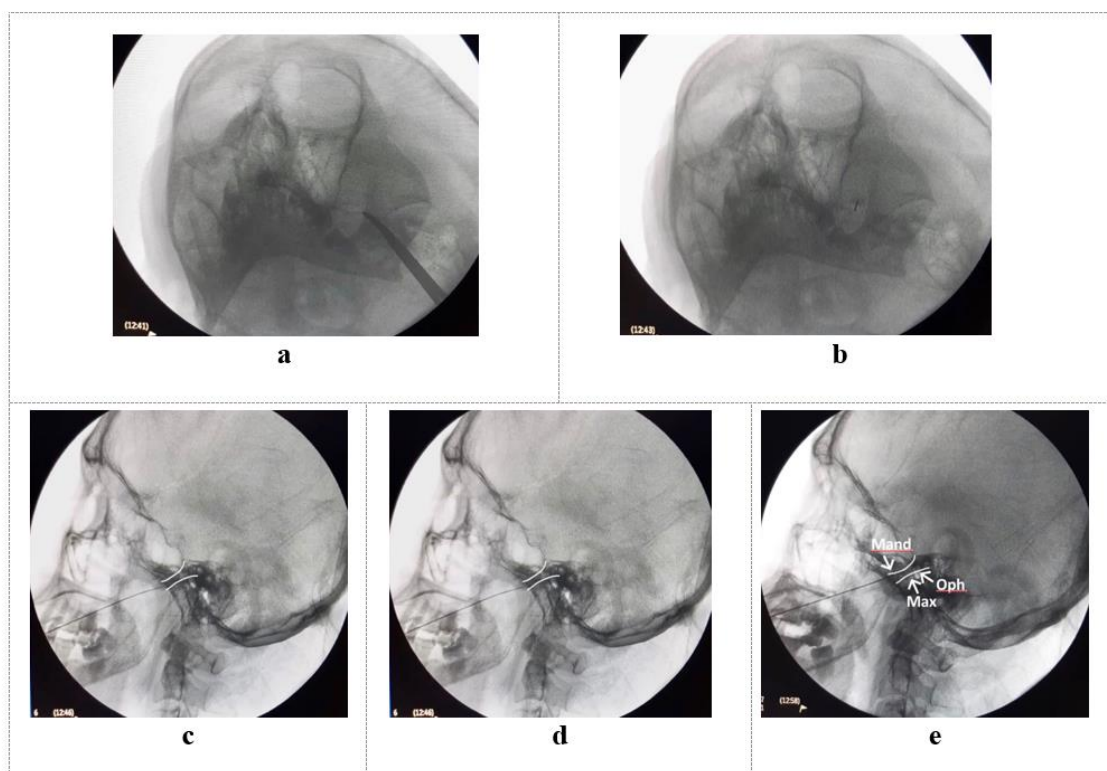


Figure 2: Procedural scheme of GG RFA: (a) Skin landmarked of left rounded FO in caudal tilt 30° to 40° and left 10° to 15° oblique view; (b) RF cannula inserted in tunnel view; (c) lateral view showed 'imagery tunnel' in line to the clivus; (d) advancing RF cannula through the FO; (e) tip placed near to common anatomical consideration of each branch (Mand: mandibular branch, Max: maxillary branch, Oph: ophthalmic branch).

cannula, then motor stimulation was set at 2 Hz, 0.1–1.5 volts. Quite commonly the subjects would identify the correct painful TG branch(es) affected in this step. In this study, we applied the diagnostic block procedure by using sensory stimulation (below 0.5 volts), and then 1 mL of lidocaine 1.5% was injected just before the ablation started.

A single cycle of RFA procedure by setting up a G4 Cosman™ generator on 60°C for 90 sec according to affected branches was completed and the patient was shifted to the recovery room for observation at least for half to one hour. Post-procedure the patient was followed up for 6 months. Data were identified using IBM Statistical Product and Service Solutions (SPSS) for windows version 26.0. NRS before and after were compared with the Wilcoxon signed-rank test. For all comparisons, $P < 0.05$ was accepted to be significant.

3. Results

The study was completed by all 21 patients, who underwent an RFA procedure following TN diagnosis. Nine men and 12 women, age average of 53.86 ± 10.48 y, were included (Table 1). The duration of TN ranged from 3 to 24 months (mean 8.3 ± 6.3 months). The pain was noted to improve significantly by NRS scale within 6 months follow-up (33.3% to 85.7%, mean 63.04%), or by Wilcoxon signed-rank test by mean 2.15 ± 0.9 ($P < 0.05$) (Table 2). Both genders suffered from TN without significant correlation to pain i

Table 1. General characteristics of the patients

Variable	Value
Age (y)	53.86 ± 10.48
Gender M : F	9 (42.9%) : 12 (57.1%)
Duration of complaints (months)	8.3 ± 6.3
<i>Data presented as Mean \pm SD or n (%)</i>	

Table 2. Numeric Rating Scale pre- and post RFA treatment

Parameter	Pre-RFA	Post-RFA	P
NRS	5.66 ± 1.01	2.14 ± 0.96	0.00
<i>NRS: Numeric Rating Scale. A respondent selects a whole number (0–10 integers) that best reflects the intensity of his/her pain. RFA. Radiofrequency Ablation</i>			

improvement ($P > 0.05$). We observed significant pain improvement without any serious complications. Two subjects suffered from mild facial hypoesthesia, wherein all of the analgesic prescriptions were reduced.

4. Discussion

RFA acts by the thermocoagulation of nociceptive fibers (A- δ and C), whereas lower temperatures might

not alter A- α and A- β fibers.³⁵ The improvement after 6 months follow up was 33.3% to 85.7% (mean 63.04%) without complications, as compared to 82°C and 2 min cycles with 5 y follow-up (50.4%).¹¹ The 60 sec of each: 65°C, 70°C, and 75°C within 18 months follow up showed improvement. At 24 h, 77.8% patients with improvement, at 1-month 77.8%, at 3-months 82.4%, at 6-months 80%, at 1-year 63.6%, and at 1.5 years 33.3%. The first cycle of RFA successfully 66.7%^{27,31,36}, similar to this study (mean 63.04%).^{5,11,36} This study was conducted to monopolar RF technology, which by increasing the temperature from 60°C to 90°C the lesion width might increase 2.9 mm to 5.2 mm, so 1.8 mm to 2.8 mm of the length within 2 min. It was observed that by increasing the temperature and duration of ablation might enhance the heating of the area surrounding the active cannula tip.³⁷ While injections of saline or lidocaine before the ablation might enhance the ablation lesion size. By 6 months of follow-up, the lower temperature and shorter duration (90 sec), observed significant pain improvement. The curved tip-electrode needling may avoid unnecessary injuries, and unwanted ablation of the branch(es) of the nerves with single ablation.³⁶ Pain improvement is associated with neuromodulation from RF electric fields, rather than by neurolytic mechanisms. Recently the role of RF has been studied in many other pathologic conditions with variable success.³⁷⁻⁴⁰

5. Limitations

There were a few limitations of our study; the sample size was much small, existing comorbidities might have effected the pain improvement such as patients with diabetes or depression, a comparison with 2 or 3 groups treated with higher temperatures and a longer follow-up need to be further analyzed.

6. Conclusions

A single cycle of RF treatment at 60°C for 90 sec among trigeminal neuralgia patients showed significant improvement of pain severity at 6 months without any complications.

7. Data availability

The numerical data generated during this research is available with the authors.

8. Acknowledgement

We gratefully acknowledge the full cooperation by the staff of the Department of Neurology, Dr. Kariadi Central General Hospital, Kota Semarang, Jawa Tengah, Indonesia, in the conduct of this study.

9. Conflict of interest

The study received no external or industry funding. Own hospital resources were utilized for the study.

10. Authors' contribution

TB: concept, conduction of the study work and manuscript editing

YA: followed-up monitoring of the subjects and assisted of statistical analysis

11. References

- Montano N, Conforti G, Di Bonaventura R, Meglio M, Fernandez E, Papacci F. Advances in diagnosis and treatment of trigeminal neuralgia. *Ther Clin Risk Manag.* 2015;11:289-99. [PubMed] DOI: [10.2147/TCRM.S37592](https://doi.org/10.2147/TCRM.S37592)
- Crucu G, Finnerup NB, Jensen TS, Schulz J, Sindou M, Svensson P, et al. Trigeminal neuralgia neuralgia new classification and diagnostic grading for practice and research. *Neurology.* 2016;87:220-28. [PubMed] DOI: [10.1212/WNL.0000000000002840](https://doi.org/10.1212/WNL.0000000000002840)
- Spina A, Mortini P, Alemanno F, Houdayer E, Iannaccone S. Trigeminal neuralgia: toward a multimodal approach. *World Neurosurg.* 2017;103:220-30. [PubMed] DOI: [10.1016/j.wneu.2017.03.126](https://doi.org/10.1016/j.wneu.2017.03.126)
- Yadav YR, Nishta Y, Sonjray P, Vijay P, Shailendra R, Yasin K. Trigeminal neuralgia. *Asian J Neurosurg.* 2017;12:585-97. [PubMed] DOI: [10.4103/ajns.AJNS_67_14](https://doi.org/10.4103/ajns.AJNS_67_14)
- Bendtsen L, Zakrzewska JM, Abbott J, Braschinsky M, Di Stefano G, Donnet A, et al. European Academy Of Neurology Guideline On Trigeminal Neuralgia. *Eur J Neurol.* 2019;26(6):831-49. [PubMed] DOI: [10.1111/ene.13950](https://doi.org/10.1111/ene.13950)
- Besi E, Boniface DR, Cregg R, Zakrzewska J. Comparison of tolerability and adverse symptoms in oxcarbazepine and carbamazepine in the treatment of trigeminal neuralgia and neuralgiform headaches using the Liverpool Adverse Events Profile (AEP). *J Headache Pain.* 2015;16:563. [PubMed] DOI: [10.1186/s10194-015-0563-z](https://doi.org/10.1186/s10194-015-0563-z)
- Goyal C, Bhandari V, Rafi M. Long term carbamazepine therapy induced acute lymphoblastic leukemia. *Int J Basic Clin Pharmacol.* 2013;2(2):222-3. DOI: [10.5455/2319-2003.ijbcp20130320](https://doi.org/10.5455/2319-2003.ijbcp20130320)
- Al-Quliti KW. Update On neuropathic pain treatment for trigeminal neuralgia. The pharmacological and surgical options. *Neurosciences (Riyadh).* 2015;20(2):107-14. [PubMed] DOI: [10.17712/nsj.2015.2.20140501](https://doi.org/10.17712/nsj.2015.2.20140501)
- Di Stefano G, Truini A, Cruccu G. Current and innovative pharmacological options to treat typical and atypical trigeminal neuralgia. *Drugs.* 2018;78(14):1433-42. [PubMed] DOI: [10.1007/s40265-018-0964-9](https://doi.org/10.1007/s40265-018-0964-9)
- Kitt CA, Kenneth G, Miriam D, Clifford JW, Jon DL. Trigeminal Neuralgia: Opportunities For Research And Treatment. *Pain.* 2000;85(1-2):3-7. [PubMed] DOI: [10.1016/S0304-3959\(99\)00310-3](https://doi.org/10.1016/S0304-3959(99)00310-3)
- Elzohry AAM, Amin AM, Abdel- Wahab AT, Hassanin AAM. Medical treatment versus radiofrequency ablation for patients with trigeminal neuralgia: a prospective clinical study. *Clin Res Neurol.* 2019;2(2):1-5. [FreeFullText]
- Börü ÜT, Duman A, Bölük C, Duman SC, Tasdemir M. Botulinum toxin in the treatment of trigeminal neuralgia: 6-month follow-up. *Medicine.* 2017;96(39):e8133. [PubMed] DOI: [10.1097/MD.00000000000008133](https://doi.org/10.1097/MD.00000000000008133)
- Fleet JL, Dixon SN, Kuwornu PJ, Dev VK, Montero-Odasso M, Burneo J, et al. Gabapentin dose and the 30-day risk of altered mental status in older adults: A retrospective population-based study. *PLoS One.* 2018;13(3):e0193134. [PubMed] DOI: [10.1371/journal.pone.0193134](https://doi.org/10.1371/journal.pone.0193134)
- Lawal AO, Adisa AO, Akinyamoju AO, Kolude B. Management of trigeminal neuralgia using amitriptyline and pregabalin

- combination therapy. *Afr J Biomed Res.* 2012;15(3):201–3. [FreeFullText]
15. Umaharan T, Sivayokan S, Sivansuthan S. Amitriptyline dependence and its associations: a case report and literature review. *Case Rep Psychiatry.* 2021 Jan 29;2021:6647952. [PubMed] DOI: [10.1155/2021/6647952](https://doi.org/10.1155/2021/6647952)
 16. Li Y, Yang L, Ni J, Dou Z. Microvascular decompression and radiofrequency for the treatment of trigeminal neuralgia: a meta-analysis. *J Pain Res.* 2019 Jun 28;12:1937-1945. [PubMed] DOI: [10.2147/JPR.S203141](https://doi.org/10.2147/JPR.S203141)
 17. Vasappa CK, Kapur S, Krovvidi H. Trigeminal Neuralgia. *BJA Edu.* 2016;16(10):353–6. DOI: [10.1093/bjaed/mkw015](https://doi.org/10.1093/bjaed/mkw015)
 18. Cong L, Zhihua C, Zhilin G, Huoni OY. Effects of microvascular decompression plus longitudinal nerve sectioning on recurrent trigeminal neuralgia and investigations of postoperative recurrence causes. *Turk Neurosurg.* 2019;29(3):369-376. [PubMed] DOI: [10.5137/1019-5149.JTN.23513-18.1](https://doi.org/10.5137/1019-5149.JTN.23513-18.1)
 19. Jafree DJ, Williams AC, Zakrzewska JM. Impact of pain and postoperative complications on patient-reported outcome measures 5 years after microvascular decompression or partial sensory rhizotomy for trigeminal neuralgia. *Acta Neurochir.* 2018;160:125–34. [PubMed] DOI: [10.1007/s00701-017-3350-6](https://doi.org/10.1007/s00701-017-3350-6)
 20. Gandhoke GS, Smith KJ, Niranjana A, Sekula RF, Lunsford LD. Comparing microvascular decompression with gamma knife radiosurgery for trigeminal neuralgia: a cost-effectiveness analysis. *World Neurosurg.* 2019;125:207-16. [PubMed] DOI: [10.1016/j.wneu.2018.12.204](https://doi.org/10.1016/j.wneu.2018.12.204)
 21. Gagliardi F, Spina A, Bailo M, Boari N, Cavalier A, Franklin A, et al. Effectiveness of gamma knife radiosurgery in improving psychophysical performance and patient's quality of life in idiopathic trigeminal neuralgia. *World Neurosurg.* 2018;110:e776-85. [PubMed] DOI: [10.1016/j.wneu.2017.11.096](https://doi.org/10.1016/j.wneu.2017.11.096)
 22. Zhang H, Lei D, You C, Mao BY, Wu B, Fang Y. The long-term outcome predictors of pure microvascular decompression for primary trigeminal neuralgia. *World Neurosurg.* 2013;79:756-62. [PubMed] DOI: [10.1016/j.aneurysm.2012.01.040](https://doi.org/10.1016/j.aneurysm.2012.01.040)
 23. Bithal PK. Radiofrequency Thermocoagulation For Trigeminal Neuralgia. In: *Handbook of Trigeminal Neuralgia.* Springer Singapore; 2019. p.141-150. DOI: [10.1007/978-981-13-2333-1_1](https://doi.org/10.1007/978-981-13-2333-1_1)
 24. Abd-Elseyed A, Nguyen S, Fiala K. Radiofrequency ablation for treating headache: a follow-up study. *Curr Pain Headache Rep.* 2020 Mar 12;24(4):15. [PubMed] DOI: [10.1007/s11916-020-0843-4](https://doi.org/10.1007/s11916-020-0843-4)
 25. Asplund P, Blomstedt P, Bergenheim AT. Percutaneous balloon compression vs percutaneous retrogasserian glycerol rhizotomy for the primary treatment of trigeminal neuralgia. *Neurosurgery.* 2016 Mar;78(3):421-8. [PubMed] DOI: [10.1227/NEU.0000000000001059](https://doi.org/10.1227/NEU.0000000000001059)
 26. Akbas M, Salem HH, Emara TH, Dinc B, Karsli B. Radiofrequency thermocoagulation in cases of atypical trigeminal neuralgia: a retrospective study. *Egypt J Neurol Psychiatry Neurosurg.* 2019;55:46. DOI: [10.1186/s41983-019-0092-9](https://doi.org/10.1186/s41983-019-0092-9)
 27. Erdine S, Ozyalcin NS, Cimen A, Celik M, Talu GK, Disci R. Comparison of pulsed radiofrequency with conventional radiofrequency in the treatment of idiopathic trigeminal neuralgia. *Eur J Pain.* 2007;11(3):309-13. [PubMed] DOI: [10.1016/j.ejpain.2006.04.001](https://doi.org/10.1016/j.ejpain.2006.04.001)
 28. Sharma G, Dey S. Trigeminal neuralgia: radiofrequency ablation. *J Recent Adv Pain.* 2018;4(1):36-8. [FreeFullText] DOI: [10.5005/jp-journals-10046-0099](https://doi.org/10.5005/jp-journals-10046-0099)
 29. Wang C, Dou Z, Yan M, Tang Y, Zhao R, Han Y, et al. The comparison of efficacy and complications of coblation and radiofrequency thermocoagulation for V2/V3 idiopathic trigeminal neuralgia: a retrospective cohort study of 292 cases. *BMC Anesthesiol.* 2021 Jan 7;21(1):6. [PubMed] DOI: [10.21203/rs.3.rs-29873/v1](https://doi.org/10.21203/rs.3.rs-29873/v1)
 30. Liu G, Du Y, Wang X, Ren Y. Efficacy and safety of repeated percutaneous radiofrequency thermocoagulation for recurrent trigeminal neuralgia. *Front Neurol.* 2019 Jan 18;9:1189. [PubMed] DOI: [10.3389/fneur.2018.01189](https://doi.org/10.3389/fneur.2018.01189)
 31. Wu H, Zhou J, Chen J, Gu Y, Shi L, Ni H. Therapeutic efficacy and safety of radiofrequency ablation for the treatment of trigeminal neuralgia: a systematic review and meta-analysis. *J Pain Res.* 2019 Jan 18;12:423-441. [PubMed] DOI: [10.2147/JPR.S176960](https://doi.org/10.2147/JPR.S176960)
 32. Ajayi NO, Lazarus L, Satyapal KS. Trigeminal cave and ganglion: an anatomical review. *Int J Morphol.* 2013;31(4):1444-8. DOI: [10.4067/S0717-95022013000400047](https://doi.org/10.4067/S0717-95022013000400047)
 33. Akbas M, Salem HH, Emara TH, Dinc B, Karsli B. Radiofrequency thermocoagulation in cases of atypical trigeminal neuralgia: a retrospective study. *Egypt J Neurol Psychiatry Neurosurg.* 2019;55:46. DOI: [10.1186/s41983-019-0092-9](https://doi.org/10.1186/s41983-019-0092-9)
 34. Díaz RCR, Benavides JLB, Álvarez JG. Gasserian ganglion thermal radiofrequency in patients with trigeminal neuralgia. *Rev Colomb Anaesthesiol.* 2013;41(2):127–31. DOI: [10.1016/j.rca.2013.03.001](https://doi.org/10.1016/j.rca.2013.03.001)
 35. Arslan M, Deda H, Avci E, Elhan A, Tekdemir I, Tubbs RS, et al. Anatomy of Meckel's Cave and the Trigeminal Ganglion: Anatomical Landmarks for a Safer Approach to Them. *Turk Neurosurg.* 2012;22(3):317-23. [PubMed] DOI: [10.5137/1019-5149.JTN.5213-11.1](https://doi.org/10.5137/1019-5149.JTN.5213-11.1)
 36. Singh S, Verma R, Kumar M, Rastogi V, Bogra J. Experience with conventional radiofrequency thermorhizotomy in patients with failed medical management for trigeminal neuralgia. *Korean J Pain.* 2014;27 (3):260-5. [PubMed] DOI: [10.3344/kjp.2014.27.3.260](https://doi.org/10.3344/kjp.2014.27.3.260)
 37. Cosman Jr ER, Dolensky JR, Hoffman RA. Factors that affect radiofrequency heat lesion size. *Pain Medicine.* 2014;15:2020–36. [PubMed] DOI: [10.1111/pme.12566](https://doi.org/10.1111/pme.12566)
 38. Mohammed N, Jubara MAA. Effectiveness of pulsed radiofrequency in chronic lumbosacral radicular pain. *Anaesth. pain intensive care.* 2021;25(4):464–469. [Free full text] DOI: [10.35975/apic.v25i4.1566](https://doi.org/10.35975/apic.v25i4.1566)
 39. Usman A, Butt FR, Durrani RS, Ghafoor AR. Pain relief in a patient with massive sino-nasal tumor. *Anaesth. pain intensive care.* 2020;24(4):457-459. [Free full text] DOI: [10.35975/apic.v24i4.1320](https://doi.org/10.35975/apic.v24i4.1320)
 40. Mimaroglu C, Mimaroglu Altinay B, Duger C, Isbir AC, Gursoy S, Kaygusuz K, et al. The evaluation of radiofrequency facet nerve denervation in the patients with lumbar facet syndrome: experience with 493 patients. *Anaesth. pain intensive care.* 2017;21(4):438-441. [Free full text]