

CASE REPORT

ANESTHESIA & CONCURRENT DISEASE

Complete atrioventricular block after an anesthetic induction in a patient with unknown metabolic acidosis

L. Ferreira,^{1*} P. Santos,¹ F. Correia,¹ A. Vieira,¹ A. Bernardino,¹ A. Freitas²

Author affiliation:

1. Luis Silva Ferreira, Department of Anaesthesiology, Coimbra University Hospital, Coimbra, Portugal [Luis.ferreira.f7@gmail.com] {ORCID:0000-0002-5928-5456}
2. Pedro Santos, Department of Anaesthesiology, Coimbra University Hospital, Coimbra, Portugal [pmfs.25@gmail.com] {ORCID:0000-0001-7181-4958}
3. Filipa Correia, Department of Anaesthesiology, Coimbra University Hospital, Coimbra, Portugal [anaalbuquerquecorreia@gmail.com] {ORCID:0000-0002-2030-1842}
4. Ana Vieira, Department of Anaesthesiology, Coimbra University Hospital, Coimbra, Portugal [vet.anavieira@gmail.com] {ORCID:0000-0001-5498-1404}
5. André Freitas, Department of Cardiology, Coimbra University Hospital, Coimbra, Portugal [Andre.azulfreitas@gmail.com] {ORCID:0000-0002-0127-2441}

Correspondence: Luis Silva Ferreira; E-mil: Luis.ferreira.f7@gmail.com

Summary

Clinical case of an 84-year-old female patient who developed a complete heart block a few minutes after anesthetic induction associated with hemodynamic instability, nonresponsive to vagolytic and adrenergic medication. Transcutaneous pacing was started with hemodynamic improvement. After the event, a decompensated metabolic acidosis was detected which was promptly corrected, leading to a normalization of the heart rhythm. Metabolic acidosis is a described but uncommon cause of atrioventricular block. The authors are not aware of previous report of complete heart block in this context. We would like to draw attention to the importance of choosing carefully which anesthetic drugs should be used in these cases.

Key words: Atrioventricular block; General anesthesia; Metabolic acidosis; Bradycardia

Citation: Ferreira LS, Santos P, Correia F, Vieira A, Freitas A. Complete atrioventricular block after an anesthetic induction in a patient with unknown metabolic acidosis. . *Anaesth. pain intensive care* 2022;26(2):249-252; DOI: 10.35975/apic.v26i2.1828

Received: December 18, 2021, **Reviewed:** January 27, 2022, **Accepted:** February 2, 2022

Introduction

Third-degree or complete atrioventricular block is characterized by a transient or permanent alteration in the atrioventricular (AV) conduction system, that interrupts the transmission of the electric impulse from the atria to the ventricles. It can compromise the cardiac output with hemodynamic instability, which can be noncompliant to vagolytic and adrenergic drugs. In these cases, the use of pacemaker can be the last therapeutic resource in order to avoid a progression to a cardiopulmonary arrest.

The purpose of this paper, is to describe a case of a transitory complete heart block (CHB) that took place after a general anesthesia induction on a patient with no risk factors, which had an unknown metabolic acidosis.

The authors are not aware of previous report of complete heart block in this context.

Case report

An 84 year-old female was proposed to a femoral intramedullary nailing for a right femoral shaft fracture. The woman had arterial hypertension and osteoporosis, which were treated with oral medication (pantoprazole, lisinopril and calciferol). In the past, she was submitted to an appendectomy and to prosthetic replacement of the right knee, both under general anesthesia, without complications. The patient denied any cardiac symptoms, including syncope or thoracic pain at rest or during effort. A metabolic equivalents (MET) of 4 was

established. During the 5-day stay, the patient had an acute renal failure associated with hyperkalemia, both of which were resolved. The preoperative exams showed 81 beats/min sinus rhythm, a Hb 110 gm/L, normal creatinine levels and a borderline Na^+ (136 mmol/L) and K^+ (5.2 mmol/L) levels.

sodium bicarbonate 8.4% was initiated. In the meantime, an isoprenaline perfusion was also started at 10 $\mu\text{g}/\text{min}$. The surgery was postponed and the patient transported to the Post-Anesthesia Care Unit (PACU). In the PACU, her BP was higher than 90/60 mmHg with a pacemaker rhythm of 60 beats/min. A 12-lead electrocardiogram

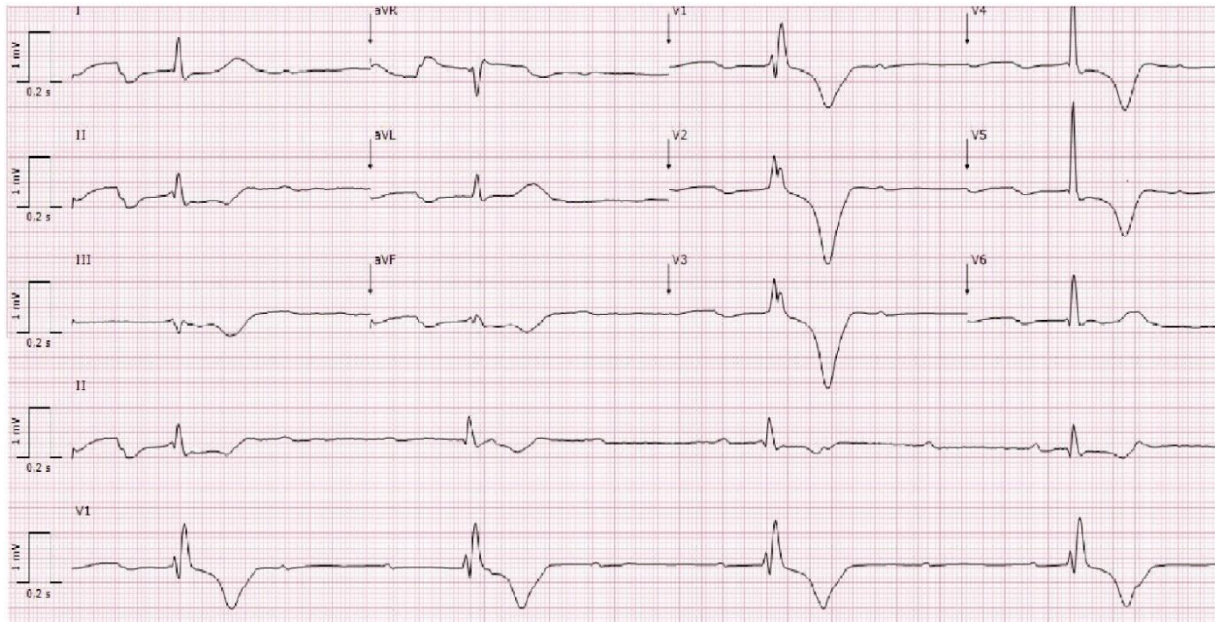


Figure 1: ECG trace showing complete heart block

No premedication was prescribed. In the operating room, the patient was monitored with the basic standard monitoring preconized by the American Society of Anesthesiologists and with a bispectral index (BIS) monitor. The patient was conscious, collaborative, had an 18 breaths/min respiratory rate with a 96% peripheral oxygen saturation, heart rate of 75 beats/min and a blood pressure (BP) of 131/70 mmHg. The patient refused regional anesthesia. General anesthesia was performed using 0.05 mg of fentanyl (0.07 $\mu\text{g}/\text{kg}$), 70 mg of propofol (1 mg/kg) for the induction, obtaining a 40-50 BIS score. The airway was secured with a number 4 I-gel® supraglottic airway. During the induction there was no relevant hemodynamic change. The anesthetic maintenance was started using sevoflurane 0.5%. During the positioning of the patient, approximately 5 min after the induction, the heart rate suddenly dropped to 24 beats/min with a rhythm suggestive of a CHB. The BP dropped to 42/23 mmHg and there was no improvement after the administration of 2 mg of atropine and 30 mg of ephedrine. An external pacing was started and a 60 beats/min ventricular rate was obtained, applying a 70 mA electric current, with a quick improvement of the BP. An arterial line was placed for invasive BP monitoring and for arterial blood gas testing, which revealed a pH 7.21, pCO_2 4.1 kPa, pO_2 12.6 kPa, HCO_3^- 16 mmol/L, base excess -6.9 and lactate 1.22 mmol/L. A 250 ml

confirmed the CHB (Figure 1). After 30 min, a second electrocardiogram was performed, showing a 68 beats/min, normal sinus rhythm. A transthoracic echocardiogram revealed a good ventricular function. Gradually, the isoprenaline perfusion was decreased until it was suspended. The cardiac enzymes did not reveal significant changes. After evaluation by cardiology there was no indication for permanent pacemaker.

The surgery was rescheduled after two weeks under general anesthesia. No complication was reported.

Discussion

The CHB is characterized by a transient or permanent change in the AV conduction system that interrupts the transmission of the electric impulse to the Purkinje fibers.¹ As a result, the atria and the ventricles contract independently of each other. Normally, the location of the block may be identifiable by the QRS complex size.¹ In this case, the patient developed wide QRS complexes, hemodynamic instability and no response to atropine, which was suggestive of a block located below the AV node.

The complete heart block may be acquired, which is most common, or congenital. Frequently, it is related to coronary heart disease, degenerative conduction system

defects, electrolyte disorders or the administration of drugs that interfere in the AV conduction system (Box 1).^{2,3} Normally, the occurrence of this kind of blocks is more common in patients with a previously known and less severe AV block.⁴

Box 1: Etiology of complete heart block
Congenital Disease
- Congenital AV block (pregnant women with systemic lupus erythematosus)
- Familial AV block (SCN5A mutation)
Degenerative
- Lev's disease; Lenegre's disease
Infectious
- Rheumatic fever; Endocarditis; Lyme's disease.
Inflammatory/ Infiltrative
- Sarcoidosis; Amyloidosis; Myocarditis
Ischemic
- Coronary artery disease
Metabolic / Endocrine
- Thyroid disease (hypothyroidism and hyperthyroidism)
- Electrolyte Disorders (hyperkalemia, hyponatremia and hypocalcemia)
- Acid-base disorders
- Hypothermia
- Adrenal gland disorders (Pheochromocytoma, hypoadosteronism)
Vagal stimulation
- Direct laryngoscopy and tracheal intubation
- Neurocardiogenic syncope
- Peritoneal retraction
- Bezold-Jarisch and Oculocardiac reflex
Iatrogenic
- Medication (beta-blockers, verapamil, diltiazem, digoxin, ondansetron, droperidol, metoclopramide, propofol, inhalational anesthetics, opioids, among others).
- Catheter Ablation
- Cardiac surgery (especially valve surgery)
- Transcatheter Aortic Valve Implantation (TAVI)

During the preoperative period, the patient had a normal electrocardiogram, no history of cardiac pathology or medication that could produce changes in the AV conduction. While hospitalized, she had an acute renal failure associated with hyperkalemia that was promptly

resolved. On the day before the procedure, the blood count was normal, with potassium and sodium in the superior and inferior limits of the normality, respectively.

During the intraoperative period, the risk factors include drugs that change the AV conduction, an increase of the vagal stimulation or the surgical manipulation. Drugs such as droperidol, metoclopramide and ondansetron may prolong the QT interval and originate an AV block.³ Opioids such as fentanyl or remifentanyl can also produce changes in the AV node that result in severe bradycardia.³ Additionally, some inhalational anesthetics can cause disturbances in the conduction system. Sevoflurane may prolong the QT interval significantly, inclusively, it was suspected that it could originate a CHB.⁵ Propofol can also induce a CHB, but only with higher doses (superior to 8 mg/kg).⁶ In the case presented, low-normal fentanyl and propofol doses were used for the induction. Consequently, we consider it does not justify the event. For the anesthetic maintenance, a low dose (0.5%) of sevoflurane was used, however we may not completely exclude its influence on the event.

The increase in vagal stimulation could also contribute to the episode. A well-recognized setting is the vagal stimulation induced by direct laryngoscopy and orotracheal intubation.⁷ However, this hypothesis was discarded, because the airway was secured by a Supraglottic Airway Device (SGD), which is associated with a much smaller parasympathetic response. Furthermore, the cardiac event did not happen immediately after the insertion of the SGD.

The authors believe that the most likely cause of the CHB was a decompensated metabolic acidosis, detected right after the event. The acidosis delays the electric conduction through the AV node,⁸ which is an uncommon cause of CHB.³ The acute renal insufficiency is frequently associated with metabolic acidosis.⁹ Nevertheless, in the day previous to the surgery the patient was stable and the blood count was normal. The patient was eupneic with 96% peripheral oxygen saturation (this aspect led us to not perform a preoperative arterial blood gas test). The hypothesis that the metabolic acidosis was the main cause for the event is reinforced with the rhythm normalization after the supplementation with sodium bicarbonate 8.4%. Nevertheless, we may not exclude the contribution of other factors because the event occurred 5 min after the anesthetic induction. The potassium and sodium values close to the extremity of normality and the anesthetic agents used may have contributed as facilitators to the alteration of the AV conduction.

A 12-lead ECG, a transthoracic echocardiogram, coronary angiography and/or electrophysiological tests should be requested to diagnose an AV block and its

etiology. In this case, an ECG and an echocardiogram did not reveal any significant alterations. Given the probable metabolic cause and the absence of cardiac risk factors, no further exams were realized.

The approach of a CHB includes a pharmacological and electric therapy.¹⁰ Atropine and/or isoprenaline can be used as first line therapy in order to increase heart rate temporarily. In refractory situations, such as this case, an electric therapy using a pacemaker should be considered.¹⁰ The guidelines recommend the implementation of a permanent pacemaker in all asymptomatic and symptomatic patients that have a CHB.¹⁰ Nonetheless, a temporary pacemaker (transcutaneous or transvenous) should be considered in situations where a reversible cause is identified. In our case, a transcutaneous pacemaker was started on the patient due to the refractory bradycardia with hemodynamic instability. As a result, because the probable cause was corrected and the patient returned to sinus rhythm, the implantation of a permanent pacemaker was not considered necessary.

This report presents a CHB case in the context of an unknown metabolic acidosis, which is rarely seen in medical literature. The preoperative evaluation of the patient is essential in all anesthetic acts, but does not prevent unexpected situations. Being aware for possible reversible metabolic alterations is crucial, particularly in elderly patients with recent changes in renal function, which may cause AV blocks. In these cases, the correct choice of drugs to use during the anesthetic procedure may be decisive.

Acknowledgements

Published with the written consent of the patient.

Conflict of Interest

No external funding and no competing interests declared

Authors' contribution

LF: First author, manuscript editor

PS, FC: Manuscript editing

AV, AF: Literature search

References

1. Bansal R, Rathi C, Lokhandwala Y. Where is the level of atrioventricular block? *Circulation*. 2020 Oct 27;142(17):1684-1686. [PubMed] DOI: [10.1161/CIRCULATIONAHA.120.050344](https://doi.org/10.1161/CIRCULATIONAHA.120.050344)
2. Byun JM, Jung CW, Shin SY. Occurrence of complete atrioventricular block during surgery. *Korean J Anesthesiol*. 2011 Jul;61(1):90-2. [PubMed] DOI: [10.4097/kjae.2011.61.1.90](https://doi.org/10.4097/kjae.2011.61.1.90)
3. Barra SN, Providência R, Paiva L, Nascimento J, Marques AL. A review on advanced atrioventricular block in young or middle-aged adults. *Pacing Clin Electrophysiol*. 2012 Nov;35(11):1395-405. [PubMed] DOI: [10.1111/j.1540-8159.2012.03489.x](https://doi.org/10.1111/j.1540-8159.2012.03489.x)
4. Shigematsu-Locatelli M, Kawano T, Nishigaki A, Yamanaka D, Aoyama B, Tateiwa H, et al. General anesthesia in a patient with asymptomatic second-degree two-to-one atrioventricular block. *JA Clin Rep*. 2017;3(1):27. [PubMed] DOI: [10.1186/s40981-017-0099-0](https://doi.org/10.1186/s40981-017-0099-0)
5. Zhang X, Firth PG. Third degree atrio-ventricular block in a 4-year-old child during sevoflurane anesthesia. *Paediatr Anaesth*. 2008 Dec;18(12):1217-8. [PubMed] DOI: [10.1111/j.1460-9592.2008.02699.x](https://doi.org/10.1111/j.1460-9592.2008.02699.x)
6. Sochala C, Deenen D, Ville A, Govaerts MJ. Heart block following propofol in a child. *Paediatr Anaesth*. 1999;9(4):349-51. [PubMed] DOI: [10.1046/j.1460-9592.1999.00373.x](https://doi.org/10.1046/j.1460-9592.1999.00373.x)
7. Redmann AJ, White GD, Makkad B, Howell R. Asystole from direct laryngoscopy: a case report and literature review. *Anesth Prog*. 2016 Winter;63(4):197-200. [PubMed] DOI: [10.2344/16-00014.1](https://doi.org/10.2344/16-00014.1)
8. Nisbet AM, Burton FL, Walker NL, Craig MA, Cheng H, Hancox JC, et al. Acidosis slows electrical conduction through the atrioventricular node. *Front Physiol*. 2014 Jun 25;5:233. [PubMed] DOI: [10.3389/fphys.2014.00233](https://doi.org/10.3389/fphys.2014.00233)
9. Zheng CM, Liu WC, Zheng JQ, Liao MT, Ma WY, Hung KC, et al. Metabolic acidosis and strong ion gap in critically ill patients with acute kidney injury. *Biomed Res Int*. 2014;2014:819528. [PubMed] DOI: [10.1155/2014/819528](https://doi.org/10.1155/2014/819528)
10. Kusumoto FM, Schoenfeld MH, Barrett C, Edgerton JR, Ellenbogen KA, Gold MR, et al. 2018 ACC/AHA/HRS guideline on the evaluation and management of patients with bradycardia and cardiac conduction delay: A Report of the American College of Cardiology/American Heart Association Task Force on Clinical Practice Guidelines and the Heart Rhythm Society. *Heart Rhythm*. 2019 Sep;16(9):e128-e226. [PubMed] DOI: [10.1016/j.hrthm.2018.10.037](https://doi.org/10.1016/j.hrthm.2018.10.037)