

CASE REPORT

CORONA EXPERIENCE

Pulmonary hypertension following severe COVID-19: a case report

Chandra Shekhar Karmakar ¹, Mohammad Abdul Hannan ¹, Md Shafiqul Islam ²,
Dilip Kumar Bhowmik ², AKM Akhtaruzzaman ³

1. Assistant Professor, Department of Anesthesia, Analgesia and Intensive Care Medicine, Bangabandhu Sheikh Mujib Medical University, Shahbag, Dhaka-1000, Bangladesh.

2. Associate Professor, Assistant Professor, Department of Anesthesia, Analgesia and Intensive Care Medicine, Bangabandhu Sheikh Mujib Medical University, Shahbag, Dhaka-1000, Bangladesh.

3. Professor and Chairman, Department of Anesthesia, Analgesia and Intensive Care Medicine, Bangabandhu Sheikh Mujib Medical University, Shahbag, Dhaka-1000, Bangladesh.

Correspondence: Prof. AKM Akhtaruzzaman; E-mail: akhtaruzzaman.akm@gmail.com

Abstract

Persistence of symptoms or development of new symptoms, late in the course of COVID-19 puts a constant burden on our healthcare facilities. In its severe form, COVID-19 patient may present as acute respiratory distress syndrome (ARDS), shock, and multiorgan failure and other immunological disharmony. With extensive parenchymal and vascular endothelial damage to lung vasculature, some patient may develop extensive fibrosis and pulmonary hypertension. Our patient a 60-year-old male, slightly overweight (BMI = 28.3) with history of IGT suddenly developed fever, sore throat and anosmia with myalgia. At 7th day of symptom his saturation fell down and patient was admitted in Bangabandhu Sheikh Mujib Medical University (BSMMU) for advance management. Initially patient was treated in COVID-19 ward, latter he was shifted to ICU as oxygen saturation was not maintained by HFNC. After a long battle of 56 days in ICU and 19 days stay in post COVID ward patient was discharged home with intermittent oxygen therapy only to develop pulmonary hypertension as a sequelae of post COVID syndrome. A holistic approach to management of post COVID syndrome is needed for such multisystem involvement of severe COVID patients.

Key words: COVID-19; Pulmonary hypertension; Post-COVID syndrome; CTEX CPAP; HFNC

Citation: Karmakar CS, Hannan MA, Islam MS, Bhowmik DK, Akhtaruzzaman AKM. Pulmonary hypertension following severe COVID-19: a case report. *Anaesth. pain intensive care* 2021;25(4):539-543.

DOI 10.35975/apicare.v25i4.1554

Received: May 29, 2021, **Reviewed:** June 10, 2021, **Accepted:** June 21, 2021

1. Introduction

COVID-19 has become an unprecedented public health crisis. As of 29th April, 2021 more than 147 million cases have been detected with a mortality of more than 3.11 million victims.¹ Clinical features vary from a mild asymptomatic disease to a more severe presentation with respiratory dysfunction, thrombotic complications and multiorgan failure.² COVID-19 can present with various atypical presentations apart from initial influenza-like symptoms. In a case series of over 1000 patients in China, 83% of patients had

lymphopenia, but neutropenia has very rarely been reported along with elevated levels of LDH, D-dimer, CRP and ferritin.³ Most patients with coronavirus disease recover completely, but few of them who had even mild disease may suffer from long term symptoms after complete recovery. Recent literature suggests a diverse set of symptoms that persist after a diagnosed COVID-19 infection known as post COVID syndrome or long COVID.⁴ About 10% of patients in the UK after resolution of the acute viral

infection have persistent or progressive symptoms even after sixty days of the disease of onset. 87.1% of discharged patients of COVID-19 still experience at least one symptom, dyspnea, chest pain, fatigue and impaired quality of life; three or more symptoms have been experienced by at least 55% of the patients.⁵ A survivor after severe COVID-19 may present with post-COVID syndrome (PCS) that may affect quality of life or even need a meticulous medical care for prolonged periods as our case exemplifies it.

2. Case report

A previously healthy, 60-year-old gentleman was diagnosed with COVID-19 pneumonia in the community on July 31, 2020, by his positive RT-PCR of nasopharyngeal swab. Initially, he presented with typical COVID complaints, e.g., fever, cough, myalgia, anosmia and a runny nose. He was instructed to self-quarantine at home and received supportive care with self-monitoring of oxygen saturation by portable pulse oximeter. Despite his initial efforts, he continued to experience persistent symptoms of fatigue, lethargy, intermittent dizziness and tachycardia.

On August 2, 2020, his oxygen saturation dropped to 92–93% at night, so he was admitted to Bangabandhu Sheikh Mujib Medical University COVID unit the next day. On admission, his vital signs were; pulse rate 95 bpm, blood pressure – 130/80 mmHg, SpO₂ 91%, and respiratory rate 26/ min. A set of investigations, including blood tests, ECG, chest X-ray and high-resolution CT (HRCT) chest was done which showed 40% lung involvement. Initially the patient was put on non-rebreathing facemask (NRM), and his SpO₂ was 94–95% with 10 L of oxygen. Inj. remdesivir, tab paracetamol, and low molecular weight heparin (LMWH) 40 unit S/C once was prescribed and breathing exercises by respirometer continued as per patient's tolerance.

Gradually the oxygen demand increased and the patient deteriorated clinically, so was shifted to ICU on August 6, 2020. Oxygen saturation dropped further, so he was put on oxygen through high flow nasal cannula (HFNC) at 70 L/min with FiO₂ 0.8. His SpO₂ was still 86% with respiratory rate 35/min. His Lab reports showed ferritin 338.2 ng/ml, LDH 505 U/L, CRP 101.33 mg/L, ABG's showed pH 7.50, PCO₂ 29.2 mmHg, PO₂ 50 mmHg, %SO_{2c} 88%. Patient

maintained saturation at 89–91% with HFNC at 70 L/min & FiO₂ 0.7–0.8 on intermittent right and left lateral positioning. Inhalation of salmeterol and fluticasone combination was commenced along with other medication. In ICU he developed hypertension hence; tab. amlodipine was added along with other medication.

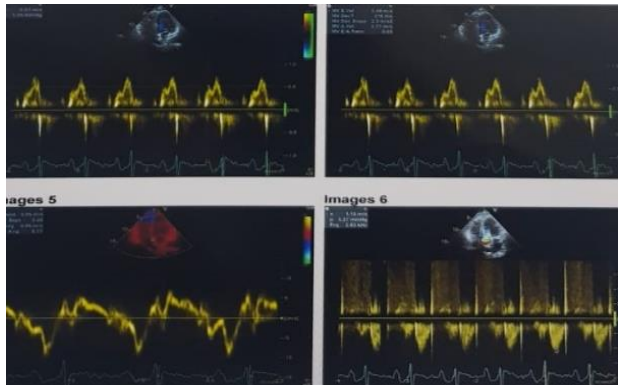
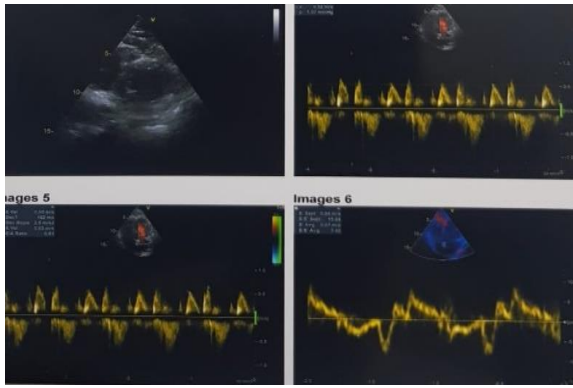
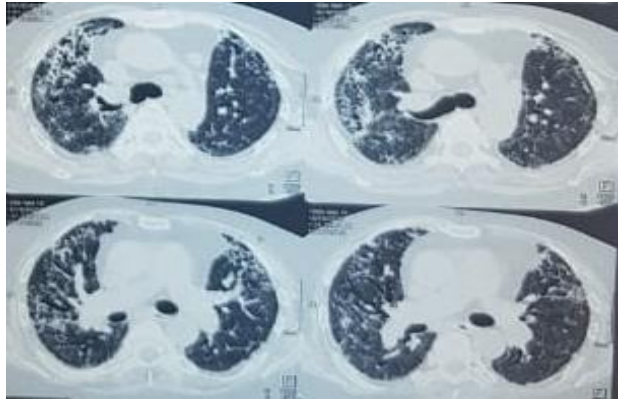
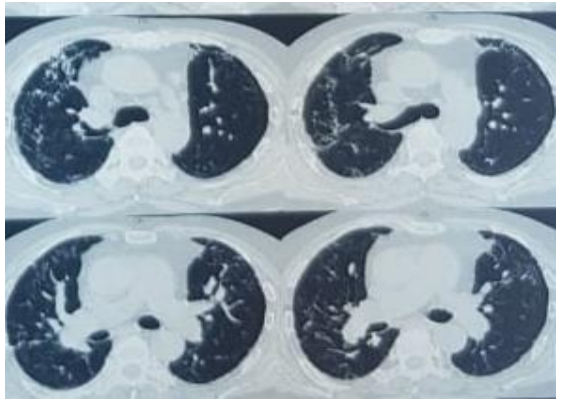
On August 2, 2020, saturation decreased further to 75–78%, with respiratory rate around 40 breaths/min. Then patient was shifted from HFNC to CTEX CPAP (a newly developed non-invasive oxygen delivery device approved by Medicines and Healthcare products Regulatory Agency (MHRA), at flow rate 10 L/min and PEEP 10 cmH₂O). However, as his condition deteriorated he was shifted from CTEX CPAP to non-invasive mechanical ventilation. Initial setting was PEEP 10 cmH₂O, pressure support 16 cmH₂O and FiO₂ 0.8–0.9. With this setting his SpO₂ was 92–93%, but saturation dropped sharply when he tried to change his position. Gradually his PEEP and pressure support were adjusted to keep his saturation around 93–95%. After almost one month of NIV support patient gradually improved and his pressure support was reduced down to PEEP 6 cmH₂O, and pressure support 10 cmH₂O. However, FiO₂ demand was still more than 0.5. On September 21, 2020, his ABG reports showed improvement in his parameters; pH–7.45, PCO₂–46, and PO₂–67 mmHg.

On September 23, 2020 the patient was shifted to BiPAP and NRM intermittently to prepare him to shift to post-COVID ward. After one week of trial patient could maintain his saturation with facemask at 8–1L of oxygen/min. He stayed 19 days in post-COVID ward. During that period baseline investigations including ABG's were done cmH₂O regularly and measures were taken accordingly. Patient got chest physiotherapy / breathing exercises three times a day along with passive body part movements and massages.

He was discharged from post-COVID ward on October 19, 2020. However, he was still on 4–5 L/min oxygen via face mask. Medications during discharge were; tab rivaroxaban for 45 days, tab amlodipine along with some vitamin and mineral supplements. Repeat HRCT of chest was done on December 19, 2020 which revealed more than 56% involvement of lung parenchyma in extensive pulmonary inflammatory lesions, fibrosis with multifocal consolidations. Pulmonologist was consulted and nintedanib, acetylcysteine and montelukast was

advised along with a repeat HRCT after one month. Breathing exercise and reconditioning exercises continued. At this stage, patient was on 3 L oxygen via nasal cannula, cap nintedanib was advised for another 1 month but was withdrawn after 15 days as liver enzymes increased. Patient was still on 2–3 L oxygen though nasal cannula. He was still unable to walk without assistance and do daily activities on his own. He suffered from severe anorexia, and was evaluated again to establish the cause.

On January 14, 2021, his ECG and echocardiography were done along with other base line investigations. ECG revealed fascicular block, poor progression of R wave and anterior ischemia. Echocardiography revealed moderate pulmonary hypertension (PASP 58 mmHg and LVEF 42%). After consultation with the cardiologist, he was prescribed frusemide, spironolactone, tab. carvedilol, tab. losartan potassium, tab ecosprin, and tab atorvastatin. A repeat HRCT at January 16, 2021 revealed scattered fibrotic

Table 1: Echo reports according to date	
January 23, 2021	April 3, 2021
Post-COVID status	Post-COVID status
Wall motion abnormality of LV and RV	Jerky septum
Tricuspid regurgitation (mild)	Tricuspid regurgitation (mild)
Moderate LV systolic dysfunction (LVEF 42 ± 3%)	Fair LV systolic function (LVEF 50–55%)
Moderate pulmonary hypertension (PASP 58 mmHg)	PASP 46 mmHg
Mild RV systolic dysfunction	Mild RV systolic dysfunction
LV diastolic dysfunction	LV diastolic dysfunction
Reduced, global, longitudinal strain of LV	
	
	

changes in more than 50% of the lung parenchyma with prominent bronchovascular markings. After 2 months, on repeat Echo and ECG, cardiac condition improved.

He was on 1 L oxygen through nasal cannula for 15 h daily. Now, he is able to walk without assistance and can perform his daily activities on his own. He does daily breathing exercise and reconditioning.

CT scan according to date:

HRCT Chest of 19th October, 2020 showed bilateral extensive inflammatory lesions, fibrosis with multifocal consolidations involving more than 56% of parenchyma.

Repeat HRCT on January 16, 2021, revealed bilateral extensive pulmonary inflammatory lesions, scattered fibrosis, septal thickening, and reticulations with multiple ground glass opacities involving more than 50% of the lung parenchyma.

3. Discussion

The long-term consequences of COVID-19 are not fully known. Most of the patients, who experienced 'mild' COVID-19 symptoms, do not require hospitalization. However, those who require hospitalization a significant number of them develop severe systemic, multi-organ disease and may suffer from post-COVID-19 sequelae. Residual effects of the acute COVID-19 may lead to Long COVID, a complex, multifactorial illness.

The National Institute for Health and Care Excellence (NICE) has published guidelines on post COVID-19 syndrome as signs and symptoms that are not explained by an alternative diagnosis which develop during or after a COVID-19 infection, continuing for more than 12 weeks.⁶ Those symptoms can affect any vital systems of the body and may fluctuate over time. Extensive lung damage by COVID-19 may cause pulmonary fibrosis in some patients.⁷ Hypercoagulable state and PE is most likely explained by complement-mediated micro vascular injury and immunothrombotic derangements, supported by autopsies.^{8,9} Extensive pulmonary macrophage activation, inflammation, diffuse alveolar and interstitial damage all contribute to pulmonary intravascular coagulopathy as well as altered adaptive immune responses, are probably the

pathophysiological mechanisms for the development of PE in COVID-19.¹⁰

In the current case micro vascular injury and marked pulmonary parenchymal abnormalities in combination may have had an important role in the development of PH. This patient developed extensive pulmonary fibrosis and moderate pulmonary hypertension after recovering from active disease. Hence he has to go through extensive pulmonary and cardiac rehabilitation. Even after 280 days of first symptoms appeared, patient still need one litre oxygen via nasal cannula to prevent permanent pulmonary vascular remodeling. Therefore, awareness of pulmonary hypertension as a complication of COVID-19 is warned.

4. Conflict of interest

None declared by the authors

5. Authors' contribution

All authors took part in the management of the patient as well as preparation of this manuscript.

6. References

1. European Centre for Disease Prevention and Control. ecdc.europa.eu; 2021. Available from: <http://ecdc.europa.eu/en/geographical-distribution-2019-ncov-cases>.
2. Singhal T. A Review of Coronavirus Disease-2019 (COVID-19). *Indian J Pediatr.* 2020 Apr;87(4):281-286. [PubMed] DOI: [10.1007/s12098-020-03263-6](https://doi.org/10.1007/s12098-020-03263-6)
3. Guan WJ, Ni ZY, Hu Y, Liang WH, Ou CQ, He JX, et al. Clinical characteristics of coronavirus disease 2019 in China. *N Engl J Med.* 2020 Apr 30;382(18):1708-1720. [PubMed] DOI: [10.1056/NEJMoa2002032](https://doi.org/10.1056/NEJMoa2002032)
4. Wijeratne T, Crewther S. Post-COVID 19 Neurological Syndrome (PCNS); a novel syndrome with challenges for the global neurology community. *J Neurol Sci.* 2020 Dec 15;419:117179. [PubMed] DOI: [10.1016/j.jns.2020.117179](https://doi.org/10.1016/j.jns.2020.117179)
5. Carfi A, Bernabei R, Landi F; Gemelli Against COVID-19 Post-Acute Care Study Group. Persistent symptoms in patients after acute covid-19. *JAMA.* 2020 Aug 11;324(6):603-605. [PubMed] DOI: [10.1001/jama.2020.12603](https://doi.org/10.1001/jama.2020.12603)
6. NICE. Common symptoms of ongoing symptomatic COVID-19 and post-COVID-19 syndrome | COVID-19 rapid guideline: managing the long-term effects of COVID-19 | guidance. Available from: <https://www.nice.org.uk/guidance/ng188/chapter/common-symptoms-of-ongoing-symptomatic-covid-19-and-post-covid-19-syndrome>

7. Wu J, Pan J, Teng D, Xu X, Feng J, Chen YC. Interpretation of CT signs of 2019 novel coronavirus (COVID-19) pneumonia. *Eur Radiol.* 2020 Oct;30(10):5455-5462. [PubMed] DOI: [10.1007/s00330-020-06915-5](https://doi.org/10.1007/s00330-020-06915-5)
8. Magro C, Mulvey JJ, Berlin D, Nuovo G, Salvatore S, Harp J, et al. Complement associated microvascular injury and thrombosis in the pathogenesis of severe COVID-19 infection: A report of five cases. *Transl Res.* 2020 Jun;220:1-13. [PubMed] DOI: [10.1016/j.trsl.2020.04.007](https://doi.org/10.1016/j.trsl.2020.04.007)
9. Ackermann M, Verleden SE, Kuehnel M, Haverich A, Welte T, Laenger F, et al. Pulmonary Vascular Endothelialitis, Thrombosis, and Angiogenesis in Covid-19. *N Engl J Med.* 2020 Jul 9;383(2):120-128. [PubMed] DOI: [10.1056/NEJMoa2015432](https://doi.org/10.1056/NEJMoa2015432)
10. McGonagle D, O'Donnell JS, Sharif K, Emery P, Bridgewood C. Immune mechanisms of pulmonary intravascular coagulopathy in COVID-19 pneumonia. *Lancet Rheumatol.* 2020 Jul;2(7):e437-e445. [PubMed] DOI: [10.1016/S2665-9913\(20\)30121-1](https://doi.org/10.1016/S2665-9913(20)30121-1)