

CASE REPORT

PAIN MANAGEMENT

A rare case of low backache (Bertolotti's syndrome)

Liaquat Ali ¹, Khaleel Ahmad ², Umer Ali ³

1. Prof, Department of Anesthesiology, Critical Care and Pain Medicine, Foundation University Medical College, Fauji Foundation Hospital, Rawalpindi, Pakistan.

2. Consultant Anesthesiologist/Pain Specialist, Department of Anesthesiology, Critical Care and Pain Medicine Foundation University Medical College, Fauji Foundation Hospital, Rawalpindi, Pakistan.

3. Registrar, Anesthesiology & Pain Medicine Anesthetist, Department of Anesthesiology, Critical Care and Pain Medicine Foundation University Medical College, Fauji Foundation Hospital, Rawalpindi, Pakistan.

Correspondence: Maj Gen (r) Professor Liaquat Ali; E-mail: liaquatanaes@gmail.com; Phone: +93 321 5836898

Abstract

Lumbosacral transition of L5 vertebra is an anatomical variation. Enlarged transverse process of L5 vertebra may form a pseudo joint with ilium or sacrum. This may lead to low back pain, especially in young adults due to change in biomechanical properties of the lumbar spine. This condition is referred to as Bertolotti's syndrome.

We present a case of 40 years old male surgeon with low backache not responding to oral and intravenous pain killers which prevented him from carrying out his daily routine activities. The pain was severe, excruciating and radiating to right buttock with Visual Analogue Scale (VAS) score ranging from 8/10. There was tenderness over right sacroiliac area provoked by deep palpation. Provisional diagnosis of right sacroilitis was made. Fluoroscopy revealed anomalous articulation between right enlarged L5 transverse process with ipsilateral ala of sacrum forming a pseudo arthrosis with maximum tenderness over it. Periarticular injection at pseudo joint with 0.1 % bupivacaine and of triamcinolone 40 mg was given under fluoroscope and confirmed with dye. There was immediate relief from pain. In young individuals with chronic low back pain diagnosis of Bertolotti's syndrome should also be kept in mind.

Key words: Low back pain; Bertolotti's syndrome; Visual Analogue Scale

Citation: Ali L, Ahmad K, Ali U. A rare case of low backache (Bertolotti's syndrome). *Anaesth pain intensive care* 2021;25(2):402-405. DOI: [10.35975/apic.v25i3.1508](https://doi.org/10.35975/apic.v25i3.1508)

Received: May 6, 2021, **Reviewed:** May 11, 2021, **Accepted:** May 20, 2021

1. Introduction

Bertolotti's syndrome was first described in 1917. It is characterized by an abnormal enlargement of the transverse process of the most caudal lumbar vertebra i.e. L5. This enlarged transverse process forms a pseudo joint by articulating with sacrum or ilium.¹ The articulation may be partial or total and unilateral or bilateral. The overall incidence of Bertolotti's syndrome is reported to be as 4–8% in cases of low back pain.² It is an important cause of low back pain in young individuals. There is a variety of opinions about treatment of Bertolotti's syndrome; however, no consensus has been developed yet. We present a symptomatic case of Bertolotti's syndrome treated

successfully with fluoroscopic guided local anesthetic and steroid injection.

2. Case report

A forty year old male presented to our pain clinic at Fauji Foundation Hospital Rawalpindi with a history of low back pain for the last 3 weeks. Pain started suddenly while doing heavy exercise. Pain started in low back radiating to right buttock and occasionally up to ipsilateral knee joint. There was no history of trauma. Pain intensity on VAS score was 8/10. The pain was hindering his daily routine activity. On physical examination, there was tenderness over right

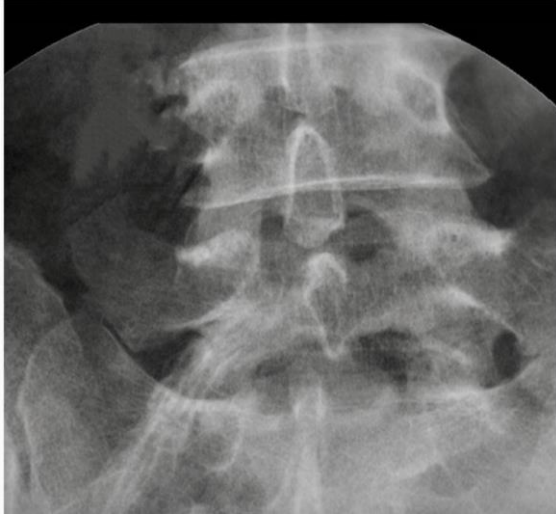

Figure 1: X-ray of lumbosacral region showing abnormal joint on both side

sacral and sacroiliac joint area provoked by superficial and deep palpation. Muscle power, sensations and reflexes were intact bilaterally in lower limbs. Patrick test, pelvic compression test and straight leg raising tests were negative.

Fluoroscopy revealed anomalous articulation between right enlarged L5 transverse process with ipsilateral ala of sacrum forming a pseudo arthrosis. On reexamination tenderness was more severe over pseudo arthrosis. A radiograph of the lumbar spine revealed a typical lumbosacral transition of L5 vertebra with large L5 right transverse process articulating with ala of sacrum (Figure 1). X-ray also demonstrated some degenerative changes of the pseudo arthrosis.

Treatment was planned by injecting local anesthetic and steroid by fluoroscopic guidance at pain clinic. Skin was prepared with antiseptic solution and draped in a sterile fashion. Quincke spinal needle 22 gauge was advanced between transverse process of L5 vertebra and ala of the sacrum under fluoroscopic guidance. Needle tip was confirmed (Figure 2 marked) and 0.5 ml of contrast medium – iohexol injection (Omnipaque™) was injected. After confirmation of contrast spread (Figure 3) 0.1 % bupivacaine and triamcinolone 40 mg (4 ml total volume) was injected. There was immediate relief from the pain. Patient was reassured and anti-inflammatory drugs advised for two weeks. At two weeks follow up he had complete relief from pain with VAS 0/10. His anti-inflammatory drug was stopped. At one month follow

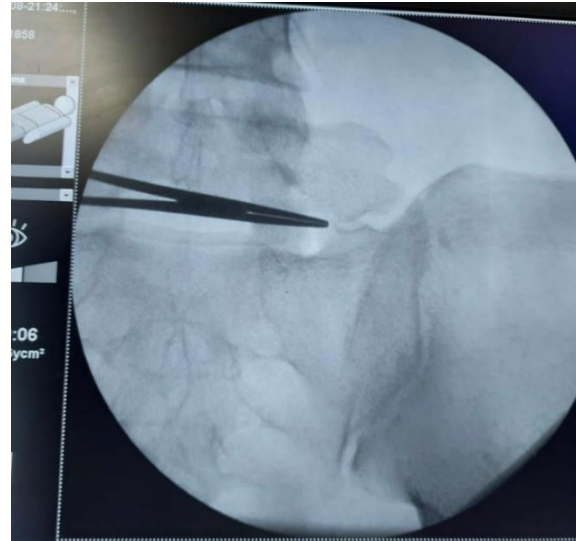


Figure 2: Fluoroscopic view of the site of the injection marked with the tip of the artery forceps

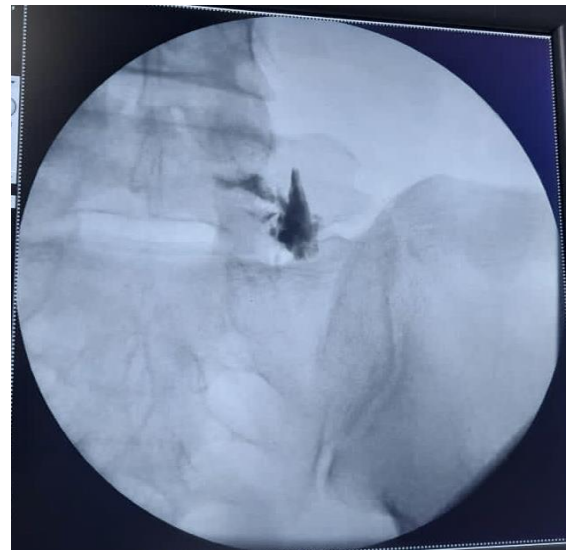


Figure 3: Fluoroscopic view of the contrast in the anomalous joint

up he had complete pain relief without any medication. He was instructed to come for follow up, whenever any symptoms reappear.

3. Discussion

Bertolotti was the first person who demonstrated anomalous anatomic enlargement of most caudal lumbar vertebra. Its enlarged transverse process may articulate with sacrum or ilium and cause low back pain. Bertolotti's syndrome may account for 4–8% cases of low back pain³ for adult patients and almost 11% for young⁴ individuals under 30 y of age. Quinlan

et al. reported even higher incidence of low back pain in young individuals with this syndrome.⁵

Definitive mechanism of pain in this syndrome is still unknown. One possible explanation is articulation of the transverse process and the sacral ala.^{6,7,8,9} Alternatively, degeneration of intervertebral disc at adjacent level may be another cause of low back pain.¹⁰ Elster et al. concluded that the incidence of spinal stenosis and degenerative disc disease was almost nine times higher at level adjacent to transitional vertebra.¹¹ K Ottani et al. also proposed extraforaminal stenosis secondary to hypertrophic transverse process.¹² These changes lead to abnormal biomechanical stress and cause low back pain. Vergauwen et al. demonstrated that abnormal transitional vertebra may not lead to degenerative changes; however, if degeneration occurs, it is more marked at supra adjacent level of transitional vertebra.¹³ We consider degeneration between transverse process and sacral ala was the cause of low back pain in our patient.

Direct infiltration of local anesthetic and steroid relieves pain in patients with Bertolotti's syndrome.¹⁴ Some authors even injected contralateral facet joint to enlarged transverse process of transitional vertebra.¹⁵

Santavirta et al. demonstrated that if there is no disc pathology and conservative treatment fails, surgical resection of the enlarged process may be tried. If transitional disc appears pathological then posterolateral fusion may be done.¹⁶

4. Conclusion

Bertolotti's syndrome should be considered in differential diagnosis, while investigating low back pain in young individuals. Conservative versus operative treatment is still debatable. In our case infiltration of local anesthetic and steroid into pseudoarthrosis under fluoroscopic guidance resulted in resolution of the symptoms.

5. Conflict of interest

None declared by the authors.

6. Authors' contribution

LA: Supervisor, managed the case, manuscript review
KA, UA: Managed the case, literature review, manuscript writing

7. References

1. Marks RC, Thulbourne T. Infiltration of anomalous lumbosacral articulations. Steroid and anesthetic injections in 10 back-pain patients. *Acta Orthop Scand*. 1991 Apr;62(2):139-41 [PubMed] DOI: [10.3109/17453679108999242](https://doi.org/10.3109/17453679108999242)
2. Quinlan JF, Duke D, Eustace S. Bertolotti's syndrome. A cause of back pain in young people. *J Bone Joint Surg* 2006;88:1183-6. [PubMed] [Free full text] DOI: [10.1302/0301-620X.88B9.17211](https://doi.org/10.1302/0301-620X.88B9.17211)
3. Brault JS, Smith J, Currier BL. Partial lumbosacral transitional vertebra resection for contralateral facetogenic pain. *Spine (Phila Pa 1976)* 2001;26:226-9 [PubMed] DOI: [10.1097/00007632-200101150-00020](https://doi.org/10.1097/00007632-200101150-00020)
4. Wiltse LL, Guyer RD, Spencer CW, Glenn WV, Porter IS. Alar transverse process impingement of the L5 spinal nerve: the far-out syndrome. *Spine* 1984;9:31-41 [PubMed] DOI: [10.1097/00007632-198401000-00008](https://doi.org/10.1097/00007632-198401000-00008)
5. Almeida DB, Mattei TA, Sória MG, Prandini MN, Leal AG, Milano JB, Ramina R. Transitional lumbosacral vertebrae and low back pain: diagnostic pitfalls and management of Bertolotti's syndrome. *Arq Neuropsiquiatr*. 2009 Jun;67(2A):268-72 [PubMed] [Free full text] DOI: [10.1590/s0004-282x2009000200018](https://doi.org/10.1590/s0004-282x2009000200018)
6. Manchikanti L, Cash KA, McManus CD, Pampati V, Benyamin RM. A randomized, double-blind, active-controlled trial of fluoroscopic lumbar interlaminar epidural injections in chronic axial or discogenic low back pain: results of 2-year follow-up. *Pain Physician*. 2013 Sep-Oct;16(5):E491-504 [PubMed] [Free full text]
7. Malham GM, Limb RJ, Claydon MH, Brazenor GA. Anterior pseudoarthrectomy for symptomatic Bertolotti's syndrome. *J Clin Neurosci*. 2013 Dec;20(12):1762-6. [PubMed] DOI: [10.1016/j.jocn.2013.02.018](https://doi.org/10.1016/j.jocn.2013.02.018)
8. Ugokwe KT, Chen TL, Klineberg E, Steinmetz MP. Minimally invasive surgical treatment of Bertolotti's Syndrome: case report. *Neurosurgery*. 2008 May;62(5 Suppl 2):ONSE454-5; discussion ONSE456.. [PubMed] DOI: [10.1227/01.neu.0000326034.77585.88](https://doi.org/10.1227/01.neu.0000326034.77585.88)
9. Mitra R, Carlisle M. Bertolotti's syndrome: a case report. *Pain Pract*. 2009 Mar-Apr;9(2):152-4. [PubMed] [Free full text] DOI: [10.1111/j.1533-2500.2008.00253.x](https://doi.org/10.1111/j.1533-2500.2008.00253.x)
10. Aihara T, Takahashi K, Ogasawara A, Itadera E, Ono Y, Moriya H. Intervertebral disc degeneration associated with lumbosacral transitional vertebrae: a clinical and anatomical study. *J Bone Joint Surg Br*. 2005 May;87(5):687-91 [PubMed] [Free full text] DOI: [10.1302/0301-620X.87B5.15727](https://doi.org/10.1302/0301-620X.87B5.15727)
11. Elster AD. Bertolotti's syndrome revisited: transitional vertebrae of the lumbar spine. *Spine* 1989;14:1373-7. [PubMed]
12. Otani K, Konno S, Kikuchi S. Lumbosacral transitional vertebrae and nerve-root symptoms. *J Bone Joint Surg Br*. 2001 Nov;83(8):1137-40 [PubMed] DOI: [10.1302/0301-620x.83b8.11736](https://doi.org/10.1302/0301-620x.83b8.11736)

13. Vergauwen S, Parizel PM, Van Breusegem L, Van Goethem JW, Nackaerts Y, Van den Hauwe L, De Schepper AM: Distribution and incidence of degenerative spine changes in patients with a lumbosacral transitional vertebra. *Eur Spine J* 1997;6:168–172 [[PubMed](#)] [[Free full text](#)] DOI: [10.1007/BF01301431](https://doi.org/10.1007/BF01301431)
14. Jancuska JM, Spivak JM, Bendo JA. A Review of Symptomatic Lumbosacral Transitional Vertebrae: Bertolotti's Syndrome. *Int J Spine Surg*. 2015 Jul 29;9:42. [[PubMed](#)] [[Free full text](#)] DOI: [10.14444/2042](https://doi.org/10.14444/2042)
15. Brault JS, Smith J, Currier BL: Partial lumbosacral transitional vertebra resection for contralateral facetogenic pain. *Spine* 2001;26:226–229 [[PubMed](#)] DOI: [10.1097/00007632-200101150-00020](https://doi.org/10.1097/00007632-200101150-00020)
16. Santavirta S, Tallroth K, Ylinen P, Suoranta H: Surgical treatment of Bertolotti's syndrome. Follow up of 16 patients. *Arch Orthop Trauma Surg* 1993;112:82–87 [[PubMed](#)] DOI: [10.1007/BF00420261](https://doi.org/10.1007/BF00420261)