



Can procoagulant use lead to hypercoagulable state?; A case of intravascular and intracardiac thrombosis after protamine administration

Ahmed D. Abu Zaid¹, Muhammad Atif Malik², Abdulaziz Alhossan³

ABSTRACT

¹Director, Department of Cardiac Anesthesia, Prince Sultan Cardiac Centre, Riyadh, (KSA)

²Consultant Cardiac Anesthesiologist, Prince Sultan Cardiac Centre, Riyadh, (KSA)

³Department of Cardiac Surgery, Prince Sultan Cardiac Centre, Riyadh, (KSA)

Correspondence: Dr Ahmed D. Abu Zaid, Director, Department of Cardiac Anesthesia, Prince Sultan Cardiac Centre, Riyadh, (KSA); Phone: +996 114783000, Ext: 88551; E-mail: AAbuZaid@pscc.med.sa

Received: 27 Sep 2018

Reviewed: 16 Oct, 30 Oct 2018

Accepted: 6 Dec 2018

Antifibrinolytics e.g. tranexamic acid (TA) are frequently used during cardiac surgical procedures on cardiopulmonary bypass for supporting hemostasis and reducing blood transfusion requirement. A 42 years old lady with chronic atrial fibrillation (AF), severe mitral regurgitation (MR) and tricuspid regurgitation (TR) underwent mitral valve replacement (MVR) and tricuspid valve (TV) repair. The anesthetic and surgical management was uneventful but soon after the reversal of heparin with protamine, the patient developed intracardiac and intra-arterial thrombosis extending to abdominal aorta. The patient received TA bolus at induction followed by infusion during the cardiopulmonary bypass. The safety of routine prophylactic use of antifibrinolytic was questioned and routine use of screening tools e.g. thromboelastometry suggested.

Key words: Antifibrinolytics; Tranexamic acid; Hemostasis; Cardiopulmonary bypass; Blood transfusion; Thromboelastometry

Citation: Abu Zaid AD, Malik MA, Alhossan AA. Can procoagulant use lead to hypercoagulable state?; A case of intravascular and intracardiac thrombosis after protamine administration. *Anaesth Pain & Intensive Care* 2018;22(4):518-521

INTRODUCTION

Antifibrinolytics are frequently used during cardiac surgical procedures on cardiopulmonary bypass for supporting hemostasis and reducing blood transfusion requirement.¹ Effective hemostasis is extremely important for surgical procedures including the cardiac surgery.² It is regulated very delicately to maintain a fine balance between controlling bleeding in response to primary injury and preventing hypercoagulability.³ Most often this balance is tilted towards excessive bleeding and mandates the use of agents to prevent it. There are numerous such agents, which are available in clinical practice and most of them have been found to be effective in controlling bleeding and reducing the use of blood products.^{4,5} Cardiopulmonary bypass is a part and parcel of the

cardiac surgery. Its use however, alters the hemostatic balance and predisposes the patients to the risk of coagulopathy. The pathophysiology of bleeding often after CPB is multifactorial and complex involving hypothermia, endothelial cell and tissue injury, activation of platelets and coagulation factors, acute hemodilution and exposure to foreign surface. The thrombin level also increases despite adequate systemic heparinization.

Tranexamic Acid (TA) is one of such agent which is antifibrinolytic and acts by binding with plasminogen and prevents its conversion to plasmin.⁶ This minimizes the increase in primary fibrinolysis during cardiopulmonary bypass (CPB). TA also preserves the platelet function by reducing plasmin effect on platelets and glycoprotein 1b receptor.^{7,8,9}

procoagulant induced hypercoagulable state

Despite having all the beneficial effects, can it make the blood hypercoagulable and adversely affect the outcome of the surgery? The answer to this question is not clear and in one of the reported incident, it was associated with dosing error.¹⁰ We present a case report of induced hypercoagulable state in a female patient after routine dose of TA.

CASE REPORT

A 42 years old lady weighing 82 kg was booked for mitral valve replacement (MVR) and tricuspid valve (TV) repair for her severe mitral regurgitation (MR) and tricuspid regurgitation (TR). Preanesthetic assessment showed her history to be negative for asthma, hypertension or diabetes mellitus. She had chronic atrial fibrillation (AF) and was on warfarin for the last 8 years. She had had two cesarean sections under regional anesthesia. She was on hormonal oral contraceptives for her polycystic ovary syndrome for 6 years. Other medications included beta blockers and diuretics. Preoperative echo showed severe MR, severe TR, normal LV systolic function. EF was 55%. Estimated PASP was 40 mmHg. Her physical examination and routine lab investigations were mostly unremarkable.

In the operating room (OR), after applying the routine monitors, an arterial line was inserted in the left radial artery and 16G cannula in the right arm. Induction was done with midazolam 3 mg, etomidate 6 mg, and fentanyl 250 μ g. Another dose of 250 μ g fentanyl was given at the time of intubation. Airway was secured with endotracheal tube (ETT) no. 7.5 mm and rocuronium 80 mg was used for muscle relaxation. 800 mg of TA bolus was also given as antifibrinolytic. Swan Ganz catheter was inserted in the right internal jugular vein alongwith 7.5 Fr triple lumen central venous line. Trans-esophageal echocardiography (TEE) was done by the cardiologist and it confirmed the pre anesthetic study. She received 35,000 IU of heparin before the aortic and caval cannulation. Activated clotting time (ACT) was found to be 460 sec (using HEMOCHRON[®] Jr. Signature+). CPB was initiated and continued smoothly while the temperature was lowered to 32° C. Anesthesia was maintained with propofol 25-30 μ g/kg/h, fentanyl 2-5 μ g/kg/h and TA @ 160 mg/h as antifibrinolytic. The cross clamp time was 91 min and CPB time was 113 min; the patient was warmed to 36° C. ACT was measured at regular intervals and it was > 408 sec throughout the conduct of CPB. Her hemoglobin (Hb) dropped to 8.2 gm/dL and near the weaning, 1 unit of packed red cells was added in the prime. The urine output before the CPB was 600 ml and 1200 ml at the CPB. The heart was irritable and developed ventricular fibrillations after the cross clamp removal. MgSO₄ 2 gm was given via CPB and

defibrillation was done with 20 J. The cardiac rhythm stabilized after that. Atrial pacing with a rate of 90/min was started along with infusions of dobutamine 5 μ g/kg/min and noradrenaline 0.1 μ g/kg/min. After about five minutes, the CPB flow was reduced and heart allowed to eject blood. TEE showed minimal paravalvular leak around the mitral valve and good repair of the tricuspid valve. The radial arterial line suddenly appeared to be dampened for no obvious reason and in order to wean the patient from CPB and adjust the inotropic support, it was decided to measure the aortic pressures directly by inserting a needle. There was a discrepancy of 15 mmHg in the systolic and 5 mmHg in the mean BP. The arterial blood gas (ABG) level was acceptable except for lactate level of 4 mmol/L. ACT was checked at that time to be 439 sec. The protamine was started and the surgeons and perfusionists were notified at the 30%, 50% and 75% of its administration to adjust the CPB settings accordingly. The dose was completed over 10 min (total dose of 350 mg) and ACT after that was 154 sec.

About 10 min following that, there was a sudden drop in the Near Infrared Spectroscopy (NIRS, INVOS SOMANETICS) recording to 32 (baseline value 66) placed over the right side of the forehead and later disappearance of the A line tracing both for the aortic and radial site with no aspiration. ST segment elevation was also noted in leads I, II, aVL and V. The surgeons were notified immediately and it was decided to go back on CPB as the heart rate was slowing down and cardiac chambers getting distended. Patient was reheparinized and cannulated. (ACT 618 sec). Venous blood gas (VBG) values showed normal parameters except for HCO₃ = 17.9 mmol/L, BE = -8.3 and lactate going up to 5.9. The needle taken out of the aorta had a small clot in its tip. The radial arterial line showed some tracing and free aspiration again after the heparin. The NIRS recording dropped to 14. Cardiologist was called in again for TEE which demonstrated severe LV (EF 10%) and RV dysfunction. Mobile thrombus was noted in left atrium (LA) and LV (Figure 1). Descending thoracic and abdominal aorta had large thrombi at multiple places (Figure 2). The CPB alarmed repeatedly for higher line pressures and low reservoir volume. 4 units of pRBCs, 500 ml of ringer lactate solution and 500 ml of 5% albumin was added in the prime but there was no hemodynamic and metabolic improvement rather the patient started to bleed excessively. She was later put on ECMO and transferred to ICU where she succumbed after 4 hours.

DISCUSSION

The exact cause of intra vascular thrombosis

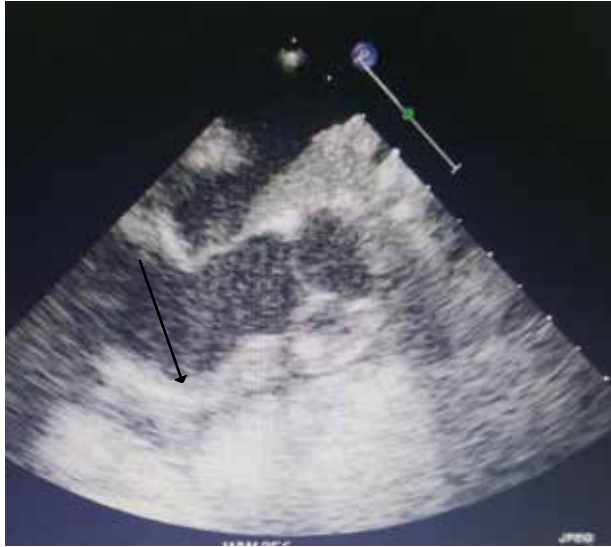

Figure 1: The transesophageal echocardiographic image demonstrating the presence of newly formed clot in the LV cavity. LA cavity also showing the presence of clot

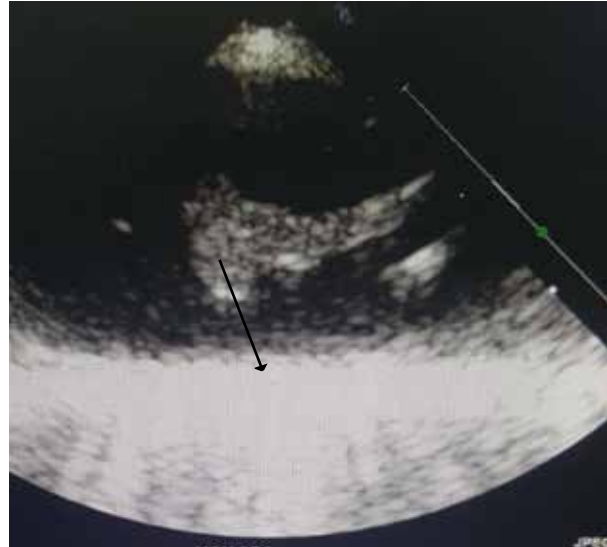


Figure 2: Transesophageal echocardiographic image showing the presence of clot in the thoracic aortic arch

is unclear especially after the completion of protamine. A few reports of similar incidence of intravascular thrombosis have been published in which antifibrinolytics, e.g. aprotinin and epsilon aminocaproic acid (EACA) were thought to be contributing, but none ever implicated TA.^{11,12} The thrombophilia work up was carried out in the ICU. APC resistance was found to be > 300 sec (which may point towards factor V Leiden) but as she was fully heparinized, the value of this result became questionable. The family refused to permit the autopsy which further mystified the etiology.^{13,14} The use of tranexamic acid gained popularity after the withdrawal of aprotinin. Increased incidence of mortality and seizures have been reported but none of intravascular thrombosis.¹⁵ A meta-analysis including 10,488 patients in 129 trials showed its use has been associated with reduction in blood transfusion by a third whereas its effects on myocardial infarction, stroke, deep vein thrombosis and pulmonary embolism could not be demonstrated.¹⁶

The patient may have some undiagnosed thrombophilia; hereditary (Factor V Leiden) or acquired (contraceptive related increase in fibrinogen

level and activity of factor VII and X or warfarin related decrease in Protein C). The three factors that were labelled by Virchow for intravascular thrombosis namely; vessel injury, coagulation state and alteration in blood flow are usually seen in patients undergoing procedures on CPB and concomitant use of antifibrinolytics in those who might have thrombophilia can possibly lead to intravascular thrombosis.

CONCLUSION

Our case report raises a question over here; should the antifibrinolytics be routinely administered during surgeries on CPB? Now-a-days, routine point of care (POC) testing like thromboelastography and thromboelastometry (ROTEM), especially during cardiac surgeries, are strongly advocated.

Conflict of interest: Nil declared by the authors

Authors' contribution:

AZAD: Manuscript Evaluation & Editing _

MAM: Manuscript Writing & Literature Review _

AAH: Literature Review for Discussion

REFERENCES

1. McIlroy DR, Myles PS, Phillips LE, Smith JA. Antifibrinolytics in cardiac surgical patients receiving aspirin: a systematic review and meta-analysis. *Br J Anaesth.* 2009;102(2):168-78. [PubMed] DOI: [10.1093/bja/aen377](https://doi.org/10.1093/bja/aen377)
2. Villanueva, M. Introduction: effective hemostasis in surgery. *AORN J.* 2008;88(3):S1. [PubMed] DOI: [10.1016/j.aorn.2008.08.012](https://doi.org/10.1016/j.aorn.2008.08.012)
3. Gale AJ. Continuing education course #2: current understanding of hemostasis. *Toxicol Pathol.* 2011;39(1):273-80. [PubMed] DOI: [10.1177/0192623310389474](https://doi.org/10.1177/0192623310389474)
4. Henry DA, Carlless PA, Moxey AJ, O'Connell D, Stokes BJ, Fergusson DA, et al. Anti-fibrinolytic use for minimizing perioperative allogenic blood transfusion. *Cochrane Database Sys Rev.* 2011. 19;(1):CD001886. [PubMed] DOI: [10.1002/14651858.CD001886.pub3](https://doi.org/10.1002/14651858.CD001886.pub3)
5. Ortmann E, Besser MW, Klein AA. Antifibrinolytic agents in current anaesthetic practice. *Br J Anaesth.* 2013;111(4):549-63. [PubMed] DOI: [10.1093/bja/aet154](https://doi.org/10.1093/bja/aet154)
6. Roberts I, Prieto-Merino D, Manno D. Mechanism of action of tranexamic acid in bleeding trauma patients: an exploratory analysis of data from the CRASH-2 trial. *Crit Care.* 2014;18(6):685. [PubMed] DOI: [10.1186/s13054-014-0685-8](https://doi.org/10.1186/s13054-014-0685-8)
7. Weber CF, Gorlinger K, Byhahn C, Moritz A, Hanke AA, Zacharowski K, et al. Tranexamic acid partially improves platelet function in patients treated with dual anti platelet therapy. *Eur J Anaesthesiol.* 2011;28(1):57-62. [PubMed] DOI: [10.1097/EJA.0b013e32834050ab](https://doi.org/10.1097/EJA.0b013e32834050ab)
8. Ramalingam, G, Jones N, Besser M. Platelets for anaesthetists—part 1: physiology and pathology. *BJA Education.* 2016;16(4):134-9. DOI: [10.1093/bjaed/mkv027](https://doi.org/10.1093/bjaed/mkv027)
9. Achneck HE, Sileshi B, Parikh A, Milano CA, Welsby IJ, Lawson JH. Pathophysiology of bleeding and clotting in the cardiac surgery patient: from vascular endothelium to circulatory assist device surface. *Circulation.* 2010;122(20):2068-77. [PubMed] DOI: [10.1161/CIRCULATIONAHA.110.936773](https://doi.org/10.1161/CIRCULATIONAHA.110.936773)
10. Upadhyay SP, Mallick PN, Jagia M, Singh RK. Acute arterial thrombosis associated with inadvertent high dose of tranexamic acid. *Indian J Crit Care Med.* 2013;17(4):237-9. [PubMed] DOI: [10.4103/0972-5229.118443](https://doi.org/10.4103/0972-5229.118443)
11. Ramsay MA, Randall HB, Burton EC. Intravascular thrombosis and thromboembolism during liver transplantation: antifibrinolytic therapy implicated? *Liver Transpl.* 2004;10(2):310-4. [PubMed] DOI: [10.1002/lt.20064](https://doi.org/10.1002/lt.20064)
12. Bhandary SP, Papadimos TJ, Essandoh MK, Apostolakis J. Massive intracardiac thrombosis during coronary artery bypass grafting surgery. *Int J Crit Illn Inj Sci.* 2015;5(1)56-8. [PubMed] DOI: [10.4103/2229-5151.152347](https://doi.org/10.4103/2229-5151.152347)
13. Bates SM, Greer IA, Middeldorp S, Veenstra DL, Prabalos AM, Vandvik PO. VTE, Thrombophilia, Antithrombotic Therapy, and Pregnancy: Antithrombotic Therapy and Prevention of Thrombosis, 9th ed: American College of Chest Physicians Evidence-Based Clinical Practice Guidelines. *Chest.* 2012;141(2 Suppl):e691S-e736S. [PubMed] DOI: [10.1378/chest.11-2300](https://doi.org/10.1378/chest.11-2300)
14. Pruller F, Weis EC, Raggam RB, Cervar-Zivkovic M, Renner W, Wagner J, et al. Activated protein C resistance assay and factor v Leiden. *N Engl J Med.* 2014;371(7):685-6. [PubMed] DOI: [10.1056/NEJMc1405664](https://doi.org/10.1056/NEJMc1405664)
15. Lecker I, Wang DS, Whissell PD, Avramescu S, Mazer CD, Orser BA. Tranexamic acid associated seizures: causes and treatment. *Ann Neurol.* 2016;79(1):18-26. [PubMed] DOI: [10.1002/ana.24558](https://doi.org/10.1002/ana.24558)
16. Ker K, Edwards P, Perel P, Shakur H, Roberts I. Effect of tranexamic acid on surgical bleeding: systematic review and cumulative meta-analysis. *BMJ.* 2012;344:e3054. [PubMed] DOI: [10.1136/bmj.e3054](https://doi.org/10.1136/bmj.e3054)

