



## Digital imaging as an objective airway assessment: A pilot study measuring tongue and unoccupied area in the oral cavity in patients undergoing thyroid surgery

Yvon Bryan, MD<sup>1</sup> and Kathleen N. Johnson, BS<sup>1</sup>, Jonathan Krebs, BS<sup>1</sup>, Payton Leech, MD<sup>1</sup>, Scott Rosenthal, MD<sup>1</sup>, Hannah M Harris, BS<sup>1</sup>, Jennifer Cannon, MD<sup>2</sup>

### ABSTRACT

**Objective:** The primary aim of our study was to develop an alternative airway exam to calculate the size and shape of the tongue, the unoccupied area of the oral cavity, and the ratio of unoccupied area to the entire oral cavity in patients with thyroid disease. A secondary aim was to compare the ratio of unoccupied area of the oral cavity to the Mallampati classification.

**Methodology:** An IRB-approved prospective observational study was performed at Wake Forest Baptist Health in patients undergoing thyroid/parathyroid surgery who were 18 and older, and had an anticipated difficult airway indicated either by the physical exam, previous history, or planned use of a specialized airway device. Awake intubations or tracheostomies were excluded. Demographic data were collected including the airway exam (Mallampati classification, oral aperture, thyromental distance, neck range of motion) and a picture of the oral cavity with the tongue protruding was captured. Digital imaging analysis was performed with ImageJ to measure the area of the tongue, the unoccupied area of the oral cavity, and the entire oral cavity area. The ratio of unoccupied area to the entire oral cavity was calculated and correlated to the Mallampati classification.

**Results:** Eleven patients undergoing thyroid surgery were included in analysis. There was a wide variation in the size and shape of the tongue, leading to different unoccupied areas of the oral cavity and different ratios of unoccupied area to the entire oral cavity area. There was a negative correlation between Mallampati class and the ratio of unoccupied area ( $r = -0.696$ ). Unoccupied area ratios  $< 18$  were correlated with Mallampati III/IV while that  $> 36$  were correlated with Mallampati I; the distinction between Mallampati I and II was harder to define.

**Conclusion:** We found that the ratio of unoccupied area to that of the entire oral cavity may be classified similarly to the Mallampati class and may quantify the distinction between Mallampatis I and III. The use of digital imaging to measure the size and shape of the tongue and the unoccupied area of the oral cavity may provide a quick and reliable alternative method to predict difficult intubation.

**Key words:** Digital Imaging; Diagnostic Techniques and Procedures; Diagnostic Imaging; Tongue; Airway Assessment; Thyroid, Classification

**Citation:** Bryan Y, Johnson KN, Krebs J, Leech P, Rosenthal S, Harris HM, Cannon J. Digital imaging as an objective airway assessment: A pilot study measuring tongue and unoccupied area in the oral cavity in patients undergoing thyroid surgery. *Anaesth Pain & Intensive Care* 2018;22(4):438-443

<sup>1</sup>Department of Anesthesiology, Wake Forest School of Medicine, Winston-Salem, NC 27157, (USA)

<sup>2</sup>Department of General Surgery, Wake Forest School of Medicine, Winston-Salem, NC 27157, (USA)

**Correspondence:** Yvon F. Bryan, MD, Department of Anesthesiology, Wake Forest School of Medicine, Medical Center Boulevard, Winston-Salem, NC 27157-1009 (USA);

Ph: 1+336-716-4498; E-mail: [ybryan@wakehealth.edu](mailto:ybryan@wakehealth.edu)

**Received:** 20 Sep 2018

**Reviewed:** 17 Nov 2018

**Corrected & Accepted:** 30 Nov 2018

## INTRODUCTION

Mallampati classification offers a quick airway assessment tool that may predict the likelihood of vocal cord visualization with a Macintosh 3 blade based on the visibility of the patient's uvula and faucial pillars.<sup>1</sup> However, it does not assess anatomical features of the oral cavity, such as the size and shape of the tongue, or the unoccupied area remaining in the oral cavity. A large tongue and/or a small unoccupied area decreases the amount of available space for the clinician to manipulate the laryngoscope blade and expose the glottic opening. Mallampati's inability to take this space into account may contribute to its ability to identify only 35% of patients with difficult intubations.<sup>2</sup> A more comprehensive airway examination capturing quantitative information regarding the size and shape of the tongue, along with the unoccupied area (space available for blade manipulation) in the oral cavity, might augment the ability to predict difficult airways preoperatively, and therefore, may facilitate placement of the endotracheal tube. We have previously identified Digital Imaging (DI) software as a tool that can provide a quick, objective, and reliable means of airway assessment.<sup>3</sup>

Difficulty in intubation with patients undergoing thyroidectomies and/or parathyroidectomies may be complicated due to the pathology accompanying thyroid disease. The presence of thyroid-specific features, such as goiter, malignancy, or tracheal deviation and compression may add to the difficulty.<sup>4-7</sup> Although it remains unclear what role these thyroid-specific features may have on intubation, the ability to predict difficult intubation in these patients preoperatively is imperative for the selection of airway device and technique.<sup>4-7</sup>

The aims of this study were to use DI as an alternative airway exam to calculate the size and shape of the tongue, the unoccupied area in the oral cavity, and the ratio of unoccupied area to the entire oral cavity in patients with thyroid disease. A secondary aim was to compare the ratio of unoccupied area to the observed Mallampati score.

## METHODOLOGY

After obtaining approval from the Wake Forest University's Health Sciences Institutional Review Board, a prospective observational study with written informed consent from adult patients undergoing surgery for thyroid/parathyroidectomies with an expected difficult airway (DA), either from previous history, the physical exam, and/or the planned use of a specialized airway device, was performed. Exclusion criteria included awake intubation or tracheostomy. A DA from the exam included: Mallampati classification III/IV, decreased neck range of motion,

thyromental distance < 3 finger breadths, and/or oral aperture < 3 finger breadths.

Demographic data were recorded before induction of anesthesia, and included age, weight, height, body mass index (BMI), American Society of Anesthesiologist (ASA) classification, Mallampati classification, neck range of motion, thyromental distance, and oral aperture. An image of each patient was taken on an encrypted, password protected Apple iPad. Each image contained the frontal view of the oral cavity with the tongue maximally protruded. Within the plane of the mouth opening, a metric ruler depicting centimeters was placed beside the oral cavity.

For Digital Imaging analysis, ImageJ, a free National Institutes of Health (NIH) software available for MAC, Windows, and Linux operating systems, was downloaded from <http://imagej.nih.gov/ij/download.html> and installed on an encrypted computer. Microsoft Excel was used in conjunction with ImageJ to quickly calculate the ratio of unoccupied area to the entire oral cavity for each patient. Each image was analyzed by the same user three times, and the average of those three measurements was used for analysis (see Appendix 1).

### Statistical Analysis:

Univariate analysis was performed to evaluate the association between Mallampati score and the ratio of unoccupied area to the entire oral cavity. A Pearson coefficient were calculated for the relationship between the Mallampati classification and the ratio of unoccupied area. A Pearson coefficient was also calculated for the relationship between the Mallampati classification and a ranking of the ratio of unoccupied area between 1-3 based on the 1st and 3rd quartiles. Linear regression was performed and a  $p < 0.05$  was considered significant.

## RESULTS

### Demographics

Eleven patients were included and analyzed. See Table 1 for demographic data.

Airway assessment related observations and measurements are given in Table 2.

### Digital Imaging Analysis

The mean  $\pm$  standard deviation (range) of the entire oral cavity area was  $27.7 \pm 11.7$  (8.4-48.6)  $\text{cm}^2$ . That of the area of the tongue was  $19.6 \pm 10.3$  (7.4-41.4)  $\text{cm}^2$  and of the unoccupied area was  $6.7 \pm 4.7$  (0.6-18.1)  $\text{cm}^2$ . The ratio of unoccupied area to the entire oral cavity was  $24.39 \pm 13.03$  (2.08-40.44). See Table 3 for digital imaging measurements.

**Table 1: Demographic data**

Parameter	Mean ± SD (range)
Age (years)	62 ± 19 (20-88)
Weight (kg)	72.3 ± 11.8 (53.1-89.5)
Height (m)	1.64 ± 0.07 (1.52-1.73)
BMI (kg/m <sup>2</sup> )	26.9 ± 3.8 (22.1-32.8)
ASA	n (%)
2	2 (18.2)
3	7 (63.6)
4	2 (18.2)

**Table 2: Airway Assessment**

Parameter	n (%)
<b>Mallampati Class</b>	
I/II	8 (72.7)
III/IV	3 (27.3)
<b>Neck Range of Motion</b>	
All	9 (81.8)
Decreased	2 (18.2)
<b>Thyromental Distance (FB)</b>	
≥ 3	8 (72.7)
<3	3 (27.3)
<b>Oral Aperture (finger breadths)</b>	
≥ 3	10 (90.9)
< 3	1 (9.1)

The size of the tongue and the ratio of unoccupied area had an inverse relationship (Figure 1). The ratio of unoccupied area for each patient is displayed in Figure 2.

The larger the tongue is, the smaller the ratio of unoccupied area will be, meaning there is less empty space available for an airway device during intubation

**Correlation between Digital Imaging Analysis and Mallampati Classification**

The ratio of unoccupied area of the oral cavity had a negative correlation with the Mallampati classification with a Pearson correlation coefficient of -0.696 (see Figure 3). An ANOVA analysis for the regression model yielded an F statistic of 8.44 and p-value of 0.017. There was a Pearson

**Table 3: Digital imaging analysis**

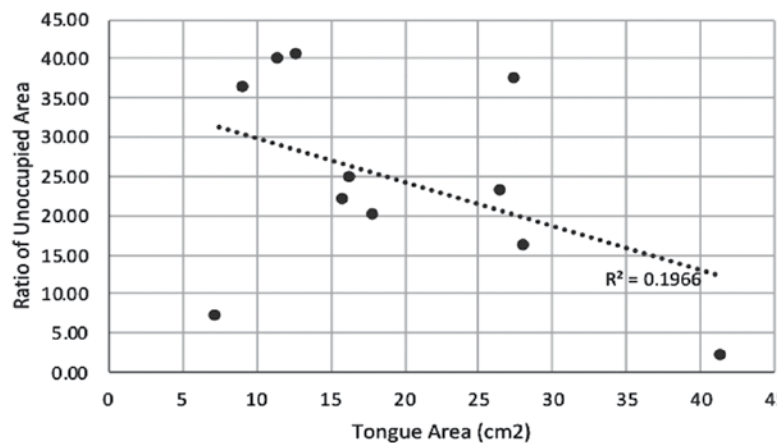
Subject	Area of Entire Oral Cavity CM <sup>2</sup>	Area of Tongue CM <sup>2</sup>	Area of Teeth CM <sup>2</sup>	Unoccupied Area CM <sup>2</sup>	Ratio of Unoccupied Area to Entire Oral Cavity
1	42.284	41.437	0	0.88	2.08
2	24.169	12.823	1.313	9.774	40.44
3	26.698	16.424	3.609	6.557	24.56
4	21.265	15.974	0.304	4.673	21.98
5	8.394	7.424	0	0.591	7.04
6	35.76	26.673	0.51	8.184	22.89
7	19.422	11.633	0.214	7.76	39.95
8	35.189	28.281	1.196	5.631	16.00
9	23.701	18.09	0.753	4.736	19.98
10	48.574	27.632	2.599	18.111	37.29
11	18.805	9.287	2.642	6.781	36.06

*Ratio of Unoccupied Area to the Entire Oral Cavity*

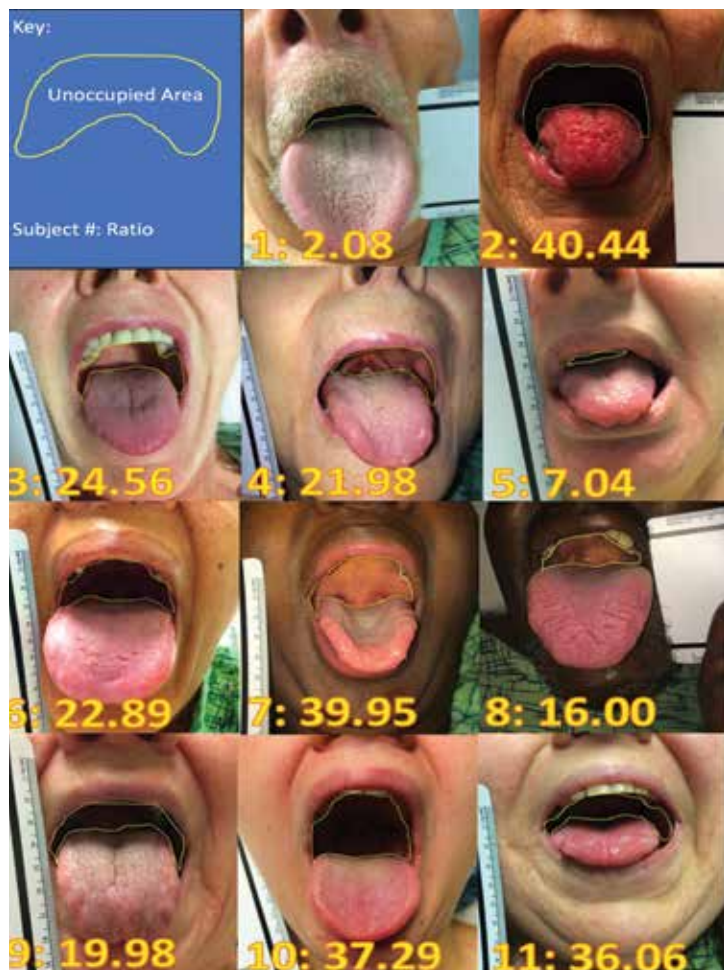correlation coefficient of -0.663 when the ratios of unoccupied area were ranked 1-3. The first quartile was 17.99, so ratios < 18 were ranked 1. The third quartile was 36.7, so ratios > 36 were ranked 3. Ratios in between these quartiles were ranked 2.

**DISCUSSION**

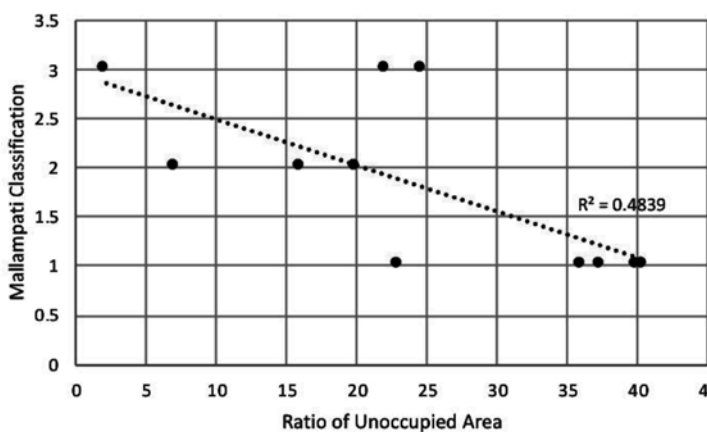
The results of our study suggest that significant variation exists in the size and shapes of tongues, resulting in different unoccupied areas of the oral cavity and ratios of unoccupied area to the entire oral cavity. We found a correlation between the Mallampati classification and the ratio of unoccupied area (UO). On one end of the spectrum, a Mallampati III/IV was



**Figure 1: The negative correlation between tongue area and the ratio of unoccupied area to the entire oral cavity (R<sup>2</sup>=0.1966).**



**Figure 2:** The variability between the size and shape of the tongue, as well as the unoccupied area. The unoccupied area is outlined in yellow, using the ImageJ software, and the first number represents the subject number of the patient followed by the ratio of unoccupied area to the entire oral cavity



**Figure 3:** The negative correlation between the ratio of unoccupied area to the Mallampati classification ( $R^2=0.4839$ ). Smaller unoccupied area ratios are correlated with higher Mallampati classifications, indicating a predictor for difficult intubation

associated with UO ratios < 18 (ranked 1). On the other end, a Mallampati I was associated with UO ratios > 36 (ranked 3). The distinction between Mallampati I and II was harder to define. Assuming normal distribution, UO ratios may be scored on a 1-3 scale in a manner similar to that of Mallampati with the added benefit of a quantitative (ie UO ratio < 18) rather than a qualitative (visibility of the faucial pillars) cutoff.

We observed that measuring oral cavity dimensions with digital imaging had high levels of inter and intraobserver agreement, whereas Mallampati scoring has significant variation among different observers.<sup>2</sup> With such high levels of interobserver disagreement, the ability of the Mallampati classification to predict difficult airway incidence was reduced. Adamus et al. showed that interobserver disagreement contributed to the low sensitivity of Mallampati, partially explaining why only 35% of patients with difficult airways were identified as having Mallampati scores of III or IV.<sup>2</sup> Digital imaging provided a more standardized, consistent approach to oral cavity assessment, and our pilot study suggests that using DI to calculate the ratio of the unoccupied area of the oral cavity may allow the patient to be scored 1-3 based on the observed ratio.

Another potential advantage of DI is that it measured the size of the visible tongue. The tongue plays a vital role in laryngoscopy; if the tongue is not properly displaced the view of the glottic opening is obstructed and the tube cannot be placed into the trachea (8). There has been little work to categorize tongue shape, size, and fat variation and distribution. This may be partially explained by the tongue's complex anatomy and development; the tongue is derived from contributions from all four pharyngeal arches and thus has complex innervation.<sup>9</sup> In addition, the fully developed tongue is a muscular organ with a complex shape capable of over twelve different movements playing vital roles in mastication and vocalization.<sup>9</sup> The tongue's size is difficult to approximate and calculate without the use of expensive imaging, as its base rests deep in the oropharynx, and only its distal third is visible when extended from the oral aperture.

Mallampati classification was based on the

## digital Imaging in Thyroid

hypothesis that the base of the tongue played one of the most important roles in vocal cord visualization, and uses the visibility of the faucial pillars as a proxy measurement to estimate the size of the base of the tongue.<sup>1</sup> Thirty years later, Mallampati is still the standard airway test and little work has been done to elucidate any further the specific role of the tongue. We developed an alternative objective airway assessment of the visible tongue and suggested that the size of the visible tongue may offer a better approximation of the visually obstructed base of the tongue. In other words, if the blade of the tongue is large then, it likely follows that the base of the tongue may also be large.

The correlation between ratio of unoccupied area of the oral cavity and the Mallampati classification indicated that using DI may precisely, quantitatively assess the oral cavity dimensions in a manner with predictive power for difficult airway likelihood preoperatively. This ratio may also be categorized in a manner similar to Mallampati with a score between 1 and 3, and still have a strong Pearson correlation. In our sample population, the first quartile for the ratio of unoccupied area was 18, which may be considered the cutoff mark for a Mallampati class III/IV airway. This ratio was not dependent on any one calculated variable. Rather, it depended on the relative contributions of the teeth, tongue, unoccupied area, and the entire oral cavity size. A large ratio of unoccupied space of the oral cavity may be a result of a large mouth, a small tongue, or a combination of the two, and vice versa. The percentage of unoccupied space is a single, quantitative calculation that incorporates the variation seen in the relative contributions of the anatomical features of the oral cavity.

### LIMITATIONS

There were several limitations to our pilot study. Our sample size was low and although we found a significant correlation between Mallampati classification and the

UO ratio, a larger sample size would have been more meaningful statistically. Our study was performed at a single tertiary academic center. We only examined the correlation between our exam and one component of the current airway exam (Mallampati classification), and did not examine thyromental distance or neck range of motion. Additionally, DI is still evolving and the program used in this study is only available on laptops or desktop computers, and is not available on mobile devices.

### CONCLUSION

In summary, we provide an objective comparison (UO ratio) to a current subjective airway assessment (Mallampati classification). The UO ratio may be able to better quantify the distinction between a Mallampati I and a Mallampati III, reducing the interobserver variability seen with the classification currently. Our objective airway assessment tool is quick and reliable and may be used to evaluate the structures in the oral cavity preoperatively in order to predict difficult intubation.

**Acknowledgments:** We are thankful to Department of Anesthesiology, Wake Forest School of Medicine for funding and facilitating the conduct of this study..

**Conflict of Interest/Disclosure:** None of the authors has anything to disclose financial or otherwise.

No external sources of funding. Funded solely by the Department of Anesthesiology, Wake Forest School of Medicine.

**Authors' contributions:**

YB: Design of study, Data analysis, Manuscript preparation

KJ: Data Analysis, Manuscript preparation

JK: Manuscript preparation

PL: Data collection

SR: Statistics and data analysis

HH: Manuscript editing

JC: Design of Study

### Appendix 1: ImageJ Methodology

ImageJ was calibrated so that 1 cm distance was equal to a set number of pixels using the ruler in the image and the scale function in ImageJ. Using ImageJ's measurement functions, the size (area occupied) of the tongue, the unoccupied area (space available) of the oral cavity, and the area of the entire oral cavity minus the lips were measured by dragging the mouse pointer along the outline of the specified space. Each of these measurements was entered into a premade Excel datasheet that calculated the ratio of unoccupied area to the entire oral cavity by dividing the unoccupied area by the area of the entire oral cavity and multiplying by 100.

## REFERENCES

1. Mallampati SR. Clinical sign to predict difficult tracheal intubation (hypothesis). *Can Anaesth Soc J.* 1983;30(3):316-7. [PubMed]
2. Adamus M, Fritscherova S, Hrabalek L, Gabrhelik T, Zapletalova J, Janout V. Mallampati test as a predictor of laryngoscopic view. *Biomed Pap Med Fac Univ Palacky Olomouc Czech Repub.* 2010;154(4):339-43. [PubMed]
3. Riley Z, Santago P, Bryan Y. Digital imaging for objective airway assessments shows high inter-rater reliability amongst anesthesiology researchers. Poster #53 [Online]. [cited 2015 Nov 14]. Presented at the 2015 State of North Carolina Undergraduate Research and Creativity Symposium. Available at: URL: <http://sncurcs.org/2015-sncurcs-digital-program/>
4. Amathieu R, Smail N, Catineau J, Poloujadoff MP, Samii K, Adnet F. Difficult intubation in thyroid surgery: myth or reality? *Anesth Analg.* 2006;103(4):965-8. [PubMed] DOI: [10.1213/01.ane.0000237305.02465.ee](https://doi.org/10.1213/01.ane.0000237305.02465.ee)
5. Bouaggad A, Nejmi SE, Bouderkka MA, Abbassi O. Prediction of difficult tracheal intubation in thyroid surgery. *Anesth Analg.* 2004;99(2):603-6. [PubMed] DOI: [10.1213/01.ANE.0000122634.69923.67](https://doi.org/10.1213/01.ANE.0000122634.69923.67)
6. Mallat J, Robin E, Pironkov A, Lebuffe G, Tavernier B. Goitre and difficulty of tracheal intubation. *Ann Fr Anesth Reanim.* 2010;29(6):436-9. [PubMed] DOI: [10.1016/j.annfar.2010.03.023](https://doi.org/10.1016/j.annfar.2010.03.023)
7. White ML, Doherty GM, Gauger PG. Evidence-based surgical management of substernal goiter. *World J Surg.* 2008;32(7):1285-300. [PubMed] DOI: [10.1007/s00268-008-9466-3](https://doi.org/10.1007/s00268-008-9466-3)
8. Janssens M, Hartstein G. Management of difficult intubation. *Eur J Anaesthesiol.* 2001;18(1):3-12. [PubMed]
9. Mu L, Sanders I. Human tongue neuroanatomy: nerve supply and motor endplates. *Clin Anat.* 2010;23(7):777-91. [PubMed] DOI: [10.1002/ca.21011](https://doi.org/10.1002/ca.21011)

